

How to Do It: Importance of Left Atrial Side Retraction in Robotic and Minimally Invasive Mitral Valve Surgery

Norihiko Ishikawa, MD, PhD,^{1,2} You Su Sun, MD,¹ L. Wiley Nifong, MD,¹
Go Watanabe, MD, PhD,² W. Randolph Chitwood, Jr., MD¹

¹Center for Robotics and Minimally Invasive Surgery, The Brody School of Medicine at East Carolina University, Greenville, North Carolina, USA; ²Department of General and Cardiothoracic Surgery, Kanazawa University School of Medicine, Kanazawa, Japan

ABSTRACT

A customized transthoracic atrial retractor was previously developed for robotic and minimally invasive mitral valve surgery, but it has sometimes failed to provide sufficient exposure of the mitral valve because some atrial tissues push away the operative field from the right side. This report describes 3 new atrial side retractors (the foldaway retractor, the spoon retractor, and the wired retractor) and their use in performing robotic mitral valve repair in fresh frozen human cadavers. These retractors provided exceptional and consistent exposure of the left atrium in robotic and minimally invasive mitral valve surgery in human cadavers without causing traumatic injury, and these retractors should be useful in live patients because they will be used in arrested hearts.

INTRODUCTION

Several recent advances, such as closed-chest cardiopulmonary bypass [Pompili 1996], endoscopic surgery, and robotic telemanipulation systems, have spurred the development of minimally invasive cardiac surgery. As a result, minimally invasive (including robotic) mitral valve surgery using a small thoracotomy incision and several thoracoports has become a standard procedure [Chitwood 2005; Nifong 2005]. A customized transthoracic atrial retractor was previously developed for robotic and minimally invasive mitral valve surgery [Kypson 2003], but it sometimes failed to provide sufficient exposure of the mitral valve because some atrial tissues pushed away the operative field from the right side. We therefore designed 3 new atrial side retractors: the foldaway retractor, the spoon retractor, and the wired retractor. In this report, we describe these new instruments and their efficacy, which was tested by performing robotic mitral valve repair in fresh frozen human cadavers.

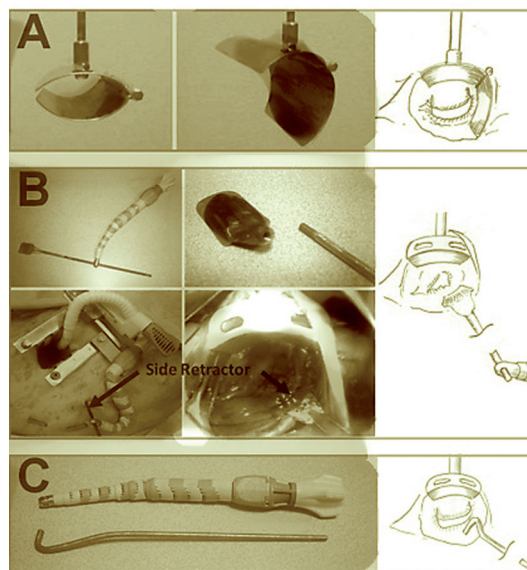
Received July 24, 2007; received in revised form August 7, 2008; accepted August 8, 2008.

Correspondence: Norihiko Ishikawa, MD, PhD, Center for Robotics and Minimally Invasive Surgery, Brody School of Medicine at East Carolina University, 600 Moye Blvd – LSB 248, Greenville, NC 27858, USA; 1-252-744-2187; fax: 1-252-744-3542 (e-mail: nori-i@mnx.jp).

TECHNIQUE

Foldaway Retractor

This retractor consists of 2 blades and a rod (Figure 1A). An upward blade and a side retraction blade are linked with a hinge joint, and both blades have a trapezoid shape. After the blades are inserted into the left atrium, they are attached to a rod inserted through the anterior chest wall, and they lift the roof of the left atrium. Then, the side retraction blade is opened and fixed by means of a screw of the hinge joint. This unique retractor consistently enhances visualization of the left atrium and the mitral valve.



Foldaway, spoon, and wired retractors. A, The foldaway retractor consists of 2 blades and a rod. The upward blade and the side retraction blade are linked, and the side retraction blade is opened and fixed. The blades are attached to the rod inserted through the anterior chest wall, and the rod is fixed by a table-mounted arm. B, The spoon retractor consists of 3 parts: a flexible arm, a rod, and an attachable blade. The rod is inserted into the thoracic cavity in the right side of the service port, attached to the blade, and then fixed by a flexible arm mounted on the rib opener. C, The wired retractor consists of a flexible arm, a rod, and an L-shaped rigid, thick wire. The L-shaped wire is inserted and fixed by the flexible arm like the spoon retractor.

Spoon Retractor

This retractor consists of 3 parts (Figure 1B): a flexible arm, a rod, and an attachable blade. We improved an existing heart stabilizer arm (Xpose™; Guidant Corporation, Santa Clara, CA, USA) so that it could be attached to the rod and fixed as desired. For the pair of the blade and the rod, we prepared 2 types of attachable mechanisms: One type has a blade with a small square hole and a square-shaped rod; the other type has a blade with a screw cup and a screw rod. When the spoon retractor is used, the rod is inserted into the thoracic cavity through a 3-mm skin incision and then attached to the blade. Once the flexible arm mounted on the rib opener is fixed with the rod, the retractor is firmly immobilized to provide excellent exposure of the operative field.

Wired Retractor

This retractor consists of a flexible arm, a rod, and an L-shaped rigid, thick wire (2 mm thick; Figure 1C). The L-shaped wire can be atraumatically inserted through a 2-mm skin incision and immobilized by means of the flexible arm, as with the spoon retractor.

We evaluated the usefulness of these retractors in robotic mitral valve repair in human cadavers with the da Vinci™ Surgical System (Intuitive Surgical, Sunnyvale, CA, USA). The retractor was inserted from the port farther from the service port and the right robotic-arm port. This approach is taken so the retractors (including the rod) do not collide with the right robotic arm. It also allows easier access to the heart and provides optimal atrial side retraction and superior presentation of the mitral valve without impinging on the robotic arms.

DISCUSSION

Successful mitral valve operation depends on excellent and consistent exposure of the left atrium as well as the mitral valve. Robotic and minimally invasive mitral valve surgery in particular requires greater visualization of the operative field. In conventional robotic and minimally invasive mitral valve surgery, the mitral valve is exposed by opening the left atrium just posterior to the intra-atrial groove and anterior to the right pulmonary veins. The transthoracic atrial retractor has been developed for these procedures, and the blade attached to the rod lifts the roof of the left atrium. Nevertheless, there are still problems with this transthoracic atrial retractor. Because this instrument was designed specifically for upward retraction of the left atrium, retraction in the horizontal direction is insufficient, so that the right side soft tissues, such as the atrial wall and the inferior vena cava, intrude into

the surgical field. Consequently, the anatomy cannot be identified well, and surgical manipulation becomes difficult. Furthermore, the right robotic instrument always touches the right oppressive tissues during robotic mitral valve surgery, and the tissues sometimes obstruct the path when the right robotic instrument is being changed. Because such obstruction would induce traumatic injury of the soft tissue, we always make an additional suture, called a “4-o’clock suture,” on the mitral annulus at 4 o’clock and pull the suture toward the outside. The 4-o’clock suture can enhance the visualization of the mitral valve, but a risk of tissue injury by the right robotic instrument still exists.

Three prototypes have therefore been designed to overcome the lack of visualization and the potential for tissue injury by the robotic instrument. In robotic mitral valve surgery, 3 large robotic arms are placed on the right chest and can be moved freely. Avoidance of conflict with the retractors and the robotic arms is exceedingly important for safety. The compact profiles of these retractors permit the procedures to be successfully performed without their impinging on the robotic arms. These retractors can be removed when not required for the intracardiac portion of the procedure, and their use prevents tissue damage. These retractors provided exceptional and consistent exposure of the left atrium in robotic and minimally invasive mitral valve surgery in human cadavers without causing traumatic injury, and they should be useful in live patients because they are intended for use in arrested hearts.

Mitral valve surgery is sometimes combined with the Maze procedure for atrial fibrillation [Reade 2005]. Because these retractors do not obstruct the side of the left atrial appendage or the pulmonary veins, these retractors should be useful for this combined procedure. They are patent-pending products in the United States.

REFERENCES

- Chitwood WR Jr. 2005. Current status of endoscopic and robotic mitral valve surgery. *Ann Thorac Surg* 79:S2248-53.
- Kypson AP, Nifong LW, Chitwood WR Jr. 2003. Robotic mitral valve surgery. *Semin Thorac Cardiovasc Surg* 15:121-9.
- Nifong LW, Chitwood WR, Pappas PS, et al. 2005. Robotic mitral valve surgery: a United States multicenter trial. *J Thorac Cardiovasc Surg* 129:1395-1404.
- Pompili MF, Stevens JH, Burdon TA, et al. 1996. Port-access mitral valve replacement in dogs. *J Thorac Cardiovasc Surg* 112:1268-74.
- Reade CC, Johnson JO, Bolotin G, et al. 2005. Combining robotic mitral valve repair and microwave atrial fibrillation ablation: techniques and initial results. *Ann Thorac Surg* 79:480-4.