

Reexamining Contraindications for Minimally Invasive Mitral Valve Surgery

Clifton C. Reade, MD,¹ Curtis E. Bower, MD,¹ Alan P. Kypson, MD,¹ L. Wiley Nifong, MD,¹ William A. Wooden, MD, FACS,² W. Randolph Chitwood Jr, MD, FACS, FRCS (Eng)¹

Divisions of ¹Cardiothoracic and Vascular Surgery, ²Plastic and Reconstructive Surgery, The Brody School of Medicine at East Carolina University, Greenville, North Carolina, USA



Dr. Reade



ABSTRACT

Historically, contraindications to minimally invasive or robotic mitral valve surgery have included prior mastectomy, thoracic reconstruction, or chest radiation. However, we believe that by granting flexibility in the choice of skin incision site while performing careful dissection, surgeons can provide these patients the outstanding results afforded by a minithoracotomy. We present a patient who had undergone a prior mastectomy and radiation treatment in whom we performed a minimally invasive mitral valve repair through a right-sided minithoracotomy using the previous mastectomy incision.

BACKGROUND

Minimally invasive mitral valve surgery (MIMVS) using AESOP (Computer Motion, Santa Barbara, CA, USA) guidance or the da Vinci Surgical System (Intuitive Surgical, Sunnyvale, CA, USA) has transformed the way patients and surgeons are viewing mitral valve surgery. Through a 4-cm minithoracotomy, MIMVS with videoscopic assistance has significantly reduced blood loss, ventilator time, and hospital length of stay [Felger 2001]. Initially, not all patients were deemed suitable for MIMVS, with contraindications including prior thoracotomy, pectus excavatum, morbid obesity, breast reconstruction, and chest radiation [Tribble 1987, Felger 2001, Casselman 2003]. However, as cardiac surgeons become more comfortable with the approach, prior contraindications should be reexamined.

Presented at the 7th Annual NewEra Cardiac Care: Innovation & Technology, Dana Point, California, January 9-11, 2004.

Received August 10, 2004; accepted August 30, 2004.

Address correspondence and reprint requests to: Clifton C. Reade, MD, Department of Surgery, The Brody School of Medicine at East Carolina University, 600 Moyer Blvd, Greenville, NC 27834, USA; 1-252-744-5069; fax: 1-252-744-3156 (e-mail: readec@mail.ecu.edu).

CASE REPORT

The patient was a 55-year-old white woman with a history of congestive heart failure but no coronary artery disease. Echocardiography revealed that she had severe bileaflet prolapse of her mitral valve. Sixteen years prior to this presentation she had a diagnosis of breast cancer and underwent a right modified radical mastectomy followed by postmastectomy radiation treatment. Subsequent to these treatments she underwent a reconstructive breast procedure with implant and nipple reconstruction.

Our normal approach to MIMVS is a 4-cm right-sided minithoracotomy through the fourth intercostal space. In order to afford this patient a pleasing cosmetic repair, we approached the skin incision via the previous mastectomy scar, residing lateral to the reconstructed nipple, instead of

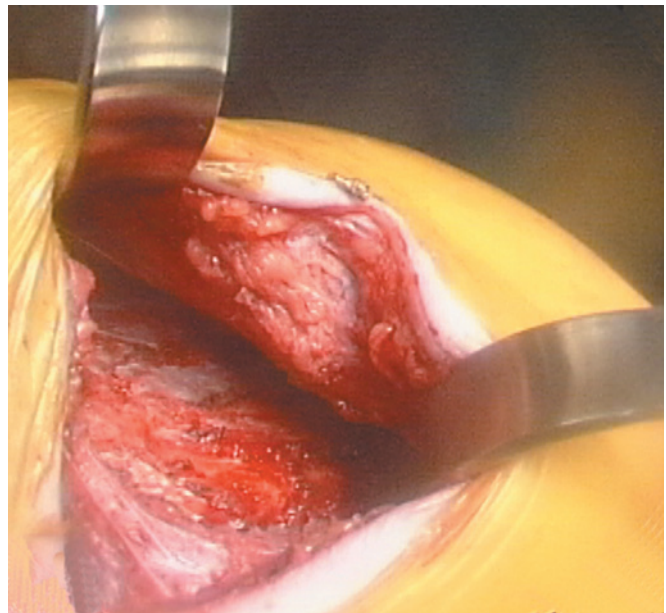


Figure 1. Exposure of the thoracic cage is performed by elevating the implant capsule/pectoralis major and medializing it from the more lateral latissimus dorsi muscle.




Figure 2. Intrathoracic access with atrial retractor inserted through minithoracotomy instead of via transthoracic separate incision.

the usual inframammary incision. The implant cavity/pectoralis muscle was raised superiorly as an en-bloc flap with dissection off of the deep thoracic cage and the lateral latissimus dorsi muscle (Figure 1). Once the thoracic cage was exposed, dissection through the fourth intercostal space could be performed as usual.

Videoscopic guidance was used to dissect intrathoracic adhesions caused by prior radiation. The pericardium was opened and the left atrium accessed in a typical manner. Because of the implant, the atrial retractor could not be placed in its typical position and had to be placed through the incision (Figure 2). A quadrangular resection of P2, sliding plasty of P1 on P3, transfer of P2 chords to A2, and insertion of a #36 Cosgrove-Edwards (Edwards Lifesciences, Irving, CA, USA) annuloplasty band was performed without difficulty, using AESOP guidance as described in previous litera-

ture [Felger 2001]. Transesophageal echocardiography showed no postrepair mitral regurgitation.

Closure of the thoracotomy was accomplished by approximating the ribs. A drain was placed below the implant capsule flap. This procedure was followed by closure of the implant capsule/pectoralis muscle flap to the lateral latissimus dorsi muscle with interrupted absorbable sutures. Skin edges were resected to obtain samples to send to pathology to rule out breast cancer recurrence. The skin was then approximated with a subcuticular suture. A cosmetic comparison between a conventional inframammary incision and our reported case is shown in Figure 3.

The patient did very well postoperatively. She was transferred from the intensive care unit on postoperative day 1, and the chest tubes and muscle flap drain were removed on postoperative day 2. She was discharged home on postoperative day 4.

CONCLUSIONS

As the benefits of MIMVS become more widely known, more and more patients will be presenting to cardiac surgeons requesting the minithoracotomy. In addition, as more patients present with mitral valve disease after prior sternotomy, more MIMVS via a minithoracotomy may be anticipated. Not only does the smaller incision provide a more pleasing cosmetic appearance, it also has been shown to speed recovery. Cardiac surgeons must become more adaptable to using existing scars for incisions and not be tethered to traditional teaching. In addition, possible contraindications for MIMVS must be reexamined as cardiac surgeons become more comfortable with the procedure. Furthermore, combined surgical disciplines can be used in the operating room to facilitate flexibility in surgical procedures. Previous incisional history should not limit our approach to MIMVS. In this case visualization of the thoracic cage after superiorly retracting the implant capsule was excellent and afforded easy access to the fourth intercostal

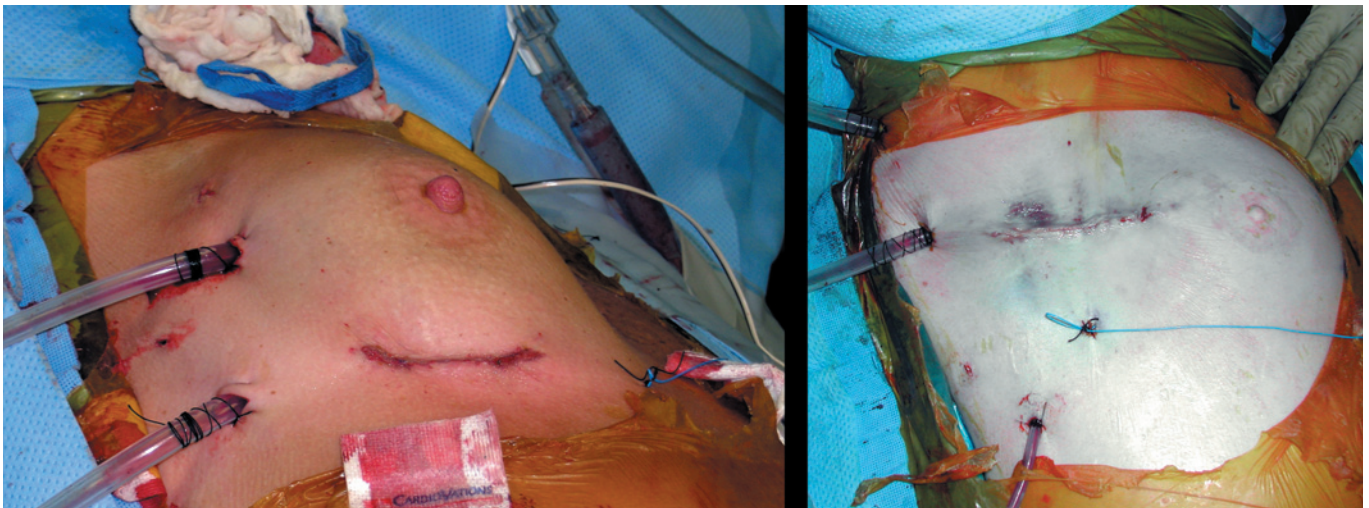


Figure 3. Comparison of conventional inframammary access (left) to access via prior mastectomy incision (right).

space. We must adapt to the patient in order to provide novel surgical care, especially as we progress toward totally endoscopic mitral valve surgery.

REFERENCES

- Casselmann FP, Slycke SV, Dom H, Lambrechts DL, Vermeulen Y, Vanerman H. 2003. Endoscopic mitral valve repair: feasible, reproducible, and durable. *J Thorac Cardiovasc Surg* 124:273-82.
- Felger JE, Chitwood Jr WR, Nifong LW, Holbert D. 2001. Evolution of mitral valve surgery: toward a totally endoscopic approach. *Ann Thorac Surg* 72:203-9.
- Tribble CG, Killinger WA, Harman PK, Crosby IK, Nolan SP, Kron IL. 1987. Anterolateral thoracotomy as an alternative to repeat median sternotomy for replacement of the mitral valve. *Ann Thorac Surg* 43:380-2.