

Hybrid Procedures for Complex Congenital Cardiac Lesions

Constantinos A. Contrafouris, Fotios A. Mitropoulos, Andrew C. Chatzis,
Nikolaos M. Giannopoulos, Michael Milonakis, Spyridon Rammos, Mike Azariades

Department of Paediatric and Congenital Cardiac Surgery, Onassis Cardiac Surgery Centre, Athens, Greece

ABSTRACT

Background: We present an alternative treatment employing a hybrid approach used in 3 patients with congenital heart disease. The goal was to provide optimal therapy by minimizing the potentially harmful effects of methods that accompany conventional surgical procedures.

Methods: Two patients aged 4 and 6 months underwent beating-heart closure of a muscular ventricular septal defect (VSD) with an occluding device. In addition, an 8-year-old patient with supraaortic, main, and branch pulmonary artery (PA) stenosis underwent conventional surgical patch augmentation of the ascending aorta and the main PA and intraoperative stenting of the branch PA stenoses.

Results: No patient deaths occurred. One patient developed a postoperative pneumothorax. Median intensive care unit and hospital stays for the VSD patients were 1 and 5 days and for the other patients 2 and 20 days, respectively. At median follow-up of 25 months, all patients were well and had required no further interventions.

Conclusions: Patients with muscular VSD can currently be treated with the hybrid approach. Intraoperative PA stenting in addition to conventional surgical repair can be performed safely and may be complementary in patients with complex lesions.

INTRODUCTION

Hybrid pediatric cardiac surgery is an emerging concept that combines skills and techniques used by pediatric cardiac surgeons and interventional cardiologists. Many efforts have been made the last decade to combine catheterization and surgical techniques. Overall results were not satisfactory initially, with high mortality and failure rates [Fishherger 1993]. For ventricular septal defect (VSD) closure the original approach in all cases was that the devices were placed under direct vision while the patient was under cardioplegic

arrest. We have employed a simplified technique of off-pump intraoperative device closure of muscular VSD via a periventricular approach, as reported in the literature [Bacha 2003]. The technique's safety has been validated in experiments and in fact the use of this method has markedly reduced the complication rate [Amin 1999]. The 1-stage approach is simple, and advantages over open repair include avoidance of ventricular incisions and other intracardiac transections. Patients with pulmonary artery (PA) stenoses can also benefit from a hybrid approach. Introduction of a stent under direct vision via the opened right PA is simple and can be done on the beating heart or even off-pump [Bacha 2004; Mitropoulos 2007].

MATERIAL AND METHODS

From June 2006 to February 2008, 3 patients, 1 male and 2 female, underwent hybrid pediatric cardiac surgery. The age range was 4 months to 8 years.

VSD Closure

Two patients aged 4 and 6 months underwent beating-heart off-pump intraoperative device closure of a muscular VSD. This surgical intervention was achieved via a right

Presented at the 4th Integrated Coronary Revascularization (ICR) Workshop for Interventional Cardiologists and Cardiac Surgeons, Innsbruck, Austria, December 4-6, 2008.

Correspondence: Constantinos A. Contrafouris, MD, Department of Paediatric and Congenital Cardiac Surgery, Onassis Cardiac Surgery Centre, 356 Sygrou Ave, 17674 Kallithea, Athens, Greece; +30210-9493861; fax: +30210-9493887 (e-mail: contraf@vodafone.net.gr).

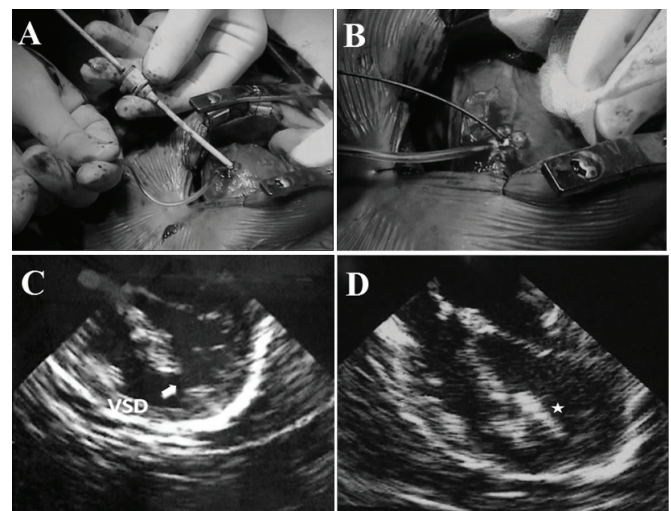


Figure 1. Intraoperative ventricular septal defect device closure (A, B) and echocardiography prior to (C) and following implantation (D).

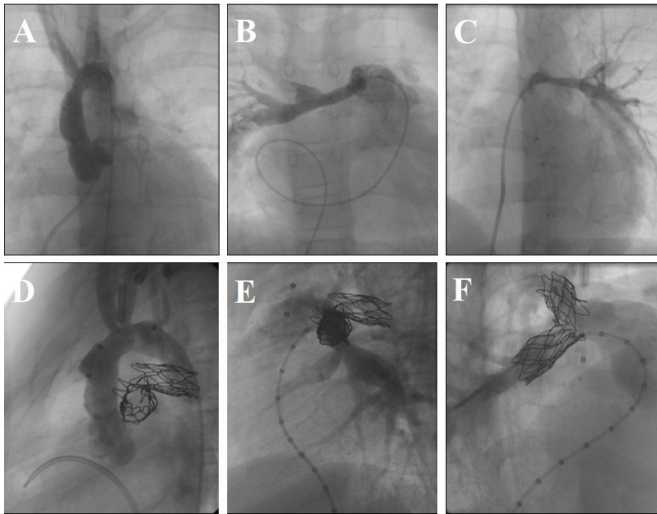


Figure 2. Supraaortic (A) and right and left pulmonary artery stenoses (B, C) and the result of the combined hybrid approach (D-F).

periventricular approach, using an Amplatzer occluding device (Amplatzer Medical, Golden Valley, MN, USA) (Figure 1).

PA Stenting

An 8-year-old patient with supraaortic, main, and branch PA stenosis underwent conventional surgical patch augmentation of the ascending aorta and the main PA. The branch PA stenoses were dilated intraoperatively, followed by direct placement of CP stents (NuMed, Hopkinton, NY, USA) into both PA branches with the heart beating. Diameter increased from 8 to 14 mm for the right and 6 to 12 mm for the left PA, respectively (Figure 2).

RESULTS

No patient deaths occurred. The patient with aortic and PA stenosis developed a postoperative pneumothorax. Median intensive care unit and hospital stays for the VSD patients were 1 and 5 days and for the other patients were 2 and 20 days, respectively. Postoperative echocardiogram study of the VSD patients showed successful closure of the defect with no residual leak. At 6 months, the right ventricular pressure of the patient with the PA stenoses had decreased by half. At median follow-up of 25 months, all patients remain well and free from further interventions.

DISCUSSION

Attempts to combine catheterization and surgical techniques have been made and were successful in various settings. Intraoperative balloon occlusion of Blalock-Taussig shunts and patent ductus arteriosus and balloon dilatation of critical aortic stenosis in neonates and infants have been reported [Hjortdal 2002]. Intraoperative PA stenting has also been described [Ungerleider 2001].

Several series of intraoperative device closure of muscular VSD by use of double-umbrella devices have also been reported. Overall, results were not satisfactory initially, with high mortality and failure rates [Fishherger 1993]. The common approach in all cases was that the devices were placed under direct vision while the patient was under cardioplegic arrest. Poor outcomes have been attributable to difficulties in delivering the device or having to suture the device in position. Currently interventional techniques are the preferred therapeutic approach for most muscular VSD, but are limited by several factors, such as patient weight, vascular access, and the need for surgical repair of concomitant lesions. In addition, the use of catheters across valves introduces risks of chordal rupture or impingement. Later, this approach was abandoned, and a 1-stage procedure was adopted. Instead a simplified technique of off-pump intraoperative device closure of muscular VSD via a periventricular approach was employed, with encouraging initial results [Amin 1999; Bacha 2004]. The 1-stage approach is simple and requires less time to accomplish.

Patients with muscular VSD and ventricular dysfunction do better without prolonged catheterization and operative times. Advantages over open repair include avoidance of transection of the moderator band or other right-ventricle muscle bundles, immediate confirmation of adequate closure, and avoidance of any ventricular incisions. In the absence of associated defects, minimally invasive approach such as a subxyphoid incision (1-2 cm) can easily be attempted. Compared to percutaneous approaches, small patient size and limited vascular access do not pose contraindications to the combined surgical/interventional technique. Because catheters are inserted via a ventricular puncture, the intervention area stays below the subvalvar apparatus of the tricuspid valve, and the risk of chordal damage is markedly reduced. In addition, most patients require additional surgical procedures, such as PA debanding or right-ventricular outflow tract reconstruction, which can be easily performed during the combined surgical/interventional technique. Patients with PA stenoses can also benefit from a hybrid approach. These stenoses often occur as the result of previous resections and adhesion formation in the area and make surgical repairs difficult and time-consuming. Delivery of a stent under direct vision via the opened right PA is simple and can be done on the beating heart or even off pump. Nevertheless, compression of the left main coronary artery by a retroaortic PA stent has also been described, and overdilation of the stent should be avoided [Mitropoulos 2007]. Fluoroscopy may be a useful tool to ensure correct positioning of the stent prior to dilatation [Bacha 2004].

Patients with muscular VSD who are eligible for device closure yet cannot undergo percutaneous closure owing to lack of small-size catheters can currently be treated in one setting with the hybrid approach. Intraoperative PA stenting in addition to conventional surgical repair can be performed safely and may be complementary in patients with complex lesions.

REFERENCES

- Amin Z, Gu X, Berry JM, Gidding T, Rocchini AL. 1999. Periventricular closure of ventricular septal defects without cardiopulmonary bypass. *Ann Thorac Surg* 68:149-54.
- Bacha EA, Cao QI, Starr JP, et al. 2003. Periventricular device closure of muscular ventricular septal defects on the beating heart: technique and results. *J Thorac Cardiovasc Surg* 126:1718-23.
- Bacha EA, Hijazi ZM, Cao QI, Starr JP, Waight D, Koenig P, Agarwala B. 2004. New therapeutic avenues with hybrid pediatric cardiac surgery. *Heart Surg Forum* 7:33-40.
- Fishherger SB, Bridges ND, Keane JF, et al. 1993. Congenital heart disease: intraoperative device closure of ventricular septal defects. *Circulation* 88:205-9.
- Hjortdal VE, Redington AN, de Leval MR, Tsang VT. 2002. Hybrid approaches to complex cardiac surgery. *Eur J Cardiothorac Surg* 22:885-90.
- Mitropoulos FA, Laks H, Kapadia N, et al. 2007. Intraoperative pulmonary artery stenting: an alternative technique for the management of pulmonary artery stenosis. *Ann Thorac Surg* 84:1338-41.
- Ungerleider RM, Johnston TA, O Laughlin MP, Jagers JJ, Gaskin PR. 2001. Intraoperative stents to rehabilitate severely stenotic pulmonary vessels. *Ann Thorac Surg* 71:476-81.