

## How I Do It

# A Novel Method That Provides Simultaneous Coronary Artery Occlusion and Retraction for Beating Heart Bypass Surgery

(#2003-89037 . . . May 5, 2003)

Osman Tansel Darcin, Mehmet Halit Andac

Harran University, Faculty of Medicine, Department of Cardiovascular Surgery, Sanliurfa, Turkey



Dr. Darcin

### ABSTRACT

**Background:** Coronary artery stabilization and retraction have been a crucial problem in beating heart bypass surgery. Conventional methods such as looping and suspension of the target artery carry risk of coronary artery damage. Above all, these methods do not aid in retraction in coronary arteriotomy.

**Methods:** Five mongrel dogs were used in this study. After intratracheal general anesthesia, median sternotomy was performed, and the left anterior descending coronary artery (LAD) and right coronary artery (RCA) were chosen as target vessels. To stabilize epicardium we passed the proximal portion of each coronary artery with a pledgeted suture parallel to the orientation of the coronary artery through the arteriotomy. After a similar suture was passed on the distal side, pledgets were placed on both sides of the incised coronary artery, and tourniquets were applied and snared just after opening of the target coronary artery for occlusion of proximal and distal flow. The tourniquets also were pulled up at an angle of 45 degrees on both sides for stabilization of the epicardium and retraction of the arteriotomy edges.

**Results:** All instances of snare-induced coronary occlusion and retraction were analyzed (10 coronary snares in 5 dogs, the RCA and the LAD of each dog being used). Flow in the coronary artery was stopped, and visualization of the arteriotomy was successful.

**Conclusions:** We described a novel technique of temporary coronary artery stabilization and occlusion that provided simultaneous retraction in coronary arteriotomy. This procedure resulted in a clean and retracted operative field for suitable anastomosis even in the arteriotomy edges.

### INTRODUCTION

Successful coronary artery bypass grafting (CABG) performed on a beating heart is required for optimal visualiza-

tion of the operative field during coronary anastomoses and for stabilization during surgical procedures [Bordst 1996, Hart 1999, Chen 2001]. To date various stabilization techniques have been used, such as suspension with epicardial sutures placed around the coronary artery and pressure or vacuum control with different instruments. Although those techniques provide some satisfactory stabilization, the former carries risk of endothelial damage to the target coronary arteries, and the latter gives a limited field for anastomosis [Bordst 1996, Gerola 1999, Hart 1999, Perrault 2000]. We describe another epicardial stabilization method for both occlusion and retraction of the coronary artery that allows suitable anastomosis.

### MATERIALS AND METHODS

Five mongrel dogs weighing  $28 \pm 5$  kg were used in the present study. All animals received humane care in compliance with the *Guide for Care and Use of Laboratory Animals* prepared by the National Institutes of Health (NIH publication No. 86-23, revised 1985). The dogs were anesthetized with intramuscular ketamine (25 mg/kg) and xylazine (3 mg/kg), and intratracheal intubation was conducted thereafter. Under sterile conditions, median sternotomy was performed, and the heart was reached with pericardiotomy. After the ventricular rate was slowed with intravenous injection of metoprolol, the heart was prepared in its native position. For the purposes of the present study, the left anterior descending coronary artery (LAD) and right coronary artery (RCA) were chosen as target vessels. Suturing was performed in the middle third of the LAD and in the atrioventricular groove portion of the RCA, which is the most common site of graft anastomosis in CABG. The proximal portion of the each coronary artery was sutured parallel to the orientation of the coronary artery with 4-0 polypropylene suture material with pledget through the arteriotomy portion. After a suture with pledget was passed on the distal side in a similar fashion, pledgets were placed on both sides of the incised coronary artery, and tourniquets were applied for temporary snaring later (Figure 1). For occlusion of proximal and distal flow, these tourniquets were snared just after the target coronary artery was opened. The tourniquets also were pulled up at an angle of 45 degrees on both sides for stabilization of epicardium and retraction of arteriotomy edges in the operative field (Figure 2).

Received April 25, 2003; accepted May 5, 2003.

Address correspondence and reprint requests to: Dr. Osman Tansel Darcin, Harran Universitesi, Arastirma Hastanesi, Kalp ve Damar Cerrahisi Anabilim Dalı, 63100-Sanlıurfa, Turkey; 90-414-314-1170/2022; fax: 90-414-315-1181 (e-mail: [otdarcin@hotmail.com](mailto:otdarcin@hotmail.com)).

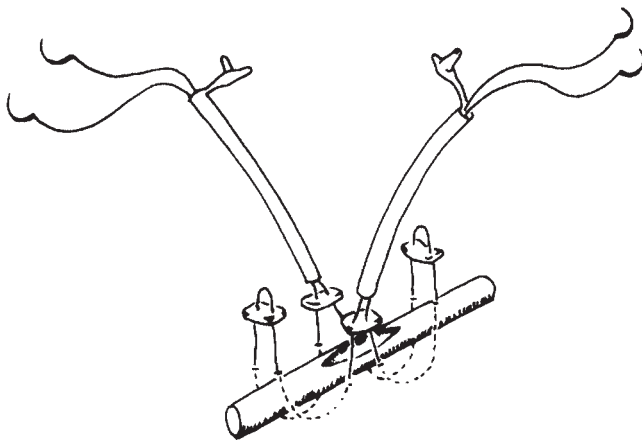


Figure 1. Stitches with pledget are placed parallel along the target coronary artery from periphery to central, and the tourniquets are placed on each side of the arteriotomy incision.

## RESULTS

A total of 10 instances of snare-induced coronary occlusion and retraction were evaluated in the beating heart model in 5 dogs. All of the arteriotomy regions were clear and retracted, except RCA snaring in 1 animal allowed proximal oozing. Epicardium was stabilized sufficiently in all of the animals.

## DISCUSSION

Although beating heart bypass surgery is a common procedure in the treatment of coronary artery disease, debate continues about epicardial stabilization [Bordst 1996, Gerola 1999, Hart 1999, Chen 2001]. A circumflex double loop of the target vessel is commonly used for this purpose. But endothelial cell damage with this technique is a substantial drawback [Gerola 1999, Perrault 2000]. Although commercial stabilizers have been used for this purpose, the limited space between the limbs of the stabilizer has made suturing difficult. Above all, neither of the previous techniques aids in arteriotomy retraction.

In the present study, we developed a novel stabilization technique in a canine model. In the technique, the stitch with a pledget compresses the target coronary artery more evenly than a double loop with a single stitch, and tourniquets placed bilaterally on the epicardium retract the arteriotomy incision. Additional coronary arteriotomy retraction gives better exposure during anastomosis than the technique of Chen [2001], even on the coronary edges. With this maneuver, coronary anastomosis was easily placed with minimal blood loss in a clear, retracted operative field in either of the coronary arteries. This exposure feasibility would also be a

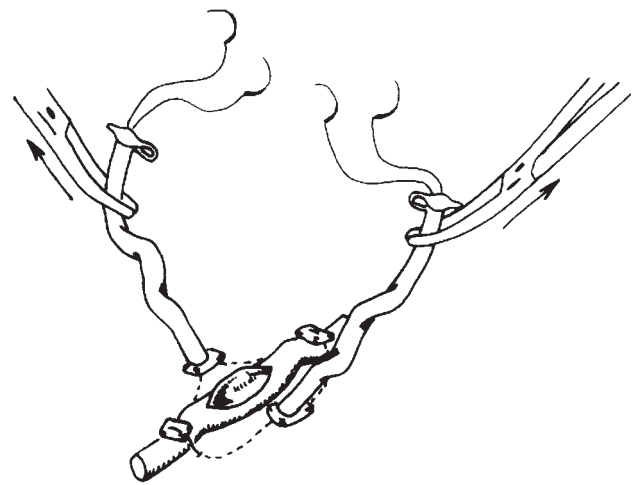


Figure 2. Target coronary artery is temporarily occluded and retracted by means of snaring and pulling up the tourniquets at an angle of 45 degrees.

time-sparing procedure during coronary anastomosis. The limitation of use of this method would be the need for posterior distal coronary anastomosis, such as of the posterior descending artery or obtuse marginal arteries. Economic comparison showed our method was less expensive than the instrumental tissue stabilization in common use [Bordst 1996, Hart 1999, Perrault 2000].

In conclusion, we designed a novel epicardial stabilization and coronary occlusion model that includes arteriotomy retraction. It is a simple and safe procedure that can enhance the surgeon's skill in beating heart bypass surgery.

## REFERENCES

- Bordst C, Jansen EW, Tulleken CA, et al. 1996. Coronary artery bypass grafting without cardiopulmonary bypass and without interruption of native coronary flow using a novel anastomosis site restraining device ("Octopus"). *J Am Coll Cardiol* 27:1356-64.
- Chen Y-S, Chou T-F, Lee J-Y, Lin F-Y, Wang S-S. 2001. New method of coronary artery occlusion for beating-heart coronary artery bypass surgery. *Ann Thorac Surg* 71:1712-3.
- Gerola LR, Moura LA, Leao LE, Soares HC, Branco JN, Buffolo E. 1999. Arterial wall damage caused by snaring of the coronary arteries during off-pump revascularization. *Heart Surg Forum* 3:103-7.
- Hart JC, Spooner T, Edgerton J, Milsteen SA. 1999. Off-pump multivessel coronary artery bypass utilizing the Octopus tissue stabilization system: initial experience in 374 patients from three separate centres. *Heart Surg Forum* 2:15-28.
- Perrault LP, Nicker C, Desjardins N, Carrier M. 2000. Effects on coronary endothelial function of the Cohn stabilizer for beating heart bypass. *Ann Thorac Surg* 70:1111-4.