

Article

A Clinical Study on the Treatment of Adult Atrial Septal Defect Using Thoracoscopic-Assisted Right Vertical Infra-Axillary Thoracotomy, Total Thoracoscopic, and Median Sternotomy Approaches

Heqi Zhang¹, Haoju Dong², Shubo Song², Hua Cao¹, Chongyang Yan¹, Maozheng Xuan², Taibing Fan², Weijie Liang^{2,*}

¹Department of Cardiac Surgery, Central China Fuwai Hospital of Zhengzhou University, 451464 Zhengzhou, Henan, China

²Henan Provincial People's Hospital Fuwai Central Cardiovascular Hospital Children's Heart Center, 451464 Zhengzhou, Henan, China

*Correspondence: lwj3781@126.com (Weijie Liang)

Submitted: 24 June 2024 Revised: 15 July 2024 Accepted: 2 August 2024 Published: 8 August 2024

Abstract

Background: To compare the clinical outcomes of three surgical approaches for treating adult atrial septal defects (ASD): Thoracoscopic-assisted right vertical infra-axillary thoracotomy (TARVIAT) under central cardiopulmonary bypass (CPB), totally thoracoscopic (TT), and median sternotomy (MS) approaches, and to assess the feasibility and safety of the TARIAT approach. **Methods:** This study reviewed 62 cases patients of repairing atrial septal defects via a TARVIAT and central extracorporeal circulation from 2019 to 2023. The patients included 22 males, aged between 18 and 59 years, with a mean age of 33.35 ± 10.97 years. The surgical indications were adult patients with moderate to severe tricuspid regurgitation and who were unsuitable for interventional closure of atrial septal defects. Exclusion criteria included patients diagnosed with severe pulmonary hypertension or Eisenmenger syndrome. Additionally, 67 patients who underwent TT approach repair of ASD and 72 patients who underwent MS approach repair of ASD were selected as the control groups. Operative time, CPB time, aortic clamping time, postoperative Intensive care unit (ICU) stay, postoperative mechanical ventilation time, 24-hour postoperative chest drainage, incision length, postoperative hospital stay, hospital costs, and postoperative complications were compared to assess statistical differences. **Results:** There were no deaths or major complications observed in any of the three groups. Statistically significant differences were found among the three groups in terms of extracorporeal circulation time, aortic clamping time, surgical time, 24-hour postoperative chest drainage, postoperative mechanical ventilation time, postoperative ICU stay, incision length, and postoperative hospital stay ($p < 0.05$). The TT group exhibited longer CPB and aortic clamping times compared to the TARVIAT and MS groups, while demonstrating lower 24-hour postoperative chest drainage volumes compared to the TARIAT and MS groups. Both the TARVIAT and TT groups showed shorter surgical times, postoperative mechanical ventilation times, postoperative ICU stay, incision lengths, and postop-

erative hospital. However, there were no statistically significant differences among the three groups regarding hospital costs, postoperative left ventricular ejection fraction (LVEF) values, and the incidence of postoperative complications ($p > 0.05$). **Conclusions:** TARVIAT under central CPB is feasible and safe for adult patients. This approach presents lower invasiveness, shorter operative duration, and faster recovery compared to other methods. In conclusion, the TARVIAT approach for repairing adult ASD is both safe and effective, offering a viable surgical option for this condition.

Keywords

atrial septal defect; thoracoscopy; right axillary vertical small incision; midline sternotomy; adult congenital heart disease

Introduction

Atrial septal defects (ASD) are considered one of the most common congenital heart defects (CHD) found in the adult. The estimated prevalence of ASD in adults is 0.88 per 1000 patients [1]. A fenestrated device is often considered in these cases to ensure that an adequate “pop-off” is present so that if right Atrial pressure rises above the light Atrial pressure, cardiac output is conserved. Relative contraindications to closure typically are regarded for percutaneous cases and include: defects larger than 36 mm, inadequate margins and rims to safely anchor the device, and/or interference of the device with the atrio-ventricular valves or venous drainage. Median sternotomy (MS) remains the gold standard for treating ASD and ventricular septal defects (VSD) due to its high success rate. Despite excellent surgical outcomes, patients often hesitate to undergo the procedure because it inevitably leads to a long midline chest scar, extended postoperative hospital stays, and potential chest deformities [2,3]. With the development of thoracoscopic-assisted surgery, robot-assisted surgery, and

various surgical approaches such as lower sternotomy, right submammary incision, right axillary incision, and right posterolateral incision, better cosmetic outcomes have been achieved [4]. Due to its concealed nature and quick postoperative recovery, the right vertical infra-axillary thoracotomy (RVIAT) is favored by both patients' families and doctors, and is now routinely used for simple CHD like atrial and VSD in infants and young children. Previous studies [5,6] have primarily focused on the efficacy of peripheral extracorporeal circulation-assisted or non-assisted thoracoscopic RVIAT for treating adult congenital heart disease, while reports of RVIAT performed under central extracorporeal circulation for adult congenital heart disease are limited. However, for adult CHD, the use of the RVIAT is less common due to higher body mass, deeper surgical fields, difficulty in deep instrument manipulation, and challenges in managing intraoperative complications. However, we combined the RVIAT with totally thoracoscopic (TT) repair using central extracorporeal circulation. This approach broadens the surgical field, saves operative time, and avoids the use of peripheral extracorporeal circulation via the neck and groin vessels, reducing the risk of peripheral nerve or vascular injury, such as femoral artery and vein stenosis, arteriovenous fistula, femoral nerve injury, and jugular arteriovenous fistula [7]. In this study, we explored the feasibility, indications, and limitations of treating adult ASD using thoracoscopic-assisted right vertical infra-axillary thoracotomy (TARVIAT) under central extracorporeal circulation, TT, and MS approaches.

Methods

A retrospective study was carried out on 201 patients who had their atrial septal defect (ASD) surgically repaired at our facility between January 2019 and June 2023. Based on the surgical approach, the patients were retrospectively categorized into three groups: the TARVIAT group ($n = 62$) underwent a right axillary vertical small incision approach with trans-centered paracardiac extracorporeal circulation assistance; the TT group ($n = 67$) underwent a full thoracoscopic assisted approach under peripheral extracorporeal circulation; and the MS group ($n = 72$) underwent a median sternotomy approach. Transesophageal echocardiogram was used for preoperative diagnosis, ASD size estimation, and pulmonary artery pressure measurement. Age ≥ 18 years, pulmonary artery systolic pressure < 60 mm Hg, or absence of right-to-left shunting on echocardiography, no history of lung disease or prior right thoracic surgery, absence of other cardiovascular or chronic diseases, catheter closure failure, or preference for surgical repair by the patient and family were the inclusion criteria for selective ASD repair. Age greater than eighteen years, patients with pulmonary artery pressure greater than moderate as determined by right cardiac catheterization and pulmonary resis-

tance greater than eighteen wood, and echocardiographic evidence of right-to-left shunting at the level of the atrial septum were the exclusion criteria. All 201 patients gave their informed consent and fulfilled the requirements for surgery.

Anesthesia

After induction of general anesthesia, a double-lumen endotracheal tube was placed to allow for single-lung ventilation in the TT and TARVIAT groups, and a single-lumen endotracheal tube was placed in the MS group. The respiration rate was set at 18 to 30 breaths/min, and the arterial oxygen saturation rate was maintained at $> 97\%$.

Operative Technique

TARVIAT group: The patient is positioned in the left lateral decubitus position with an incision length of 4–6 cm, extending from the third to the fifth intercostal space (Fig. 1). The right side is elevated by 50° to 70° . The right arm is suspended over the head and secured to a frame. Standard disinfection procedures are followed, and intravenous antibiotics are administered 30 minutes prior to skin incision to prevent infection. A right axillary incision is made at the 4th intercostal space. The patient's breathing is temporarily interrupted to allow the right lung to retract posteriorly, exposing the pericardium. The pericardium is incised parallel to the phrenic nerve, 2–3 cm anterior to it, and suspended. A wet gauze is placed to protect the right lung tissue during pericardial suspension. Three traction sutures are placed: one approximately 1 cm cranial to the superior vena cava-right atrium junction, one in the middle of the right atrium, and one at the inferior vena cava-right atrium junction. The pericardium is further incised cranially to about 1 cm from the pericardial reflection on the aorta, with two traction sutures placed laterally to fully expose the aorta and right side of the heart. A thoracoscope is inserted through a port created in the 6th intercostal space between the anterior and mid-axillary lines. After complete heparinization, cannulation of the ascending aorta, superior, and inferior vena cava is performed, and cardiopulmonary bypass (CPB) is established (Fig. 2). The ascending aorta is clamped, and cold crystalloid cardioplegia (Baxter, S2310104, Shanghai, China) is administered to achieve cardiac arrest. The right atrium is incised for intracardiac exploration, and a bovine pericardial patch of appropriate size is used for continuous suturing to close the atrial septal defect (Fig. 3). In cases of moderate to severe tricuspid regurgitation without structural abnormalities, a tricuspid annuloplasty ring is placed. If a patent foramen ovale is present, it is closed with continuous sutures. Venting of the left heart continued through the aortic root vent. The ascending aorta was opened, and the heart spontaneously restarted with sinus rhythm. Transesophageal echocardiography (TEE) confirmed the disappearance of atrial level shunt and the

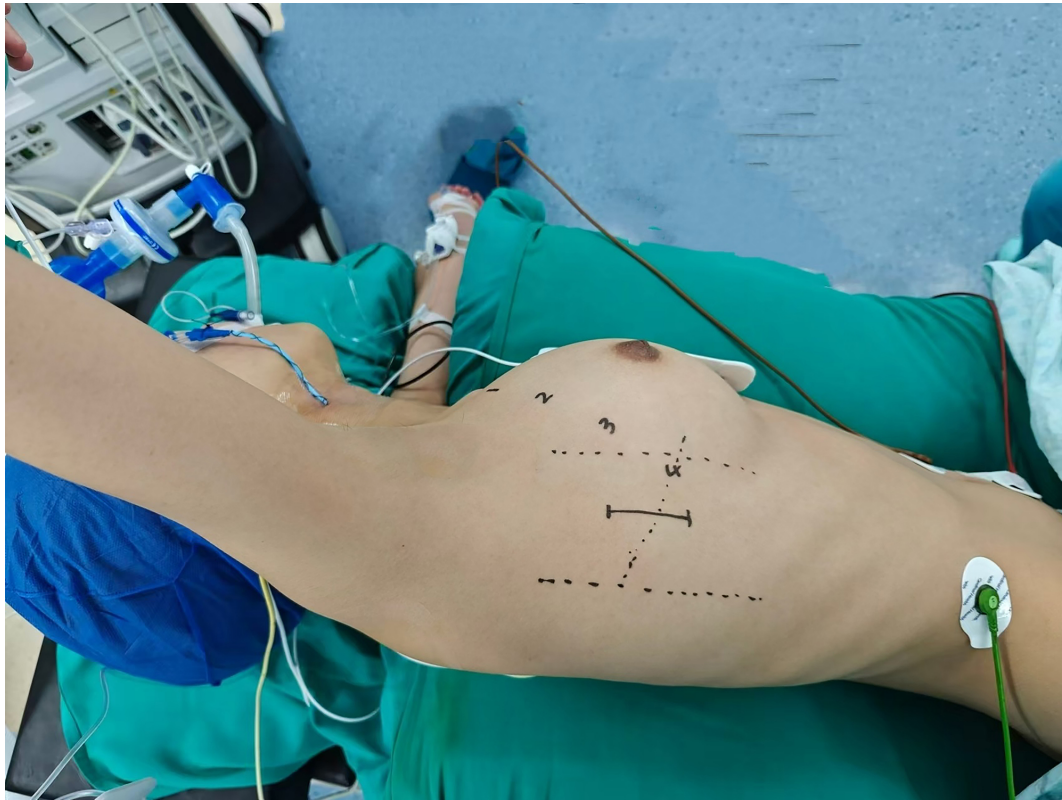


Fig. 1. Thoracoscopic-assisted right vertical infra-axillary thoracotomy (TARVIAT) preoperative position and incision location: midaxillary line between the third and fifth ribs.

absence of tricuspid regurgitation. The right atrial incision was closed. Rewarming was performed, and cardiopulmonary bypass was successfully discontinued. Protamine (Qianhong Bio-pharma, 1524080894, Changzhou, China) was administered to neutralize heparin (Shanghai Pharma, 2312202, Shanghai, China). A right chest drainage tube was placed through the thoracoscope incision. Hemostasis was carefully achieved, and the chest was closed (Fig. 4). The patient was then transferred to the intensive care unit (ICU).

TT group: The patient was placed in the supine position under general anesthesia with a double-lumen endotracheal tube. Standard monitoring was established, including electrocardiogram (ECG), invasive venous pressure, and invasive arterial pressure, with a right jugular vein catheter in place. Make three incisions, each measuring 1 to 3 centimeters, at the second intercostal space on the right side of the sternum, the fourth intercostal space on the anterior axillary line of the right side, and the third intercostal space on the midaxillary line of the right side (Fig. 5). The pericardium was opened and suspended. The right femoral artery and vein were isolated, and systemic heparinization was performed. CPB was established via the femoral artery, jugular vein, and femoral vein, with a left heart vent inserted through the pulmonary vein. Cooling was initiated, and the ascending aorta was clamped. Antegrade cardioplegia was administered through the aortic root, achieving

satisfactory cardiac arrest. The atrial septal defect was exposed and repaired with a bovine pericardial patch. TEE confirmed the absence of atrial-level shunt and tricuspid regurgitation. The right atrium was closed, and the left heart was thoroughly vented. Rewarming was initiated, and the aortic clamp was removed. The heart spontaneously restarted with sinus rhythm. After achieving adequate circulation, cardiopulmonary bypass was gradually weaned, and the cannulas were removed. Heparin was neutralized. Hemostasis was achieved, a right chest drainage tube was placed, and the chest was closed in layers. The patient was then transferred to the ICU.

MS group: The patient was placed in a supine position with a median sternotomy performed. The thymus was removed, and the pericardium was opened to expose the heart. Aortic and venous cannulation was done to establish CPB. The ascending aorta was clamped, and cold crystalloid cardioplegia was administered, resulting in cardiac arrest. The right atrium was opened, and an intracardiac examination was conducted. The ASD was repaired using a bovine pericardial patch with continuous sutures. Aortic root venting was maintained, and the ascending aorta was unclamped, allowing the heart to resume beating in sinus rhythm. TEE confirmed the absence of atrial-level shunting and tricuspid regurgitation. The right atrial incision was closed. Rewarming was initiated, and CPB was weaned off smoothly, with heparin neutralized by protamine. One

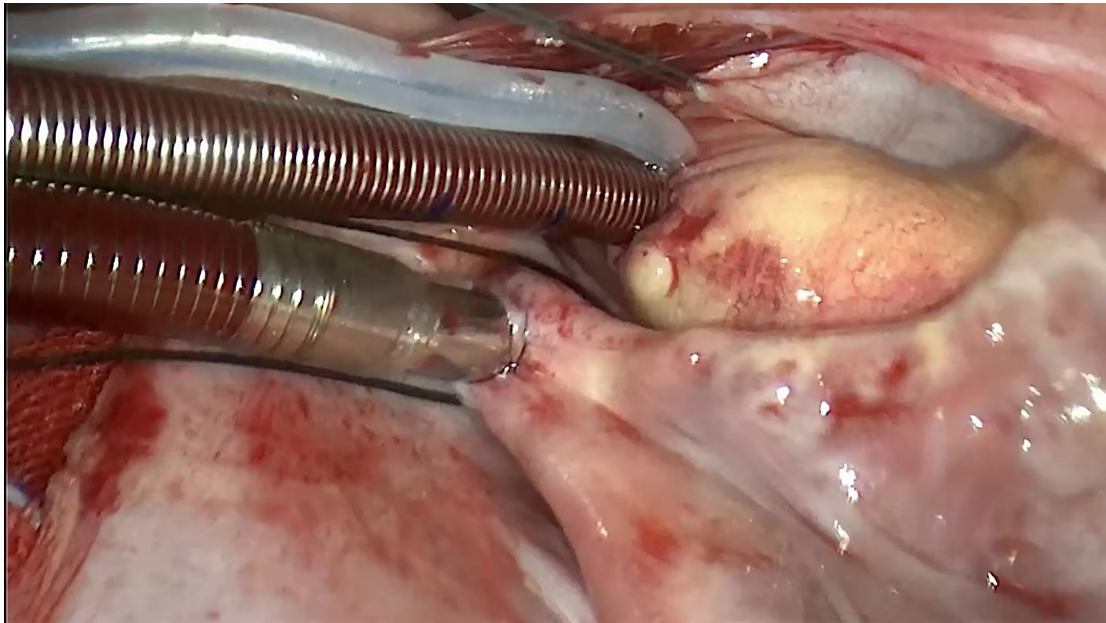


Fig. 2. Cardiopulmonary bypass was established by cannulation of the aorta and superior and inferior venae cavae.

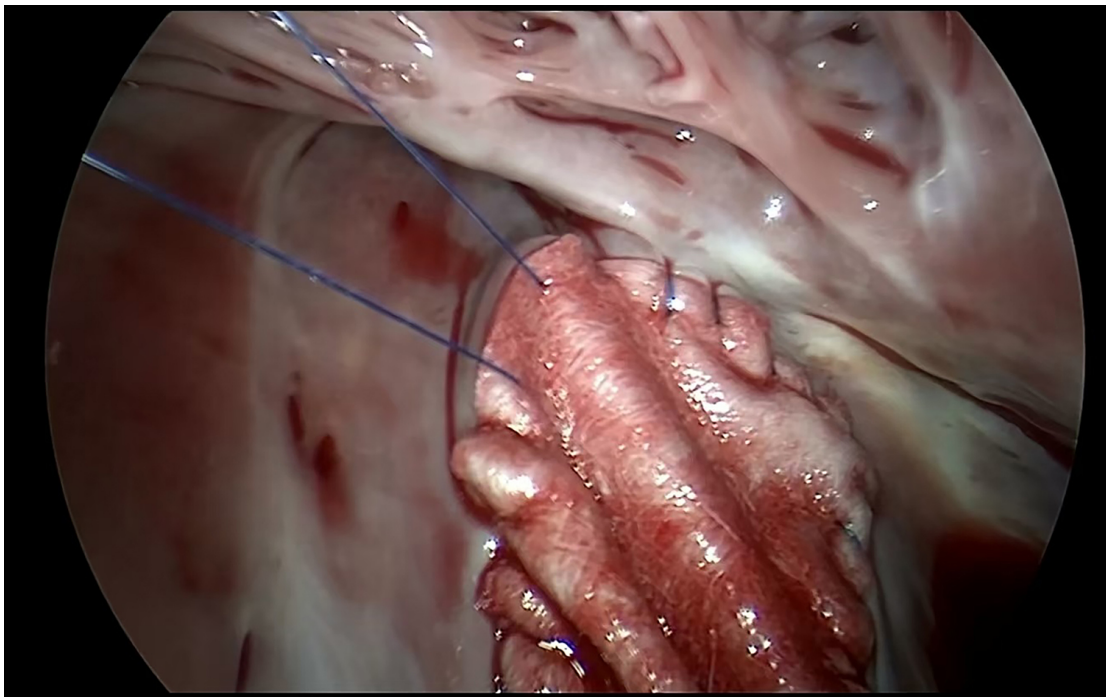


Fig. 3. Patch the atrial septal defects (ASD).

mediastinal and one pericardial drain were placed, meticulous hemostasis was achieved, and the chest was closed routinely. The patient was then transferred to the ICU. Any associated cardiac anomalies were corrected concurrently.

Postoperative Management

Postoperatively, the patient was transferred to the ICU and was administered inotropic and diuretic therapy. Bed-side chest X-rays and echocardiography were performed

to monitor for pulmonary infections and related complications. Once the patient's hemodynamic status stabilized, mechanical ventilation was discontinued, the endotracheal tube was removed, and the patient was transferred to the general ward.

Statistical Analysis

Statistical analysis was done by SPSS 26.0 version software (USA, Chicago, IL, USA). Data were defined as

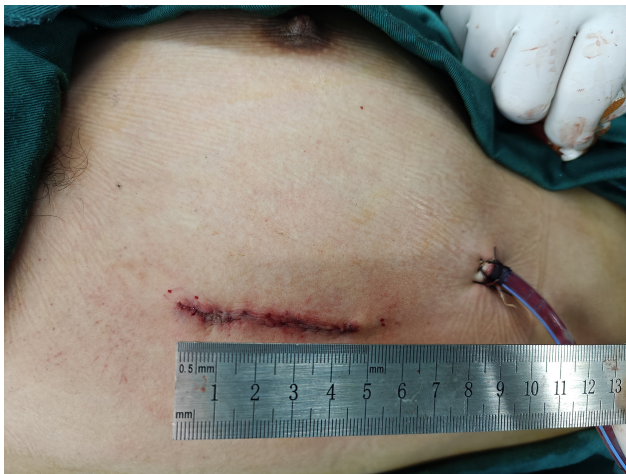

Fig. 4. The length of the incision was approximately 5 cm at the end of the procedure.

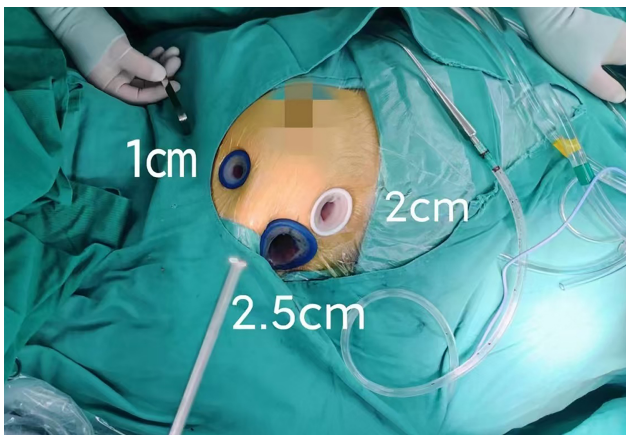


Fig. 5. Thoracoscopic incision.

continuous and categorical variables. Continuous variables were expressed as mean \pm standard and categorical variables were expressed as the χ^2 or Fisher's test. Independent sample *t*-test was used for comparison between groups. *p* value < 0.05 were defined as statistical significance.

Results

Demographic and Clinical Characteristics

There were 62 patients in the TARVIAT group, and 22 of them (35.48%) were men, Table 1. The weight was 65.41 ± 11.54 kg, the defect diameter was 34.62 ± 5.31 mm, and the average age was 33.35 ± 10.97 years. Of the 67 patients in the TT group, 27 (40.30%) were men. The average age, weight, and defect diameter were 34.69 ± 10.59 years, 61.74 ± 11.03 kg, and 31.91 ± 5.22 mm, respectively. Out of the 72 patients in the MS group, 26 (36.11%) were male. The weight was 57.59 ± 10.60 kg, the defect diameter was 31.92 ± 8.34 mm, and the average age was

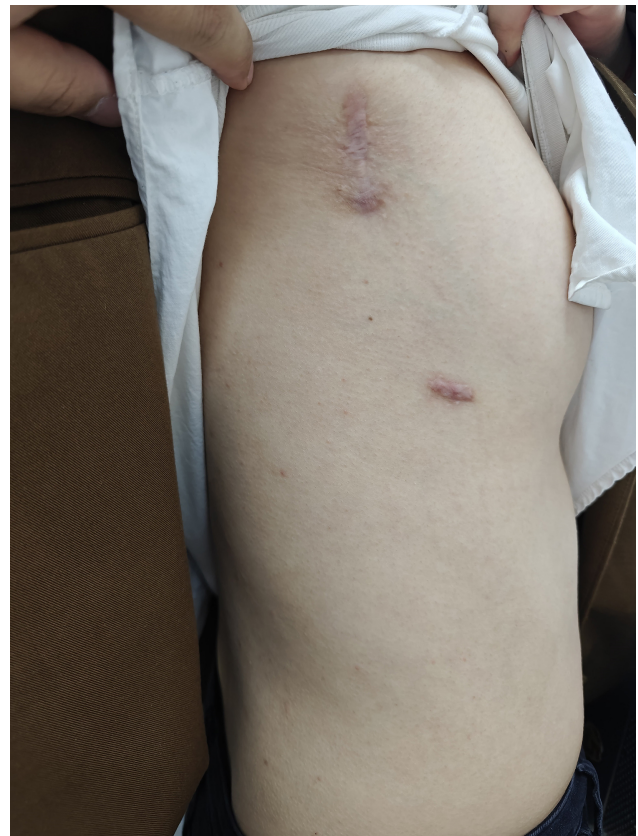

Fig. 6. TARVIAT Postoperative incision recovery of patients.

37.40 ± 11.58 years. The TARVIAT group, TT group, and MS group did not differ significantly in terms of gender or concurrent cardiac abnormalities ($p > 0.05$). Weight, age, and defect size showed statistically significant differences between the TARVIAT and MS groups ($p < 0.05$). The TT group had a higher weight than the MS group ($p < 0.05$), while the tarviat group had a defect diameter greater than the TT group ($p < 0.05$).

Perioperative Profile

Three cohorts totaling 201 patients all had successful surgical results and no deaths. No conversion to a median sternotomy was necessary in the TT and RVIAT cohorts, and all patients were routinely moved to the intensive care unit (ICU) and given powerful cardiac support, diuretics, dopamine, and other vasoactive drugs. Table 2 shows that there were no statistically significant differences in hospital expenses between the three cohorts, but there were significant differences in CPB time, aortic occlusion time, surgical duration, postoperative 24-hour chest drainage volume, postoperative mechanical ventilation duration, postoperative ICU stay duration, incision length, and postoperative hospital stay ($p < 0.05$). In the comparison of the cohorts, the TARVIAT cohort showed a higher 24-hour chest drainage volume than the TT cohort ($p < 0.05$), but it also showed considerably lower CPB time, aortic occlusion

Table 1. Preoperative patient data.

Variable	TARVIAT group (n = 62)	TT group (n = 67)	MS group (n = 72)	<i>p</i> value
Gender (female)	22 (35.48%)	27 (40.30%)	26 (36.11%)	0.823
Weight (kg) ^{†,‡}	65.41 ± 11.54	61.74 ± 11.03	57.59 ± 10.60	0.000
Age (y) [†]	33.35 ± 10.97	34.69 ± 10.59	37.40 ± 11.58	0.097
Defect size (mm) ^{*,†}	34.62 ± 5.31	31.91 ± 5.22	31.92 ± 8.34	0.027
LVEF (%)	61.39 ± 3.70	60.37 ± 2.62	60.51 ± 2.39	0.107
Concomitant other cardiac anomalies				
TR moderate or severe	5 (8.06%)	2 (2.99%)	6 (8.33%)	0.368
PFO	16 (25.81%)	18 (26.87%)	21 (29.17%)	0.904
RVOT	0	0	1 (1.39%)	0.406

TARVIAT, thoracoscopic-assisted right vertical infra-axillary thoracotomy; LVEF, left ventricular ejection fraction; TT, totally thoracoscopic; MS, median sternotomy; TR, tricuspid regurgitation; PFO, patent foramen ovale; RVOT, right ventricular outflow tract. Statistically significant difference between groups are as follows: noted in superscript mark-up: *Significant difference between the TARVIAT group and TT group. †Significant difference between TARVIAT group and MS group. ‡Significant difference between TT group and MS group and neither the chi-square test nor Fisher's exact probability method revealed statistically significant differences between the groups ($p > 0.05$).

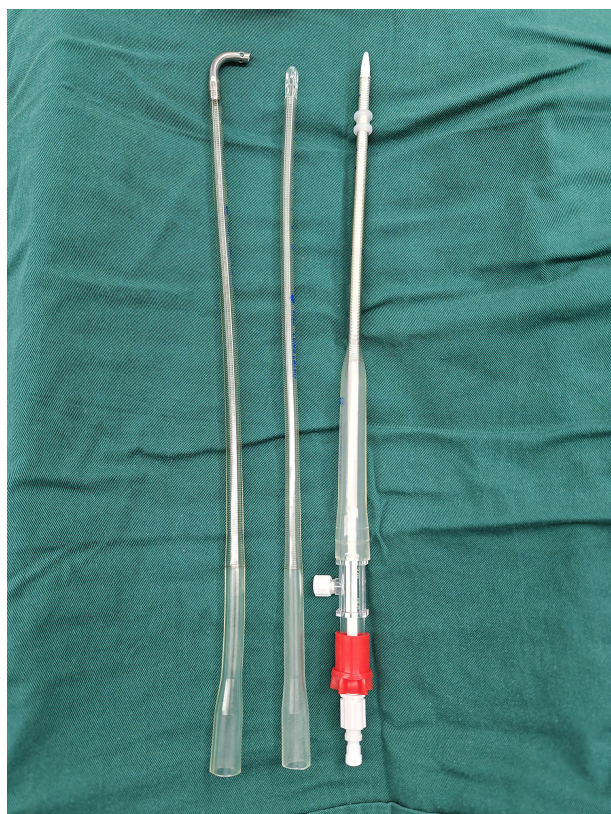

Fig. 7. On the left is a 20# superior vena cava catheter, in the middle is a 20# inferior vena cava catheter, and on the right is a 19# aortic catheter.

time, and surgical length. The length of the incision, the duration of the postoperative mechanical breathing, the postoperative ICU stay, the postoperative hospital stay, and the hospital charges did not significantly differ between these two groups ($p > 0.05$). In comparison to the TARVIAT

group ($p < 0.05$) and the TT group ($p < 0.05$), the MS cohort exhibited a significantly longer surgical duration, along with increased postoperative 24-hour chest drainage volume, mechanical ventilation duration, ICU stay duration, incision length, and hospital stay. Furthermore, the TT group's CPB and aortic occlusion times were substantially greater than those of the MS group ($p < 0.05$).

Post-operative Complications Comparison

There were no hospital deaths throughout the three successful procedures. After ASD repair, all patients had echocardiograms, which showed no neurological sequelae or hypoperfusion syndrome, full closure of the ASD, little regurgitation of the tricuspid valve, lack of residual shunts, conduction block, or recurrent thoracotomy. Two patients experienced pneumothorax: one in the MS group (1.39%) and one in the TARVIAT group (1.61%), with no statistically significant difference ($p > 0.05$). For more information, see Table 3. This might have happened when the chest drain was removed and gas entered the chest. Three patients in the MS group (4.17%), one in the TT group (1.49%), and one in the TARVIAT group (1.61%), all had wound infections or poor healing. Between the groups, there was no statistically significant difference ($p > 0.05$). Longer incisions, more stress, a slower rate of patient recovery, and more sutures that result in suture response could all be contributing factors to the higher rate of wound infection or poor healing in the MS group. While in the intensive care unit, one patient from each of the TARVIAT group (1.61%) and the TT group (1.49%) experienced transitory atrial tachycardia. This was treated with medicine, and the patients' sinus rhythm returned. There was no statistically significant difference between the groups.

Table 2. Peri-operative and post-operative data comparison among three groups of patients.

Variable	TARVIAT group (n = 62)	TT group (n = 67)	MS group (n = 72)	p value
CPB time (min) ^{*,‡}	69.95 ± 15.86	98.51 ± 11.33	69.53 ± 16.22	0.000
Crossclamp time (min) ^{*,‡}	38.73 ± 12.16	50.76 ± 11.62	37.03 ± 10.85	0.000
Total operative time (min) ^{*,†}	123.08 ± 17.41	195.52 ± 18.01	191.04 ± 21.39	0.000
Postoperative 24 hours drainage (mL/24 h) ^{*,‡}	326.73 ± 33.57	261.42 ± 52.53	499.51 ± 62.80	0.000
Postoperative intubation time (h) ^{*,†,‡}	6.13 ± 1.54	7.54 ± 1.47	9.85 ± 1.94	0.000
Postoperative ICU stay (h) ^{†,‡}	22.75 ± 4.16	23.83 ± 4.53	39.72 ± 7.10	0.000
Incision length (cm) ^{†,‡}	5.74 ± 0.35	5.80 ± 0.33	18.39 ± 1.04	0.000
Postoperative hospital stay (d) ^{†,‡}	6.61 ± 1.11	6.93 ± 1.50	9.81 ± 1.11	0.000
Hospital costs (1000 CNY)	76.05 ± 10.62	78.00 ± 6.88	78.65 ± 10.37	0.371

CPB, cardiopulmonary bypass; ICU, intensive care unit. Statistically significant difference between groups are as follows: noted in superscript mark-up: *Significant difference between the TARVIAT group and TT group. †Significant difference between TARVIAT group and MS group. ‡Significant difference between TT group and MS group.

Table 3. Post-operative complications comparison between two group of patients.

Variable	TARVIAT group (n = 62)	TT group (n = 67)	MS group (n = 72)	p value
Complications (n)				
Residual shunt	0	0	0	
Atrioventricular block	0	0	0	
Incision infection/bad healing	1 (1.61%)	1 (1.49%)	3 (4.17%)	0.625
Rethoracotomy for bleeding	0	0	0	
Neurological complication	0	0	0	
Pneumothorax	1 (1.61%)	0	1 (1.39%)	0.760
Low cardiac output syndrome	0	0	0	
Transient arrhythmia	1 (1.61%)	1 (1.49%)	0	0.538

Outcomes of Postoperative Follow-up

Following a one-month, six-month, and one-year follow-up of the patients' left ventricular ejection fraction (LVEF) values to evaluate any possible differences in post-operative cardiac function between the three groups, Table 4 clearly shows that there are no statistically significant differences in LVEF values between the three groups at these time points ($p > 0.05$). This implies that there is no appreciable difference in the three surgical techniques' immediate postoperative cardiac performance; yet, longer follow-up is necessary to assess the long-term cardiac function.

Discussion

While the traditional mid-sternotomy provides excellent exposure and serves as the classical approach for cardiovascular surgeries, meeting the requirements of various cardiac procedures, it is associated with significant trauma, substantial bleeding, prolonged hospitalization, and a high risk of wound infection, along with noticeable scarring that can adversely affect patients psychologically [8,9]. In the

past two decades, various minimally invasive techniques have been applied in congenital heart surgeries, including right lateral thoracotomy, right anterolateral (submammary) thoracotomy, partial sternotomy, and transaxillary incision [10–14]. In most medical centers, the right anterolateral minimally invasive incision involves dissecting breast tissue, affecting breast growth and sensation, particularly in female patients. The RVIAT is located along the axillary midline, away from breast and chest muscle tissue, accessing the chest cavity through the space between the serratus anterior muscles, requiring only intercostal muscle dissection. A retrospective analysis [15] of 1672 patients with congenital heart disease who underwent treatment via the RVIAT at Fuwai Hospital between 2015 and 2019 was conducted. The study concluded that for various congenital heart defects, the RVIAT can be safely performed, being distant from breast tissue, facilitating normal breast development, and yielding excellent cosmetic results. It can serve as a favorable alternative to mid-sternotomy, especially for young female patients. Initially, the RVIAT was primarily used in children and adolescents for repairing ASD and perimembranous VSD through the right atrium. However, due to the deep thoracic cavity and limited rib elasticity, exposure of the operative field in

Table 4. Reassessment of cardiac function in postoperative patients.

Variable	TARVIAT group (n = 62)	TT group (n = 67)	MS group (n = 72)	<i>p</i> value
LVEF at one month post-operation	59.42 ± 3.51	59.30 ± 3.68	60.19 ± 3.04	0.219
LVEF at six month post-operation	59.39 ± 3.67	60.10 ± 2.58	59.44 ± 3.00	0.278
LVEF at one year post-operation	59.94 ± 2.72	60.78 ± 2.47	60.50 ± 2.95	0.188

LVEF, left ventricular ejection fraction.

adults is more challenging compared to children. Consequently, it was previously believed that individuals weighing over 30 kg were not suitable candidates for this approach [16]. Nevertheless, with accumulated experience, a higher body weight is no longer considered a limiting factor for surgical indications. This study demonstrates this fact by including a patient with the highest weight of 99.3 kg in the TARVIAT group. Furthermore, advancements in technology have made full thoracoscopic heart surgery possible without relying on the Da Vinci system. The full thoracoscopic technique only requires three small incisions ranging from 1.0–2.5 cm [17]. The main advantage of thoracoscopic surgery is that it causes minimal pain and trauma, avoids the need for a large incision in the chest and the use of wires, reduces postoperative bleeding, and results in smaller drainage from chest tubes [18]. However, because it provides a two-dimensional visual image without depth perception and requires more time to learn, it typically takes longer to perform compared to other methods. Based on our data, we can see that the TT group requires more surgical time, CPB time, and aorta occlusion time than the TARVIAT group. However, there is no significant difference between the two groups in terms of postoperative ICU stay, hospital stay, mechanical ventilation time or hospital expenses. It's worth noting that within 24 hours after surgery, the TT group had less drainage from chest tubes compared to the TARVIAT group. This may be due to its smaller incision and less damage to small blood vessels. Compared to the mini-incision in the right armpit, a full thoracoscopic operation often takes longer and requires extensive experience with thoracoscopic procedures. It also necessitates the use of peripheral extracorporeal circulation. However, most cardiac surgeons are used to inserting a cannula into the ascending aorta. Currently, common complications associated with peripheral extracorporeal circulation include bleeding, thrombosis, and hemolysis [19]. There have also been reports of limb ischemia when using femoral artery cannulation without preventive measures, which can negatively impact survival or long-term functional outcomes [20]. In their follow-up study on 62 patients who underwent atrial septal defect closure through full thoracoscopic surgery at their hospital, Xu *et al.* [21] found that two patients were unhappy with the scar length in the groin area caused by the peripheral extracorporeal circulation cannula. Our TARVIAT technology mitigates the complications associated with scarring, vein oc-

clusion, and blood vessel narrowing or ischemia induced by femoral and venous catheters. The TARVIAT approach is a surgical technique for treating CHD in adults that combines a mini-incision on the right side of the armpit with a thoracoscopic approach. It uses special instruments and central CPB to repair defects while the surgeon can see everything clearly. However, sometimes the mini-incision doesn't provide a good view due to the deep chest cavity in adults. To solve this problem, an endoscope lens is placed through the 6th rib space to fully expose the field of view and assist the surgeon during surgery. With this technique, the surgeon can perform operations directly through the mini-incision while also viewing a monitor, making it easier to operate on a larger area. Compared to total thoracoscopic techniques, this method significantly reduces surgical time, extracorporeal circulation time, and aortic occlusion time. This means less time for cardiac arrest and better protection for the heart. The TARVIAT approach has some great benefits, like causing less damage to the tissues and leaving a more attractive incision. It doesn't involve cutting any muscles outside of the intercostal ones and maintains the natural space between the ribs and thoracic nerve. The incision is made in the axillary midline, which can be easily hidden by a drooping arm, making it look like a regular scar rather than one caused by heart surgery (Fig. 6). During the surgical process for adult congenital heart disease using this approach with extracorporeal circulation, there are a few important details to consider. Firstly, before applying the chest retractor, a protective ring is placed on the incision site and then divided into thirds to protect the skin edge. Secondly, a blunter aortic cannula, a 19# aortic catheter is typically selected, along with a 20# superior vena cava and inferior vena cava catheter (Fig. 7), the goal is to minimize the risk of piercing the posterior wall of the aorta during surgery. Lastly, carbon dioxide is injected into the chest cavity during operation to prevent air embolism since all air in the left atrium gets absorbed easily as carbon dioxide. Additionally, transesophageal echocardiography is used to check for any remaining air in either atria or ventricles. It is noteworthy that the TARVIAT treatment of adult congenital heart disease atrial septal defect under cardiopulmonary bypass necessitates a certain level of expertise. Prior to gaining this skill, the surgeon should be proficient in the RVIAT method for treating children's atrial septal defect and simple ventricular septal defect.

Limitations

This retrospective study was conducted at a single center with a sample size of 201 patients, which is relatively small. Future studies on a larger scale are necessary to validate the reliability of the results. Clearly, a longer follow-up period is required to assess the effectiveness of ASD closure.

Conclusions

In conclusion, both the TARVIAT approach and TT approach for repairing adult ASD with extracardiac circulation through the centrosome demonstrate favorable cosmetic outcomes and acceptable clinical results without any instances of surgical mortality or major complications. These approaches can serve as viable alternatives to the MS approach, with the noteworthy observation that the TARVIAT group may necessitate reduced surgical time, CPB time, and aortic occlusion time. Further investigation into this matter is warranted.

Availability of Data and Materials

All data points generated or analyzed during this study are included in this published article.

Author Contributions

HZ contributed to the design of this work. HC and CY contributed to the interpretation of data. SS and HD and MX analyzed the data. HZ drafted the work. WL and TF analyzed the data and revised critically for important intellectual content. All authors read and approved the final manuscript. All authors contributed to editorial changes in the manuscript. All authors agree to be accountable for all aspects of the work in ensuring that questions related to the accuracy or integrity of any part of the work are appropriately investigated and resolved.

Ethics Approval and Consent to Participate

Zhengzhou University Central China Fuwai Hospital (institutional review board approval date August 5, 2019, #2019-Q009-01). All patients signed informed consent.

Acknowledgment

Not applicable.

Funding

Medical Science and Technology Research Program of Henan Province (LHGJ20210088).

Conflict of Interest

The authors declare no conflict of interest.

References

- [1] Bradley EA, Zaidi AN. Atrial Septal Defect. *Cardiology Clinics*. 2020; 38: 317–324.
- [2] Mirzai S, Hibino N, Torregrossa G, Balkhy HH. Adult Ventricular Septal Defect Repair Using a Robotic Totally Endoscopic Approach: A Case Report. *Innovations (Philadelphia, Pa.)*. 2020; 15: 372–375.
- [3] Schipper M, Sliker MG, Schoof PH, Breur JMPJ. Surgical Repair of Ventricular Septal Defect; Contemporary Results and Risk Factors for a Complicated Course. *Pediatric Cardiology*. 2017; 38: 264–270.
- [4] Hong ZN, Chen Q, Lin ZW, Zhang GC, Chen LW, Zhang QL, *et al*. Surgical repair via submammary thoracotomy, right axillary thoracotomy and median sternotomy for ventricular septal defects. *Journal of Cardiothoracic Surgery*. 2018; 13: 47.
- [5] Luo H, Wang J, Qiao C, Zhang X, Zhang W, Song L. Evaluation of different minimally invasive techniques in the surgical treatment of atrial septal defect. *The Journal of Thoracic and Cardiovascular Surgery*. 2014; 148: 188–193.
- [6] Zhang Q, Zhou ZC, Lin M, Wang HT, Zhao ZW, Ge JJ. Thoracoscope-assisted Right Vertical Infra-axillary Mini-incision for Cardiac Surgery. *Heart, Lung & Circulation*. 2015; 24: 590–594.
- [7] Zhou K, Yang L, He BC, Ke YJ, Yang YC, Yan Q, *et al*. Total thoroscopic repair of ventricular septal defect: A single-center experience. *Journal of Cardiac Surgery*. 2021; 36: 2213–2218.
- [8] Fukunaga N, Yuzaki M, Shomura Y, Fujiwara H, Nasu M, Okada Y. Clinical outcomes of open heart surgery in patients with atopic dermatitis. *Asian Cardiovascular & Thoracic Annals*. 2012; 20: 137–140.
- [9] Hu CX, Tan J, Chen S, Ding H, Xu ZW. Comparison of clinical outcomes and postoperative recovery between two open heart surgeries: minimally invasive right subaxillary vertical thoracotomy and traditional median sternotomy. *Asian Pacific Journal of Tropical Medicine*. 2014; 7: 625–629.
- [10] Del Nido PJ. Minimally Invasive Cardiac Surgical Procedures in Children. *Innovations (Philadelphia, Pa.)*. 2020; 15: 95–98.
- [11] Mohamed KS. Minimally invasive right posterior minithoracotomy for open-heart procedures. *Asian Cardiovascular & Thoracic Annals*. 2007; 15: 468–471.
- [12] Formigari R, Di Donato RM, Mazzer E, Carotti A, Rinelli G, Parisi F, *et al*. Minimally invasive or interventional repair of atrial septal defects in children: experience in 171 cases and comparison with conventional strategies. *Journal of the American College of Cardiology*. 2001; 37: 1707–1712.
- [13] Seipelt RG, Popov A, Danner B, Paul T, Tirilomis T, Schoen-dube FA, *et al*. Minimally invasive partial inferior sternotomy for congenital heart defects in children. *The Journal of Cardiovascular Surgery*. 2010; 51: 929–933.
- [14] Gil-Jaurena JM, Zabala JI, Conejo L, Cuenca V, Picazo B, Jiménez C, *et al*. Minimally invasive pediatric cardiac surgery. Atrial septal defect closure through axillary and submammary

- approaches. *Revista Espanola De Cardiologia*. 2011; 64: 208–212.
- [15] An K, Li S, Yan J, Wang X, Hua Z. Minimal Right Vertical Infra-axillary Incision for Repair of Congenital Heart Defects. *The Annals of Thoracic Surgery*. 2022; 113: 896–902.
- [16] Yang M, Su J, Liu A, Fan X, Li G, Li B, *et al*. Correction of simple congenital heart defects by right axillary thoracotomy in adults. *Journal of Cardiac Surgery*. 2019; 34: 1172–1177.
- [17] Wang F, Li M, Xu X, Yu S, Cheng Z, Deng C, *et al*. Totally thoracoscopic surgical closure of atrial septal defect in small children. *The Annals of Thoracic Surgery*. 2011; 92: 200–203.
- [18] Liu G, Qiao Y, Ma L, Ni L, Zeng S, Li Q. Totally thoracoscopic surgery for the treatment of atrial septal defect without of the robotic Da Vinci surgical system. *Journal of Cardiothoracic Surgery*. 2013; 8: 119.
- [19] Strunina S, Hozman J, Ostadal P. The peripheral cannulas in extracorporeal life support. *Biomedizinische Technik. Biomedical Engineering*. 2019; 64: 127–133.
- [20] Bonicolini E, Martucci G, Simons J, Raffa GM, Spina C, Lo Coco V, *et al*. Limb ischemia in peripheral veno-arterial extracorporeal membrane oxygenation: a narrative review of incidence, prevention, monitoring, and treatment. *Critical Care (London, England)*. 2019; 23: 266.
- [21] Xu M, Zhu S, Wang X, Huang H, Zhao J. Two Different Minimally Invasive Techniques for Female Patients with Atrial Septal Defects: Totally Thoracoscopic Technique and Right Anterolateral Thoracotomy Technique. *Annals of Thoracic and Cardiovascular Surgery: Official Journal of the Association of Thoracic and Cardiovascular Surgeons of Asia*. 2015; 21: 459–465.