

## Epicardial Cysts: Report of Two Rare Cases

Ali Can Hatemi, MD, PhD,<sup>1</sup> Ulas Kumbasar, MD,<sup>2</sup> Ercan Servet,<sup>1</sup> Ugur Coskun,<sup>3</sup>  
Cem Bostan,<sup>3</sup> Büge Oz<sup>4</sup>

<sup>1</sup>Department of Cardiovascular Surgery, Istanbul University Cardiology Institute; <sup>2</sup>Department of Cardiovascular Surgery, Ahi Evran University, Kirsehir State Hospital; <sup>3</sup>Department of Cardiology, Istanbul University Cardiology Institute; <sup>4</sup>Department of Pathology, Istanbul University, Cerrahpasa Medical Faculty

### ABSTRACT

Epicardial cysts originating directly from the epicardium are seen very rarely. Complete surgical excision is recommended when these cysts are detected. If cysts compress surrounding vital structures, cardiopulmonary bypass (CPB) should also be considered. We report herein 2 cases of multiloculated epicardial cysts, both of which were successfully excised, 1 with CPB.

### INTRODUCTION

Although many authors have reported several cases of pericardial cysts, the incidence of epicardial cysts originating directly from the epicardium is extremely low. Including the first report of Edwards and Ahmad, only 6 cases in total have been reported to date [Edwards 1972; Komeda 1985; Ozasa 1991; Scrofani 2002; Omeroglu 2004; Buyukates 2008]. We report herein 2 cases of multiloculated epicardial cysts that were successfully excised.

### CASE REPORTS

#### Case 1

A 50-year-old woman presented with dyspnea and persistent cough of 1-week duration. The heart rate was regular at 96 beats per minute, and the blood pressure was 100/60 mmHg. Electrocardiogram (ECG), chest roentgenogram, and laboratory studies were normal. Transthoracic echocardiography (TTE) revealed circumferential pericardial effusion, and the patient was sent to the intensive care unit (ICU) for diagnostic and therapeutic pericardiosynthesis. Approximately 900 mL of clear fluid was drained with pericardiosynthesis and sampled for diagnostic evaluation. Routine cytologic, microbiologic, and biochemical investigations of the fluid showed no abnormality. The patient was discharged with medical therapy (nonsteroidal anti-inflammatory drug

and colchicum) and scheduled for control echocardiography 1 month later.

Control TTE again showed circumferential effusion with dimensions 26 mm behind the left ventricle, 25 mm on lateral surface, and 28 mm in front of the right atrium. Computerized tomography (CT) of the chest also revealed pericardial effusion that is 18 mm in its widest diameter. Diagnostic and therapeutic subxiphoidal approach was performed. Multiple cystic lesions were detected on exploration. Approximately 100 mL serous fluid was drained, and a pericardial tube was inserted to the patient. Histologic, microbiologic, and biochemical examinations were again unremarkable. Following removal of the tube, the patient was discharged with medical therapy.

The control TTE at the second month following discharge again showed significant pericardial effusion that was compressing the right atrium externally, and the initial subxiphoidal exploration revealed cystic lesions, so the decision

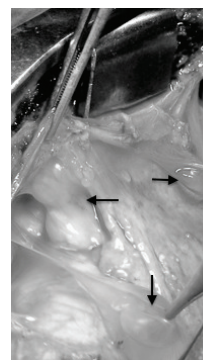


Figure 1. Multiple thin-walled cystic lesions on the whole surface of the heart (black arrows).

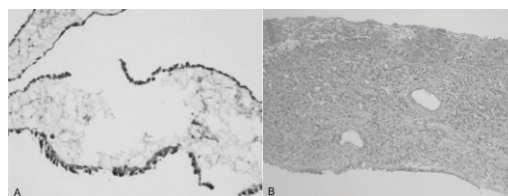


Figure 2. A, Mesothelial cells show diffuse cytoplasmic positivity with calretinin. B, Cyst lumen is lined by a monolayer of flattened mesothelial cells.

Received August 15, 2011; received in revised form October 19, 2011; accepted October 21, 2011.

Correspondence: Ulas Kumbasar, MD, Ahi Evran University, Kirsehir State Hospital, Department of Cardiovascular Surgery, Kirsehir, Turkey; 0090-533-357-10-75; fax: 0090-312-447-57-65 (e-mail: [ulaskumbasar@gmail.com](mailto:ulaskumbasar@gmail.com)).

for diagnostic and therapeutic sternotomy was made. A midline sternotomy was performed, and the pericardium was opened. On exploration, multiloculated, multiple thin-walled cystic lesions were detected on the whole surface of the heart (Figure 1). The pericardial cavity also contained clear fluid. All the cysts were removed, samples were taken for pathologic examination, the fluid was drained, and partial pericardiectomy between both phrenic nerves was performed. Immunohistochemical stains showed these cells to be positive for calretinin, which supported their mesothelial origin. A diagnosis of benign mesothelial cyst was made (Figure 2A).

### Case 2

A 17-year-old woman was admitted to our emergency clinic with shortness of breath and fatigue. Physical examination was normal. Chest x-ray showed enlarged cardiac silhouette. Echocardiographic examination revealed severe pericardial effusion and an 85 × 35 mm intrapericardial cystic mass. Both cardiac CT and magnetic resonance imaging (MRI) showed a high-density homogeneous mass confirming the diagnosis of pericardial cyst. Midline sternotomy was performed, and the pericardium was opened. On exploration, uniloculated and thick-walled cystic mass, which was located over the circumflex branch of the left coronary artery, was detected. In order to avoid damaging this coronary artery and its corresponding vein, cardiopulmonary bypass (CPB) was utilized. The cyst was excised successfully under CPB. On histologic examination, the cyst lumen was lined by a monolayer of flattened mesothelial cells, confirming the diagnosis of epicardial cyst (Figure 2B). Cytologic studies of the fluid revealed no malignancy.

## DISCUSSION

Pericardial cysts are uncommon benign lesions that have an incidence of 1:100,000 [Le Roux 1959]. However, to our knowledge, there are no data in the literature concerning the incidence of epicardial cysts because there are only a few cases reported.

Two major hypotheses about etiology of epicardial cysts have been postulated: Lambert considered that epicardial cysts occur because of failure of coalescence of the mesodermal space [Lambert 1940]; Lillie et al proposed that developmental anomaly of the ventral recesses leads to cyst formation [Lillie 1950].

Epicardial cysts are often diagnosed incidentally, unless they expand and cause compression-related symptoms as in our case. The differential diagnosis includes cystic lesions of the mediastinum such as teratomatous and bronchogenic cysts, lymphangiomas, pericardial fat tissue, lung tumors and lymphomas [Ozasa 1991]. Epicardial cysts are commonly unilocular, but they may become multilocular due to constrictive fibrous bands as in the first case.

In long-term follow-up, most patients remain asymptomatic. However, surgical excision becomes mandatory when the cyst becomes symptomatic, infected, or located atypically or expands and compresses important structures. In our cases, both patients were symptomatic and because of the failure of an accurate diagnosis and exact therapy, symptoms were aggravated in case 1.

Complete excision of the cysts seems to be the most reasonable treatment. However, when cysts compress surrounding vital structures as in case 2 or erode the ventricular or atrial wall, CPB may also be considered. Omeroglu et al reported a case in which the epicardial cyst was located over the left anterior descending (LAD) coronary artery and the cyst was successfully removed under CPB [Omeroglu 2004]. In our first case, there was neither invasion nor compression of the cysts, so the excision was straightforward. However, in the second case, the cyst was located over the epicardium at the posterolateral surface of the left ventricle and adherent to the circumflex branch of the left coronary artery. Thus, CPB was essential.

In conclusion, we believe that pericardial cysts should be kept in mind when pericardial effusion reoccurs or persists despite drainage of the fluid, and accurate diagnosis should be made with further diagnostic examinations such as MRI, transesophageal echocardiography (TEE), or even with surgical exploration. In addition, detailed evaluation of the patient contributes to the selection of the appropriate surgical intervention considering the possibility of epicardial origin of pericardial cysts and the need for CPB.

## REFERENCES

- Buyukates M, Kandemir O, Aktunc E, Tokmakoglu H. 2008. A rare case of epicardial cyst. *Thorac Cardiovasc Surg* 56:167-8.
- Edwards MH, Ahmad A. 1972. Epicardial cyst: a case report. *Thorax* 27:503-6.
- Komeda M, Miki S, Kusuhara K, et al. 1985. Epicardial cyst. Report of a case with successful resection. *Jpn Circ J* 49:1201-5.
- Lambert AV. 1940. Etiology of thin-walled thoracic cysts. *J Thorac Surg* 10:1-7.
- Le Roux BT. 1959. Pericardial coelomic cysts. *Thorax* 14:27-35.
- Lillie WI, McDonald JR, Clagett OT. 1950. Pericardial celomic cysts and pericardial diverticula: a concept of etiology and report of cases. *J Thorac Surg* 20:494-504.
- Omeroglu SN, Omeroglu A, Ardal H, et al. 2004. Epicardial mesothelial cyst located over the left anterior descending coronary artery. *Tex Heart Inst J* 31:313-5.
- Ozasa A, Nakazawa K, Kamegai M, et al. 1991. A case of epicardial cyst. *Jpn Circ J* 55:53-7.
- Scrofani R, Carro C, Beretta L, Antona C. 2002. Successful resection of an epicardial cyst. *Ann Thorac Surg* 73:1633-4.