

Case Report

Very Delayed Surgical Bleeding after Coronary Artery Bypass Graft Causing Cardiac Tamponade and Cardiogenic Shock: A Rare Case Report

Wei-Ting Kuo^{1,2,3}, Yi-Ting Tsai¹, Chih-Yuan Lin¹, Hsiang-Yu Yang^{1,4,*}, Chien-Sung Tsai^{1,*}

¹Division of Cardiovascular Surgery, Department of Surgery, Tri-Service General Hospital, National Defense Medical Center, 114 Taipei, Taiwan

²School of Medicine, National Defense Medical Center, 114 Taipei, Taiwan

³Taichung Armed Forces General Hospital, 411 Taichung, Taiwan

⁴Department of Biochemistry, National Defense Medical Center, 114 Taipei, Taiwan

*Correspondence: alfie0314@mail.ndmctsgh.edu.tw (Hsiang-Yu Yang); sung1500@mail.ndmctsgh.edu.tw (Chien-Sung Tsai)

Submitted: 15 December 2023 Revised: 21 January 2024 Accepted: 31 January 2024 Published: 7 August 2024

Abstract

Delayed surgical bleeding from the left internal mammary artery (LIMA) bed following coronary artery bypass grafting (CABG) is a rare yet potentially fatal condition that can lead to cardiac tamponade and life-threatening cardiogenic shock. We present a case of extremely delayed active bleeding from the LIMA bed, occurring 5 weeks after conventional CABG, resulting in cardiac tamponade and cardiogenic shock. The 73-year-old patient presented to the emergency room with a 2-day history of general weakness and hypotension. He had undergone CABG 5 weeks ago. Optimal inotropic agents and vasopressors were used for the treatment of shock. In the emergency room, real-time bedside echocardiography showed severe external compression of the right ventricle by a homogeneous, hyperechoic mass. Veno-arterial (V-A) mode extracorporeal membrane oxygenation (ECMO) was promptly instituted to stabilize hemodynamics. Subsequent chest re-exploration, involving blood clot evacuation, was performed, and the bleed from the distal LIMA bed was ligated. Delayed LIMA bed bleeding causing cardiac tamponade and cardiogenic shock is an infrequent occurrence, and the use of V-A mode ECMO successfully provided a window of time for chest exploration.

Keywords

delayed bleeding; coronary artery bypass grafting; extracorporeal membrane oxygenation

Background

Coronary artery bypass graft (CABG) surgery is a routine procedure in cardiovascular surgery for patients with coronary artery disease (CAD). Surgical bleeding may manifest at the cannulation site, anastomosis, and paraster-

nal wound, with associated risk factors encompassing emergency operations, lower body mass index, advanced age, and the use of anticoagulation [1,2]. However, delayed surgical bleeding from the left internal mammary artery (LIMA) bed following CABG is a very rare yet serious complication. In this case report, we present an instance of exceptionally delayed surgical bleeding originating from the distal LIMA graft bed. This event resulted in cardiac tamponade and subsequent cardiogenic shock, manifesting five weeks post-coronary artery bypass graft (CABG) surgery. Bedside real-time echocardiography and a computed tomography scan revealed a severe mass effect inducing right ventricular collapse. A chest re-exploration to investigate and address the bleeding, conducted under extracorporeal membrane oxygenation (ECMO) support, was undertaken. The patient was discharged without any further complications. The CARE checklist was used when writing this case report (**Supplementary Table 1**).

Case Presentation

The patient, a 73-year-old male, presented to the emergency room with a 2-day history of general weakness and hypotension. He has a medical history of hypertension and type 2 diabetes mellitus, both under medication control. 5 weeks before the emergency room (ER) presentation, the patient had undergone on-pump CABG surgery, involving the LIMA graft to the left anterior descending artery and saphenous vein grafts to the ramus intermedius branch and obtuse marginal branch. Ten days after the CABG operation, he encountered complications, including pneumonia and empyema, leading to sepsis and bed ridden during the post-coronary artery bypass graft (CABG) period. Thirty days after the CABG operation, he was discharged. Two days after discharge, he experienced general weakness and low blood pressure, leading to his admission to the emergency room due to worsening symptom.

Upon arrival at the emergency room, the patient exhibited a heart rate of 112 beats per minute, a respira-

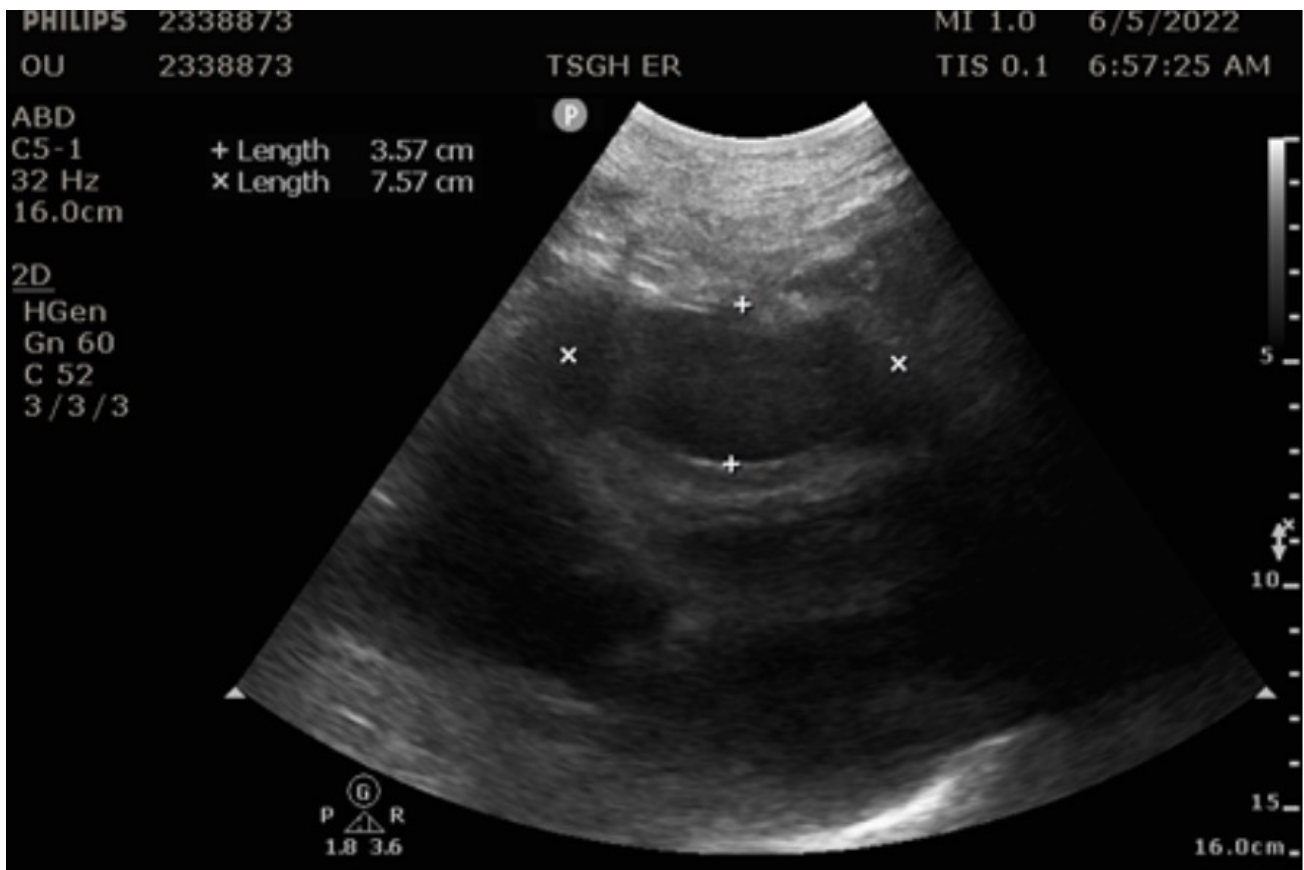

Fig. 1. Real-time echocardiography image. A hyperechoic, homogeneous mass measuring 3.5×7.5 cm was identified within the epicardial space, resulting in external compression of the right ventricle.

tory rate of 13 breaths per minute, and a blood pressure of 66/44 mmHg. The electrocardiography revealed atrial fibrillation, and the blood tests showed elevated creatine kinase and troponin and creatinine levels. Optimal inotropic agents, including norepinephrine and dopamine, were administered. Bedside real-time echocardiography and chest computed tomography revealed a huge mass lesion in the pericardial space with mass effect, compressing the right ventricle (Figs. 1,2), leading to cardiac tamponade and obstructive shock. Subsequently, Veno-arterial (V-A) mode ECMO was established to stabilize the patient, and the patient was promptly transferred to the operating room for chest re-exploration.

During re-sternotomy from the previous CABG wound, an active bleeder over the distal LIMA bed with pulsatile bleeding was identified (Fig. 3). A video showing LIMA bed bleeding was provided (**Supplementary data**). After suture ligation of the bleeder and addressing other bleeders, the sternum was closed with seven sternum wires, and the wound was closed layer by layer. The patient was then admitted to the intensive care unit for further monitoring. As the vital signs gradually stabilized, V-A ECMO was discontinued, and the patient was transferred to the general ward seven days later. Due to preoperative poor nutritional status and recurrent hospital-acquired pneumo-

nia, the patient remained hospitalized for a month, receiving medical treatment, including advanced antibiotics and nutritional support. Eventually, the patient was discharged in a relatively stable condition, and the follow-up echocardiography revealed preserved right ventricle (RV) and left ventricle (LV) contractility with subsided external hematoma (Fig. 4). Regular follow-up has been warranted to assess the pulmonary condition, exercise capacity and nutrition status.

Discussion

Postoperative bleeding following CABG can lead to severe consequences, often requiring surgical intervention. In a Japanese analysis, approximately 1.8% of patients undergoing isolated CABG necessitated reoperation due to bleeding [3]. Karthik *et al.* [4], reported 62.5% patients who needed re-exploration for checking bleeding were within 12 hours after first operation in their case series. Čanádiová *et al.* [5] showed a re-exploration after up to 7 days due to delayed cardiac tamponade with most of the re-exploration within 12 hours. Since the time to re-exploration was mostly with 12 hours in the cases series, delayed bleeding was considered as a more than 12 hours' time to re-exploration. Most of those patients with re-

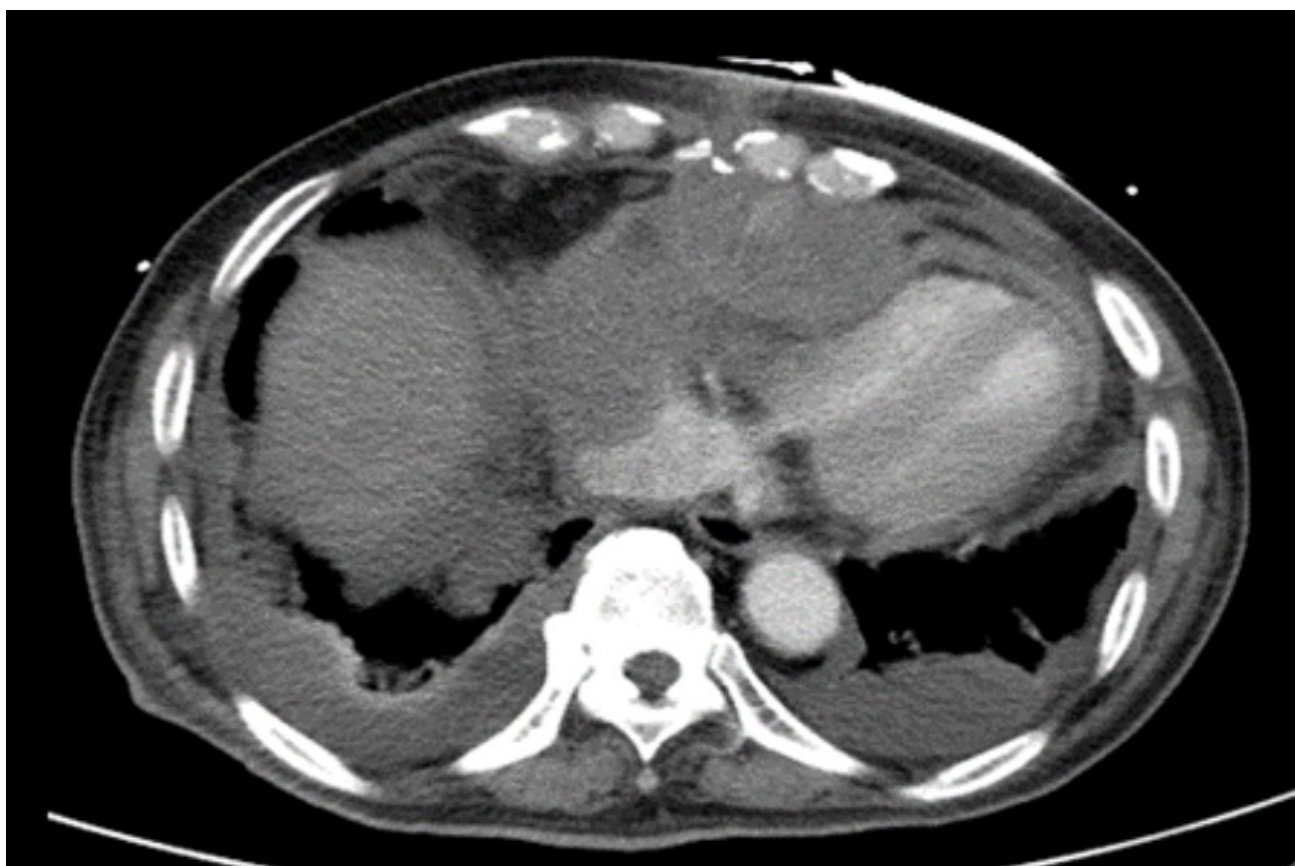

Fig. 2. Contrast-enhanced chest computed tomography image. A contrast-enhanced mass lesion was observed within the epicardial space, exhibiting a mass effect and causing compression of the right ventricle.

exploration for bleeding had an issue of anti-platelet agents used [6]. To the best of our knowledge, our case is the longest late surgical bleeding needed re-exploration, which was 5 weeks after CABG surgery. In the context of delayed bleeding, Tehrani *et al.* [7] presented a case of LIMA avulsion occurring four weeks after CABG surgery. In their case, the patient exhibited symptoms consistent with cardiac tamponade and cardiogenic shock [7]. In the context of preoperative antithrombotic strategy and its association with severe bleeding, adherence to current guidelines recommending the early discontinuation of P2Y12 receptor antagonists is crucial for reducing excessive bleeding and early mortality after CABG within the first 30 days [8]. When considering the use of aspirin post-CABG, a prospective study by Nouraei *et al.* [9] demonstrated that early administration of aspirin does not elevate the risk of post-operative bleeding following CABG. Pneumonia is the common complication of post-open heart surgery, which is related to multi-comorbidities, poor cardiac function, inadequate chest care and rehabilitation [10]. The patient presented with post-operative pneumonia and empyema, complicated with sepsis and poor nutrition status, which may affect the healing of sternal wound, leading to potential risk of bleeding. Furthermore, the nutritional status is a critical concern for patients undergoing CABG. Several studies

have shown a significant correlation between malnutrition and increased mortality as well as prolonged hospitalization duration [11]. Malnutrition also exerts detrimental effects on the cardiovascular, immunological, endocrine, gastrointestinal systems, and the healing process during the recovery phase [12]. The serum albumin level and lymphocyte count can serve as independent prognostic factors for patients with coronary artery disease undergoing coronary artery CABG [13]. Thus, potential risk factors contributing to delayed bleeding from the LIMA bed may include late discontinuation of anti-platelets agents, poor nutrition or sepsis related delayed sternal wound healing, and possibly exposure too much distal LIMA tail after ligation. Bed-side real-time echocardiography can offer immediate information for the differential diagnosis of shock in an emergency room setting [14]. The initiation of ECMO should be contemplated in instances of refractory cardiogenic shock to stabilize the patient, providing a window for decision-making and the pursuit of a comprehensive differential diagnosis [15]. Alternatively, sono-guided tube drainage of the bloody contain may temporarily relieve the obstruction of the RV. However, the drainage may not be adequate due to the already formed blood clot, rather than pure fluid, in the hematoma mass.

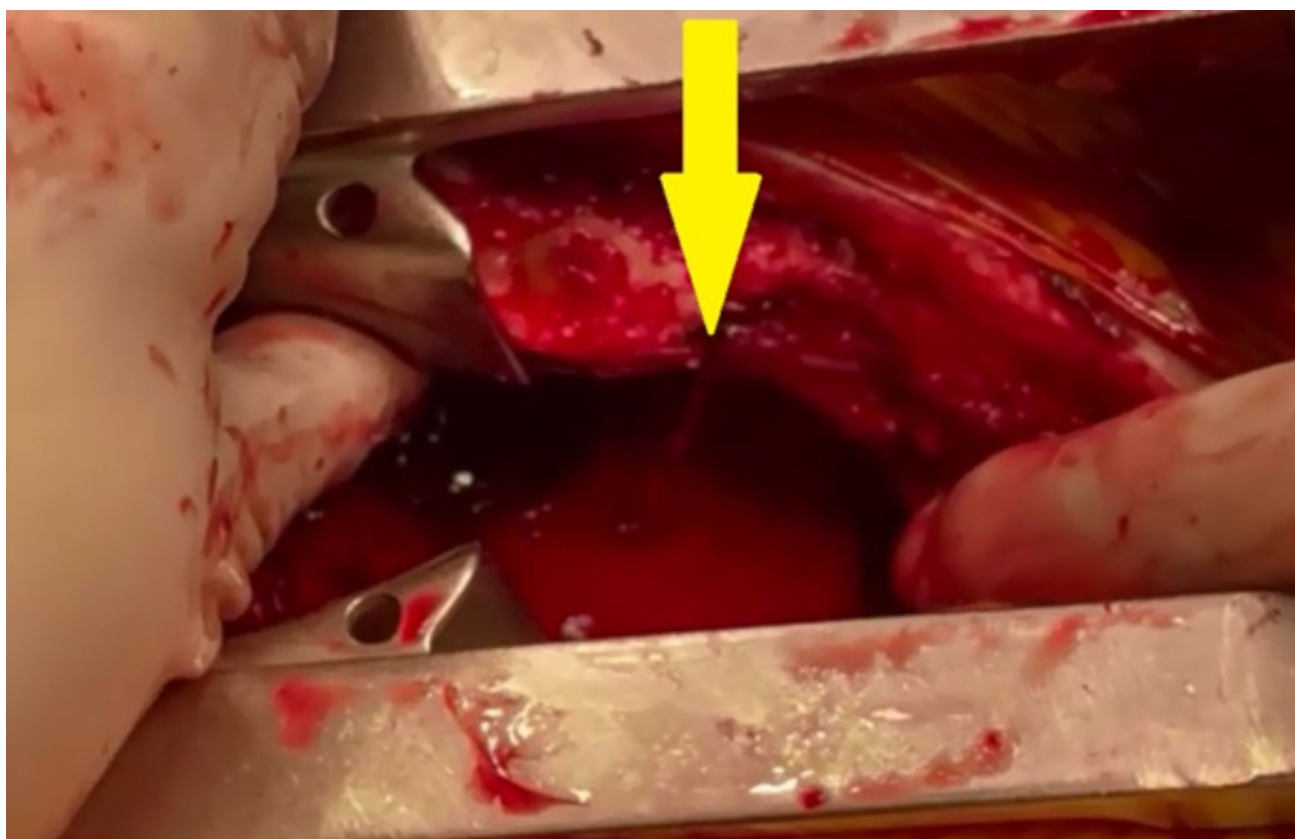


Fig. 3. Photograph of LIMA bed bleeding. An active bleeder was identified over the distal left internal mammary artery (LIMA) bed, exhibiting pulsatile bleeding. Yellow arrow indicates the active bleeding from LIMA bed.

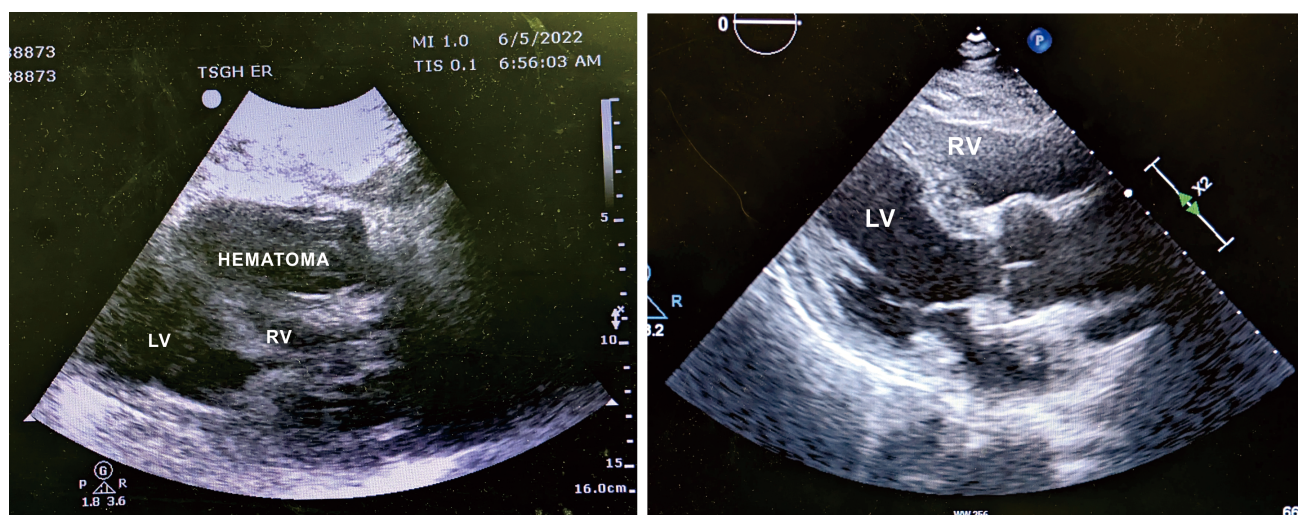


Fig. 4. Photograph of follow-up echocardiography image. Compared to preoperative echocardiography (Left), the hematoma was subsided with preserved right ventricle (RV) and left ventricle (LV) contractility showing in 1-year follow up echocardiography (Right).

Conclusion

Caring for patients who have undergone CABG is a crucial concern, and delayed surgical bleeding over the LIMA bed after CABG is a very rare complication. Both bedside echocardiography and chest computed tomography

scans are valuable tools for differential diagnosis when a patient presents with cardiogenic shock. V-A mode ECMO can be a life-saving strategy if profound shock develops, providing time for subsequent chest exploration for blood clot evacuation and checking for bleeders.

Author Contributions

WTK and HYY designed the research study. WTK and YTT performed the research. CYL and CST provided help and advice on the data. HYY drafted the manuscript. HYY approved the final version of manuscript. All authors contributed to editorial changes in the manuscript. All authors read and approved the final manuscript. All authors have participated sufficiently in the work and agreed to be accountable for all aspects of the work.

Ethics Approval and Consent to Participate

Informed consent was obtained from the patient for the purpose of publishing the case report and the case report was approved by the Institutional Review Board of the Tri-Service General Hospital (TSGHIRB No.: C202205163).

Acknowledgment

Not applicable.

Funding

This research received no external funding.

Conflict of Interest

The authors declare no conflict of interest.

Supplementary Material

Supplementary material associated with this article can be found, in the online version, at <https://doi.org/10.59958/hsf.7125>.

References

- [1] Hsu PS, Yang HY, Chen JL, Tsai YT, Lin CY, Ke HY, *et al.* The implication of seniority of supervising attending surgeon on the reexploration rate following elective coronary artery bypass grafting. *Journal of the Formosan Medical Association = Taiwan Yi Zhi.* 2019; 118: 354–361.
- [2] Mehta RH, Sheng S, O'Brien SM, Grover FL, Gammie JS, Ferguson TB, *et al.* Reoperation for bleeding in patients undergoing coronary artery bypass surgery: incidence, risk factors, time trends, and outcomes. *Circulation. Cardiovascular Quality and Outcomes.* 2009; 2: 583–590.
- [3] Miyata H, Tomotaki A, Motomura N, Takamoto S. Operative mortality and complication risk model for all major cardiovascular operations in Japan. *The Annals of Thoracic Surgery.* 2015; 99: 130–139.
- [4] Karthik S, Grayson AD, McCarron EE, Pullan DM, Desmond MJ. Reexploration for bleeding after coronary artery bypass surgery: risk factors, outcomes, and the effect of time delay. *The Annals of Thoracic Surgery.* 2004; 78: 527–34; discussion 534.
- [5] Čanádýová J, Zmeko D, Mokráček A. Re-exploration for bleeding or tamponade after cardiac operation. *Interactive Cardiovascular and Thoracic Surgery.* 2012; 14: 704–707.
- [6] Hansson EC, Jidéus L, Åberg B, Bjursten H, Dreifaldt M, Holmgren A, *et al.* Coronary artery bypass grafting-related bleeding complications in patients treated with ticagrelor or clopidogrel: a nationwide study. *European Heart Journal.* 2016; 37: 189–197.
- [7] Tehrani S, Rathore S. Successful percutaneous treatment of a catastrophic left internal mammary artery graft avulsion occurring 4 weeks post-coronary artery bypass grafting surgery: a case report. *European Heart Journal. Case Reports.* 2020; 5: ytaa524.
- [8] Biancari F, Mariscalco G, Gherli R, Reichart D, Onorati F, Fagian G, *et al.* Variation in preoperative antithrombotic strategy, severe bleeding, and use of blood products in coronary artery bypass grafting: results from the multicentre E-CABG registry. *European Heart Journal. Quality of Care & Clinical Outcomes.* 2018; 4: 246–257.
- [9] Nouraei SM, Gholipour Baradari A, Emami Zeydi A. Does Early Post-operative Administration of Aspirin Influence the Risk of Bleeding After Coronary Artery Bypass Graft Surgery? A Prospective Observational Study. *Medical Archives (Sarajevo, Bosnia and Herzegovina).* 2015; 69: 381–383.
- [10] Wang D, Huang X, Wang H, Le S, Yang H, Wang F, *et al.* Risk factors for postoperative pneumonia after cardiac surgery: a prediction model. *Journal of Thoracic Disease.* 2021; 13: 2351–2362.
- [11] Mubashir T, Balogh J, Breland E, Rumpel D, Waheed MA, Lai H, *et al.* Risk Factors and Outcomes of Protein-Calorie Malnutrition in Chronic Heart Failure Patients Undergoing Elective Cardiac Surgery. *Cureus.* 2022; 14: e30378.
- [12] Tasbulak O, Guler A, Duran M, Sahin A, Bulut U, Avci Y, *et al.* Association Between Nutritional Indices and Long-Term Outcomes in Patients Undergoing Isolated Coronary Artery Bypass Grafting. *Cureus.* 2021; 13: e16567.
- [13] Keskin M, İpek G, Aldağ M, Altay S, Hayiroğlu Mİ, Börklü EB, *et al.* Effect of nutritional status on mortality in patients undergoing coronary artery bypass grafting. *Nutrition (Burbank, Los Angeles County, Calif.).* 2018; 48: 82–86.
- [14] McLean AS. Echocardiography in shock management. *Critical Care (London, England).* 2016; 20: 275.
- [15] Combes A, Leprince P, Luyt CE, Bonnet N, Trouillet JL, Léger P, *et al.* Outcomes and long-term quality-of-life of patients supported by extracorporeal membrane oxygenation for refractory cardiogenic shock. *Critical Care Medicine.* 2008; 36: 1404–1411.