

Cardiac Tamponade due to Left Ventricular Pseudoaneurysm After Aortic Valve Replacement

Onur Baydar, MD,¹ Ugur Coşkun, MD,¹ Betül Balaban, MD,¹ Gurkan Cetin, MD,²
Inci Firatli, MD,¹ Murat Kazim Ersanli, MD,¹ Mehmet Serdar Kucukoglu, MD¹

Departments of ¹Cardiology and ²Cardiovascular Surgery, Istanbul University Institute of Cardiology,
Istanbul, Turkey

ABSTRACT

Left ventricular outflow tract pseudoaneurysm is a rare but a potentially lethal complication, mainly after aortic root endocarditis or surgery. Usually, it originates from a dehiscence in the mitral-aortic intervalvular fibrosa and arises posteriorly to the aortic root. We report a rare case of a patient with cardiac tamponade due to left ventricular pseudoaneurysm after aortic valve replacement. The subsequent surgical resection was performed successfully.

INTRODUCTION

Left ventricular outflow tract (LVOT) pseudoaneurysm is a rare but potentially lethal complication, mainly occurring with aortic root endocarditis, surgery, chest trauma, or congenital heart disease. Usually, it originates from a dehiscence in the mitral-aortic intervalvular fibrosa that arises posteriorly to the aortic root [Pongratz 1007; Bizzarri 2005; Gupta 2006]. Owing to these anatomic features, its assessment via imaging methods is challenging, and surgical repair requires complex procedures. We describe an unusual case of LVOT pseudoaneurysm. It was detected by transthoracic echocardiography 2 months after aortic root replacement for acute endocarditis. A multidetector computed tomography evaluation confirmed the presence of a pouch located between the aortic root and the left atrium.

CASE REPORT

In 2002, a 41-year-old woman was admitted to the hospital with fever, cough, and fatigue. The diagnosis was established as infective endocarditis caused by *Staphylococcus aureus*, and transthoracic echocardiography revealed a mass on the interventricular septum behind the aortic valve. After the treatment

for the infective endocarditis, the patient underwent aortic valve replacement (AVR) and resection of the vegetation found on the interventricular septum. Two months after the surgery, a pseudoaneurysm was detected by a routine transthoracic echocardiography control examination. We presented the patient with this result and offered her a reoperation, but she refused it. In July 2011, the patient came to our hospital with nausea, vomiting, fever, and atypical chest pain. She was admitted with a diagnosis of pericarditis. The examinations revealed the first heart sound as normal and the second heart sound as metallic. The heart rate was 128 beats/min, and sinus rhythm was detected in the electrocardiogram. The blood pressure was 90/60 mm Hg. Markers of inflammation were detected at high levels. The prothrombin time was at therapeutic levels. The results of other system and laboratory investigations were within the normal limits. A perivalvular pseudoaneurysm and minimal pericardial effusion was observed in a transthoracic echocardiography evaluation (Figures 1-3). Another thoracic computed tomographic angiography examination revealed a pseudoaneurysm (5.1 × 4.9 × 3.1 cm) associated with the LVOT (Figure 2). After that, ibuprofen and proton pump inhibitor treatments were ordered. The patient was again offered a reoperation, but she did not want to undergo it. After 2 weeks of treatment, she was discharged. One week after discharge, the patient was admitted to our hospital with cardiogenic shock; the diagnosis was cardiac tamponade. With this result, the patient immediately underwent a surgical resection of the pseudoaneurysm. The mechanical aortic valve was exposed and resected by aortotomy. The LVOT pseudoaneurysm was seen and reconstructed with a no. 24 Polythene graft (Perouse Medical, Ivry-le-Temple, France); later, AVR with a no. 21 Sorin Soprano biological prosthesis (Sorin, Milan, Italy) was performed. The patient's postoperative course was uneventful, and a control transthoracic echocardiography evaluation showed a good surgical repair (Figure 4). The patient was discharged on the sixth postoperative day. Currently, the patient is under follow-up without any problem.

DISCUSSION

Left ventricular pseudoaneurysm is defined as a partial cardiac rupture that is contained by the adherent pericardium or scar tissue. It leads to the formation of a false aneurysm that maintains communication with the left ventricular

Received July 10, 2012; received in revised form December 14, 2012; accepted December 20, 2012.

Correspondence: Onur Baydar, MD, Cardiologist, Instructor, Istanbul University Institute of Cardiology, Department of Cardiology, Haseki, Aksaray, 34350, Istanbul, Turkey; 90-538-790-4563; fax: 90-216-469-3796 (e-mail: dr.onurbaydar@hotmail.com).

Doppler Signal

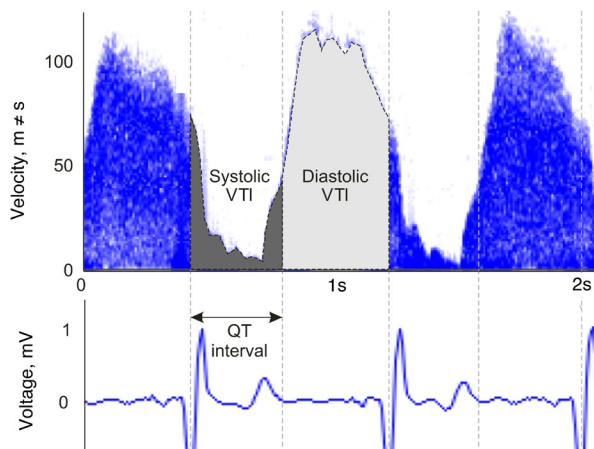


Figure 1. Transthoracic echocardiographic imaging of a perivalvular pseudoaneurysm and minimal pericardial effusion.

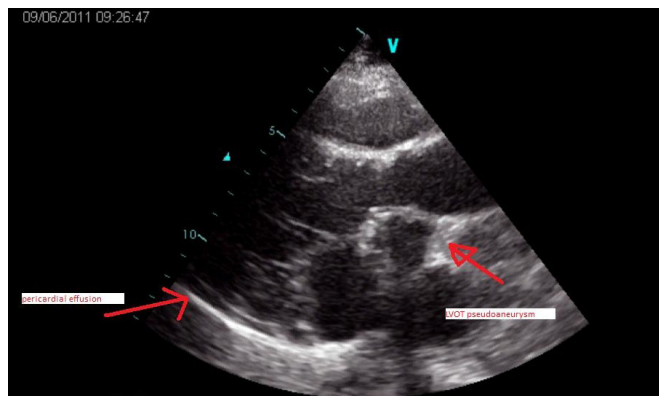


Figure 3. Transthoracic echocardiographic imaging of a perivalvular pseudoaneurysm and minimal pericardial effusion.

cavity. Left ventricular pseudoaneurysm is known to occur rarely as a serious complication after AVR. It differs from a true aneurysm, because the wall of a pseudoaneurysm consists of fibrous tissue and pericardium, not myocardium. The natural course of LVOT pseudoaneurysm is unclear. It is considered potentially fatal because of the risk of rupture into the pericardium, with the consequent cardiac tamponade, compression of the adjacent left main coronary artery, and mitral valve compression with severe regurgitation [Afridi 1995; Bizzarri 2005; Gupta 2006]. Therefore, prompt surgical resection is standard.

The development of pseudoaneurysm after AVR is attributed to the suturing technique [Barbeteas 1992; Kouchoukos 2003]. When a tight suture tears the LVOT wall, the high-velocity blood flow in the LVOT enters the tear and forms a pseudoaneurysm. If the tear is severe, suture dehiscence and paravalvular leakage can occur. The use of pledgets can avert loosened sutures and paravalvular leakage by dispersing the pressure and patching the suture tear [Stiles 1986]. The high

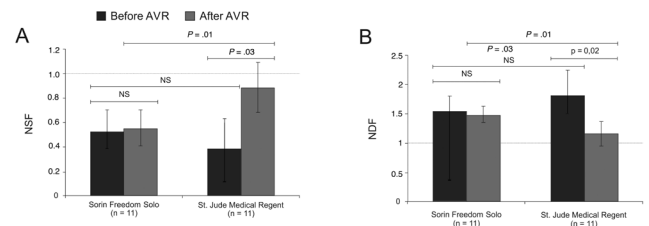


Figure 2. A perivalvular pseudoaneurysm and minimal pericardial effusion. Multidetector computed tomography image of perivalvular pseudoaneurysm.

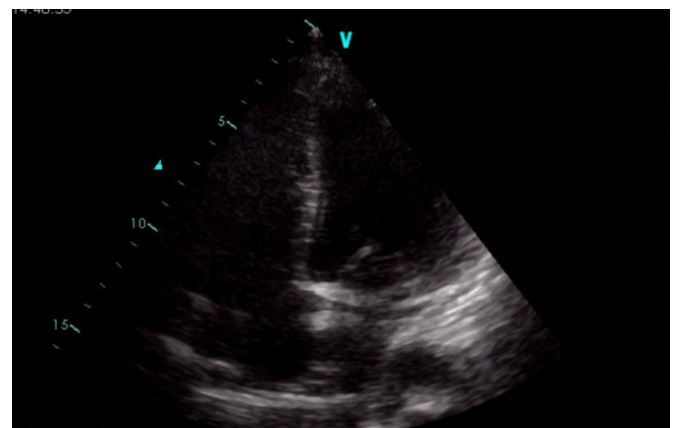


Figure 4. Transthoracic echocardiographic image after the surgical repair.

spatial resolution of multidetector computed tomography can clearly reveal the details of paravalvular structures without hindrance from acoustic shadowing or the limited acoustic window and spatial resolution of echocardiography. Even small and totally thrombotic pseudoaneurysms can be properly evaluated [Ghersin 2005].

In conclusion, although the majority of patients might be asymptomatic, LVOT pseudoaneurysm is a serious and rare complication after AVR. The recommended treatment is surgery, but this case shows that when pericardial effusion is detected in a patient with LVOT pseudoaneurysm, the risk of fatal complications increases greatly. Therefore, a patient with this condition must undergo operation urgently.

REFERENCES

- Afridi I, Apostolidou MA, Saad RM, Zoghbi WA. 1995. Pseudoaneurysm of the mitral-aortic intervalvular fibrosa: dynamic characterization using transesophageal echocardiographic and Doppler techniques. *J Am Coll Cardiol* 25:137-45.

- Barbetteas J, Crawford ES, Safi HJ, Coselli JS, Quinones MA, Zoghbi WA. 1992. Doppler echocardiographic evaluation of pseudoaneurysms complicating composite grafts of the ascending aorta. *Circulation* 85:212-22.
- Bizzarri F, Braconi L, Rossi A, Sorbara C, Stefano PL. 2005. Left ventricular outflow tract false aneurysm late after aortic valve replacement. *Heart Surg Forum* 8:136-9.
- Ghersin E, Litmanovich D, Agmon Y, Milo S. 2005. Pseudoaneurysm of the mitral-aortic intervalvular fibrosa following aortic valve replacement: diagnosis and dynamic evaluation with multidetector CT and transesophageal echocardiography. *Interact Cardiovasc Thorac Surg* 4:502-4.
- Gupta R, Jammula P, Huang MH, Atar S, Ahmad M. 2006. An unusual complication after aortic valve replacement. *J Clin Ultrasound* 34:361-4.
- Kouchoukos NT, Blackstone EH, Doty DB, Hanley FL, Karp RB. 2003. Aortic valve disease. In: Kirklin JW, Kouchoukos NT, eds. *Kirklin/Barratt-Boyes cardiac surgery: morphology, diagnostic criteria, natural history, techniques, results, and indications*. 3rd ed. Philadelphia: Churchill Livingstone. p 554-6.
- Pongratz G, Pohlmann M, Gehling G, Bachmann K. 1997. Pseudoaneurysm in the intervalvular mitral-aortic region after endocarditis and prosthetic aortic valve replacement. *Circulation* 96:3241-2.
- Stiles GM, Kernen JA, Stiles QR. 1986. Suture technique in preventing dehiscence of prosthetic mitral valves. *Arch Surg* 121:1136-40.