

Article

# Efficacy and Safety of Distal Radial Artery Approach for Coronary Angiography: A Retrospective Study

Jiaojiao Chen<sup>1,\*</sup>, Wenling Li<sup>1</sup>, Li Huang<sup>1</sup>, Lingjuan Zhou<sup>1</sup>

<sup>1</sup>Department of Cardiology, West China Hospital, Sichuan University/West China School of Nursing, Sichuan University, 610041 Chengdu, Sichuan, China

\*Correspondence: [lwl1232023@163.com](mailto:lwl1232023@163.com) (Jiaojiao Chen)

Submitted: 28 June 2023 Revised: 8 October 2023 Accepted: 13 October 2023 Published: 25 October 2023

## Abstract

**Background:** The distal radial artery approach has been employed as a potential alternative technique for coronary angiography. Nevertheless, its clinical implementation is significantly constrained by the narrow diameter of the radial artery. A comprehensive investigation of the efficacy and safety of the distal radial artery approach for coronary angiography is lacking. The objective of this study is to investigate the impact of the distal radial artery approach for coronary angiography and transradial artery access for interventional diagnosis and treatment. In addition, the effectiveness and safety of the distal radial artery approach for coronary artery angiography will be analyzed, for the wider adoption of this technique in clinical practice. **Methods:** A total of 68 patients with coronary heart disease (CHD) who underwent coronary catheterization via the left distal radial artery approach from December 2020 to December 2022 using the Distal radial artery approach (TRA) comprised the case-control study group. Seventy-three CHD patients who underwent routine left Transradial Artery Access coronary catheterization were selected as the Regular TRA group during the same period. Clinical data including age, body mass index (BMI), gender, CHD risk factors, routine drug treatment, ultrasonic-related indicators and operation-related indicators were collected from electronic medical records and the catheterization database from the two groups of patients. **Results:** The diameter and Endothelium-dependent vasodilation (noe FMD) of puncture vessels in the Distal TRA group were significantly lower than those in the Regular radial artery approach (TRA) group ( $p$ -value  $< 0.05$ ). After a period of 48 hours following the catheterization, the puncture vessel diameter and flow-mediated dilation (FMD) of the Distal TRA group were significantly lower compared to those of the Regular TRA group ( $p$ -value  $< 0.05$ ). The effectiveness of transradial artery access was then compared between the two groups. It was determined that the Distal TRA group exhibited significantly higher values in terms of the Visual Analog Scale (VAS) score, puncture time, and heparin usage, in comparison to the Regular TRA group ( $p$ -value  $< 0.05$ ). The occurrence rates of local hematoma, mediastinal hematoma, retroperitoneal hematoma, pseudoa-

neurysm, arteriovenous fistula, vagal reflex, vasospasm, blood transfusion, and other complications among patients in the Distal TRA group were comparable to those in the Regular TRA group ( $p$ -value  $> 0.05$ ). The incidence of puncture and X-ray radiation in the Distal TRA group was found to be marginally higher compared to the Regular TRA group. This study suggests that the safety profile of patients undergoing coronary artery catheterization via the distal radial artery is relatively higher than those undergoing the procedure via the transradial artery, although the difference was not statistically significant ( $p$ -value  $> 0.05$ ). **Conclusions:** The Distal radial artery approach can be used for conducting comprehensive coronary interventional diagnosis and treatment procedures, offering benefits such as reduced postoperative compression time, better hemostasis through the distal radial artery approach, and enhanced patient comfort. This approach demonstrates favorable efficacy and safety, making it a suitable routine puncture method for clinical treatment.

## Keywords

distal transradial artery access; coronary artery intubation; coronary intervention diagnosis and treatment; effectiveness; security

## Introduction

With the continuous development of new technology and instrumentation, the approach of coronary intervention has gradually transitioned from the femoral artery to the radial artery, and transradial artery access has become the preferred access site for coronary interventions [1]. Conventional transradial artery access can significantly reduce the incidence of vascular complications such as bleeding, but due to the relatively small diameter of the radial artery and the difficulty of puncture, its clinical application has certain limitations [2]. In elderly coronary heart disease (CHD) patients, the radial artery is narrow and tortuous, making it more difficult to perform conventional transradial artery access for coronary catheterization [3]. The increased rate of vascular occlusion limits the application of

conventional transradial artery access coronary intubation in hemodialysis, coronary artery bypass grafting and other procedures [4]. In China, more than 90% of coronary angiography is performed by conventional transradial artery access. However, hematoma and osteofascial compartment syndrome caused by conventional transradial artery results in increased complications such as false aneurysms [5]. With the continuous development of medical technology, super-slippery guide wires have been used to improve the success rate of transradial artery access for coronary catheterization [6].

The distal radial artery, the superficial palmar branch of the radial artery, has the advantage of reducing the incidence of arterial occlusion and represents a new approach in coronary interventional diagnosis and treatment [7]. Elderly patients have successfully undergone coronary catheterization through the distal radial artery approach. Studies have demonstrated that endovascular interventions through the distal radial artery approach are feasible for diagnosis and treatment [8]. Endovascular interventional diagnosis and treatment via the distal radial artery approach is still in the developmental stage in China, and there is insufficient experience with this technique coronary arteries interventions [9]. Therefore, we selected CHD patients for a retrospective case-control study to explore the effects of coronary artery access via the distal radial artery approach vs. conventional transradial artery access for diagnosis and treatment and to analyze its effectiveness and safety.

## Methods

### Research Object

The clinical characteristics and adverse events of CHD patients and other relevant information were extracted from the medical records and the angiography data of CHD patients was obtained from the hospital catheterization database. There were 68 CHD patients who received coronary artery access via the distal radial artery approach and 73 CHD patients who received conventional transradial artery access (Regular Distal radial artery approach (TRA) group). We collected and collated the patient's medical history information through the medical record archives and catheterization laboratory database, and obtained the approval of the West China Hospital of Medical Ethics Committee and the patient's informed consent. All patients' personal information was stored securely during the data analysis.

### Inclusion Criteria

(1) Only CHD patients with transradial artery access.  
(2) It is necessary to retain the catheter for continuous perfusion.

### Exclusion Criteria

(1) A positive Allen test or Barbeau test type D patients. (2) Patients with contraindications for coronary intervention, such as severe hepatic and renal failure and abnormal coagulation function, and patients with a previous coronary intervention through the left radial artery. (3) For patients with acute coronary syndrome requiring emergency surgery, preoperative ultrasound examination was performed to rule out forearm arterial malformations, severe calcification or occlusion. Coronary artery bypass surgery patients with a previous distal radial artery catheter were also excluded.

### Operation Methods

We selected patients with left transradial artery access because the left transradial artery access has a shorter distance to the visceral vessels than the right transradial artery access and does not need to pass through the brachiocephalic trunk. Site of coronary artery intubation: left conventional radial artery, 3 cm proximal to the radial styloid. The left distal radial artery, which is around the radial styloid process to the dorsal part of the hand.

Distal methods: The Distal TRA group were positioned flat on the operating table with the hand at rest position. Following local anesthesia with 2% lidocaine (Beijing Zeping medical company, Beijing, China) after routine disinfection and towel placement, the trocar was held in the left hand and slowly pierced the anterior wall of the blood vessel at an angle of 30–45°. After seeing blood return in the trocar, the catheter was pushed forward about 0.5 mm and pull out of the sheath. After adjusting the trocar position to see adequate blood return, the trocar was fixed to the right hand, he trocar was pulled out and the guide wire and inserted into the arterial sheath. 200 micrograms of nitroglycerin (Beijing Zeping medical company, Beijing, China) and 3000 units of heparin (Beijing Zeping medical company, Beijing, China) were given to prevent arterial spasm and clotting. Three adhesive bandages were used for adhesive fixation, and a sterile gauze was taken and folded in half three times. The midpoint of the folded gauze was placed on the puncture point, make the long axis of the gauze parallel to the radial artery, and then covered with 1–2 pieces of gauze, and the arterial sheath was pulled.

Traditional method: The puncture is usually performed at the proximal end of the transverse finger of the transverse palm stria (the strongest arterial pulsation). The specific puncture method is roughly the same as that of the distal radial artery puncture. The difference is that the conventional radial artery has relatively less bone structure. For coronary angiography, the use of nitroglycerin and heparin is the same, and for percutaneous coronary intervention, heparin should be supplemented to 100 U/kg, and heparin should be supplemented to 2000 units every 1 hour.

**Table 1. Comparison of general data between the two groups ( $\bar{x} \pm s$ ).**

Item	Distal TRA group (68)	Regular TRA group (73)	$t/\chi^2$	$p$ -value
Age (years)	63.16 $\pm$ 5.17	64.15 $\pm$ 5.18	-1.135	0.258
BMI (kg/m <sup>2</sup> )	29.13 $\pm$ 3.21	29.13 $\pm$ 3.25	0.000	1.000
Gender			2.479	0.115
Male (n)	36	32		
Female (n)	32	41		
Coronary heart disease risk factors			1.333	0.513
Diabetes (n)	20	21		
Dyslipidemia (n)	25	33		
Other factors (n)	23	19		
LVEF (%)	62.21 $\pm$ 3.81	61.97 $\pm$ 3.78	0.375	0.708
Hemoglobin (g/L)	124.25 $\pm$ 13.58	123.95 $\pm$ 13.18	0.133	0.894
Serum creatinine ( $\mu$ mol/L)	68.70 $\pm$ 9.13	69.08 $\pm$ 9.25	-0.245	0.807
Preoperative medication			5.852	0.054
Aspirin (n)	22	23		
Clopidogrel/Ticagrelor (n)	21	35		
Other Drugs (n)	25	15		

BMI, body mass index; LVEF, left ventricular ejection fraction; TRA, Distal radial artery approach.

### Statistical Methods

Data was assessed using SPSS 26.0 statistical software (IBM Corp., Armonk, NY, USA). Variables between groups were compared using the  $\chi^2$  or Fisher's exact test comparison between groups, orderly variables by using rank and inspection. The measurement data were represented by mean  $\pm$  standard deviation, and independent sample  $t$  test was applied when the patient's age, body mass index (BMI), CHD risk factors, preoperative routine drug treatment, relevant indicators of ultrasound examination and surgical indicators followed normal distribution. A  $p$ -value  $<$  0.05 was considered statistically significant.

## Results

### Comparison of Clinical Characteristics of Patients

Age, BMI, male, coronary heart disease risk factors, left ventricular ejection fraction (LVEF), hemoglobin, serum creatinine and preoperative medication were comparable between the two groups ( $p$ -value  $>$  0.05). See Table 1.

### Comparison of Ultrasound Examination

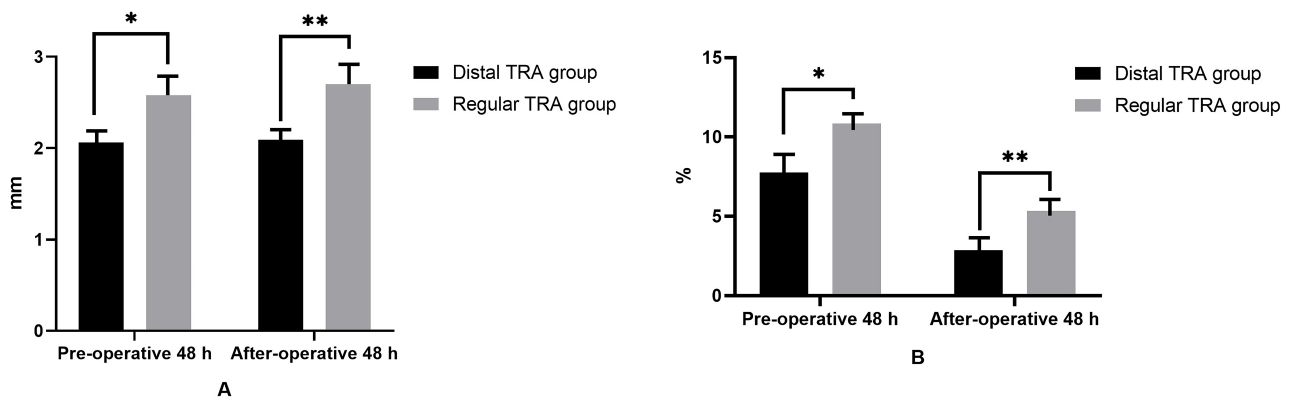
The diameter of puncture vessels and endothelium-dependent flow-mediated vasodilation (FMD) were compared between the two groups. The diameter and FMD of puncture vessels in Pre-operative 48 h, Distal TRA group were significantly lower than those in Regular TRA group ( $p$ -value  $<$  0.05). After operative 48 h, puncture vessel diameter and FMD of Distal TRA group were significantly lower than those of Regular TRA group ( $p$ -value  $<$  0.05). See Fig. 1.

### Comparison of Transradial Artery Access Effectiveness

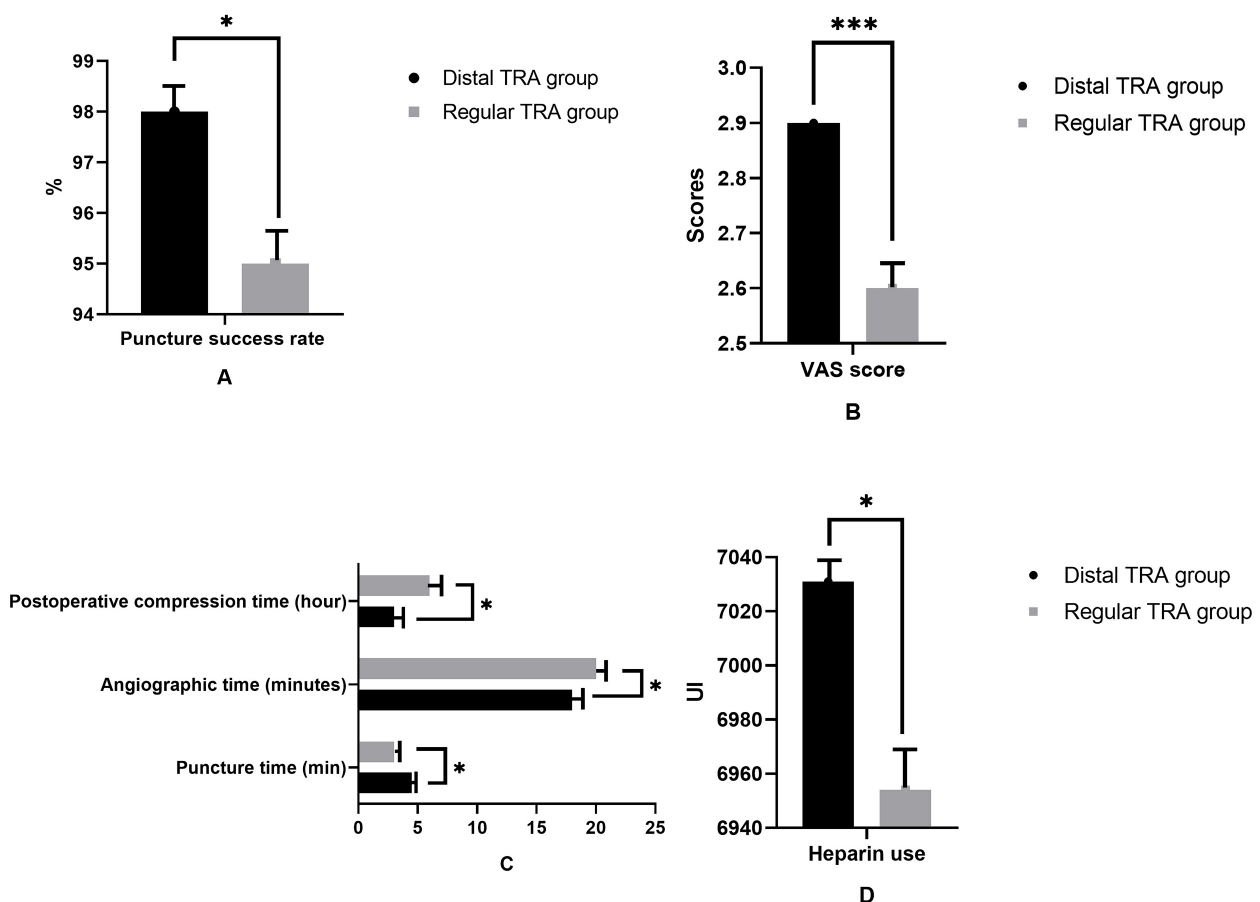
A comparison of the effectiveness of transradial artery access between the two groups found that the puncture success rate and postoperative compression time of patients in the Distal TRA group were comparable to those of Regular TRA group, with no statistical significance ( $p$ -value  $>$  0.05). The amount of the Visual Analog Scale (VAS) score, puncture time and heparin used in Distal TRA group was significantly higher than that in Regular TRA group ( $p$ -value  $<$  0.05). See Fig. 2.

### Transradial Artery Access Safety Comparison

We compared the safety of coronary intubation via distal radial artery approach versus conventional transradial artery access by comparing the complications, the number of punctures and the amount of X-ray radiation in the two groups. The incidence of complications such as local hematoma, mediastinal hematoma, retroperitoneal hematoma, pseudoaneurysm, arteriovenous fistula, vagus reflex, vasospasm and blood transfusion in the Distal TRA group was lower than that of Regular TRA group, and the difference was statistically significant ( $p$ -value  $<$  0.05). The number of punctures and amount of X-ray radiation in Distal TRA group was significantly lower than those in Regular TRA group. This indicates that the safety of patients with coronary artery intubation through distal radial artery approach is higher than that of patients with transradial artery access coronary artery intubation. The difference was statistically significant ( $p$ -value  $<$  0.05). See Fig. 3.



**Fig. 1. Comparison of ultrasonic detection parameters.** (A) The comparison of diameter of puncture vessels. (B) The comparison of endothelium-dependent flow-mediated vasodilation. Note: \* means  $p$ -value  $< 0.05$  at 48 h Pre-operative; \*\* After operative 48 h  $p$ -value  $< 0.05$ . TRA, Distal radial artery approach.

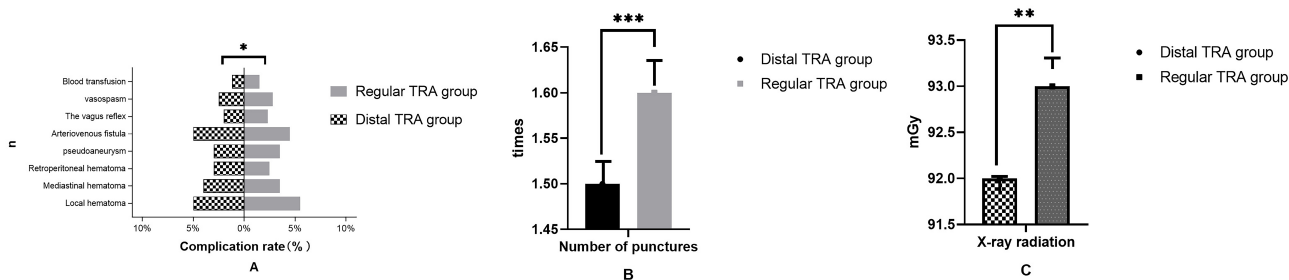


**Fig. 2. Comparison of transradial artery access effectiveness.** (A) The comparison of puncture success rate. (B) The comparison of VAS score. (C) The comparison of puncture time. (D) The comparison of heparin use. Note: \* means  $p$ -value  $< 0.001$ ; \*\*\* means  $p$ -value  $< 0.05$ . VAS, Visual Analog Scale.

## Discussion

Our study found that coronary intubation via the distal radial artery approach can be used to perform all coronary

interventions diagnosis, with the advantage of shorter post-operative compression time, convenient arterial compression for hemostasis, and improved patient comfort. Coronary artery intubation via the distal radial artery approach has good efficacy and safety. The absence of major blood



**Fig. 3. Comparison of transradial artery access safety between the two groups.** (A) The complications of puncture success rate. (B) The comparison of number of punctures. (C) The comparison of X-ray radiation. Note: \* means  $p$ -value  $> 0.05$ ; \*\* means  $p$ -value  $< 0.05$ ; \*\*\* means  $p$ -value  $< 0.001$ .

vessels and nerves around the distal radial artery approach significantly reduces bleeding complications and vascular and nerve injury, and has a low incidence of postoperative local complications at the puncture site [10,11]. The dual radial artery blood supply minimizes hand ischemia, is convenient for hemostasis, and does not affect the use of anticoagulant drugs [12]. Coronary artery intubation via distal radial artery approach reduces the occurrence of complications such as pulmonary embolism and increases the safety of interventional therapy [13].

Our study found that the diameter of the punctured vessels and FMD of the Distal TRA group was significantly lower than those of the Regular TRA group, indicating that the diameter of radial artery is closely related to the incidence of intraoperative vasospasm and postoperative radial artery occlusion. Endothelium-dependent flow-mediated vasodilation (FMD) reflects the induced response of vascular endothelium to shear stress, and is a non-invasive method to evaluate vascular endothelial function. Currently, it is more commonly used to evaluate the effect of coronary interventions on radial endothelial function. The puncture vessel diameter and FMD of patients in the distal TRA group were significantly lower than those in the conventional TRA group, indicating that coronary interventions had long-term adverse effects on the endothelial function and relaxation function of the radial artery, which contributes to radial artery occlusion. Most of the vascular complications related to the puncture site are related to the mismatch between the artery diameter and the sheath. When the ratio of the artery diameter to the sheath is greater than 1.0, it indicates that intubation is safe [14]. Blind intubation without measuring artery diameter may be associated with a higher risk of arterial injury [15]. Our study found that patients with artery diameter smaller than the sheath had obvious resistance during the placement of the sheath, pushing the guide wire and sending the guide catheter, and patients felt obvious discomfort during removal of the catheter [16]. The reason for this occurrence may be that the abundant alpha-adrenergic receptors in the outer vascular membrane of the artery make the radial artery prone to have higher vascular reactivity, which contributes to tem-

porary and sudden vascular narrowing after local trauma [17]. Therefore, prevention of radial spasm is crucial to reduce complications and improve patient comfort, and can be prevented by sedation and analgesia before surgery, reduction of puncture times, use of an ultra-thin hydrophilic sheath, and adequate anticoagulants and vasodilators after implantation of the arterial sheath [18]. All of our patients were safely implanted with a 6 F arterial sheath and successfully completed the operation. The vascular diameter of the distal radial artery and conventional radial artery was slightly dilated in the short term after the operation, which may be related to the short-term release of vascular endothelial cells with more vasodilator factors, vascular intimal injury, and local inflammation resulting in vascular dilation. The mechanism needs to be further studied and verified.

Our study demonstrated the effectiveness and safety of coronary artery intubation via distal radial artery approach. The technique of coronary intubation via distal radial artery approach is the key to the success of transradial coronary angiography [19]. During left coronary angiography, the super slippery guide wire was first inserted into the bottom of the aortic sinus so that the front end of the guide wire rolled up along the lateral wall of the left coronary sinus, and then the angiography catheter was pushed to the bottom of the sinus [20]. The technique included making the catheter head end naturally towards the left lateral wall of the ascending aorta, then withdrawing the guide wire, determining the opening position of the left coronary artery under fluoroscopy, and slowly pushing, lifting, and the slightly rotating the catheter head end into the left coronary artery opening [21]. The distance from the tip to the first bend of Terumo common type catheters is slightly longer than that of other common types of catheters, and the torsion control is good [22]. FMD reflects the induced response of vascular endothelial to shear stress and is a non-invasive method to evaluate vascular endothelial function. Currently, it is more commonly used to evaluate the impact of coronary intervention on radial endothelial function [23]. In recent years, FMD is also effective in predicting radial spasm and relieving puncture induced radial spasm, which is an important reference value in the selection of the

vascular approach, sheath size and use of anti-clonic drugs before interventional diagnosis and treatment [24]. In our study, FMD in the distal radial artery group all decreased in the short term after catheterization, which was mainly attributed to the mismatch between the diameter of the radial artery and the arterial sheath, the excessive number of intraoperative catheter exchanges, and the sustained ischemia and hypoxia of local vascular endothelium resulting in impaired vascular endothelial function due to the prolonged procedure [25]. Therefore, we use ultrasound before the procedure to assess the presence of distal radial artery malformations, measure artery diameter or ultrasound guided puncture, and increase operator training to improve puncture success and procedural success.

Our study has some limitations. It is observational, non-randomized study. In clinical practice, the interlocutor route is not randomly assigned, but is selected by the physician, so this selection bias will affect the comparison between the radial artery group and the femoral artery group.

## Conclusions

In summary, coronary artery intubation via the distal radial artery approach has similar efficacy to conventional transradial artery access, with advantages of short postoperative compression time, convenient hemostasis by arterial compression, improved patient comfort, and has good effectiveness and safety.

## Availability of Data and Materials

The data can be provided on reasonable request to the corresponding author.

## Author Contributions

JC and WL conducted study design and wrote the manuscript. JC and WL contributed to revise the manuscript. LH and LZ conducted the data analysis. All authors contributed to editorial changes in the manuscript. All authors read and approved the final manuscript. All authors have participated sufficiently in the work to take public responsibility for appropriate portions of the content and agreed to be accountable for all aspects of the work in ensuring that questions related to its accuracy or integrity.

## Ethics Approval and Consent to Participate

We collected and collated the patient's medical history information through the medical record archives and catheterization laboratory database, and have obtained the

approval of Medical Ethics Committee of West China Hospital (20201011) and the patient's informed consent. All patients' personal information is stored securely and hidden during data analysis.

## Acknowledgment

Not applicable.

## Funding

This research received no external funding.

## Conflict of Interest

The authors declare no conflict of interest.

## References

- [1] Lucreziotti S, Persampieri S, Gentile D, Barbieri L, Salerno-Uriarte D, Valli F, *et al.* Access-site hematoma in distal and conventional transradial access: a randomized trial. *Minerva Cardiology and Angiology.* 2022; 70: 129–137.
- [2] Ruzsa Z, Csavajda Á, Nemes B, Deák M, Sótonyi P, Bertrand OF, *et al.* Distal Radial Artery Access for Superficial Femoral Artery Interventions. *Journal of Endovascular Therapy: an Official Journal of the International Society of Endovascular Specialists.* 2021; 28: 255–261.
- [3] Li F, Shi GW, Zhang BF, Yu XL, Huang HM, Xiao JQ, *et al.* Recanalization of the occluded radial artery via distal transradial access in the anatomic snuffbox. *BMC Cardiovascular Disorders.* 2021; 21: 67.
- [4] Hadjivassiliou A, Cardarelli-Leite L, Jalal S, Chung J, Liu D, Ho S, *et al.* Left Distal Transradial Access (ldTRA): A Comparative Assessment of Conventional and Distal Radial Artery Size. *Cardiovascular and Interventional Radiology.* 2020; 43: 850–857.
- [5] Oliveira MDP, Caixeta A. Distal Transradial Access (dTRA) for Coronary Angiography and Interventions: A Quality Improvement Step Forward? *The Journal of Invasive Cardiology.* 2020; 32: E238–E239.
- [6] Rahman N, Ullah I, Farhad A, Adnan G. Distal transradial artery access for coronary angiography in a patient having rheumatoid arthritis-related severe arthropathies. *BMJ Case Reports.* 2021; 14: e245251.
- [7] Horák D, Bernat I, Jirouš Š, Slezák D, Rokyta R. Distal radial access and postprocedural ultrasound evaluation of proximal and distal radial artery. *Cardiovascular Intervention and Therapeutics.* 2022; 37: 710–716.
- [8] Rigatelli G, Zuin M, Daggubati R, Vassilev D, Zuliani G, Nguyen T, *et al.* Distal snuffbox versus conventional radial artery access: An updated systematic review and meta-analysis. *The Journal of Vascular Access.* 2022; 23: 653–659.
- [9] Hoffman H, Jalal MS, Masoud HE, Pons RB, Rodriguez Caamaño I, Khandelwal P, *et al.* Distal Transradial Access for Diagnostic Cerebral Angiography and Neurointervention: Systematic Review and Meta-analysis. *AJNR. American Journal of Neuroradiology.* 2021; 42: 888–895.
- [10] Golamari R, Gilchrist IC. Collateral Circulation Testing of the

- Hand- Is it Relevant Now? A Narrative Review. *The American Journal of the Medical Sciences*. 2021; 361: 702–710.
- [11] Li SS, Li JM, Liu LL, Liu W, Yang H, Feng CG. Analysis of the Risk Factors Related to the Success Rate of Distal Transradial Artery Access in Patients with Coronary Heart Disease. *Risk Management and Healthcare Policy*. 2022; 15: 657–663.
- [12] Yamazaki K, Hanaoka Y, Koyama JI, Yamazaki D, Fujii Y, Ogiwara T, *et al*. Contralateral Transradial Access for Coil Embolization of Distal Anterior Cerebral Artery Aneurysm Associated With a Steep Ipsilateral A1-A2 Angle. *Journal of Stroke and Cerebrovascular Diseases: the Official Journal of National Stroke Association*. 2022; 31: 106299.
- [13] Valgimigli M, Landi A. Distal Transradial Access for Coronary Procedures: Old Certainties, Novel Challenges, and Future Horizons. *JACC. Cardiovascular Interventions*. 2022; 15: 33–38.
- [14] Tsigkas G, Apostolos A, Davlouros P. Less Is More, But Not Always: Distal Transradial Access for Radial Artery Occlusion Prevention. *JACC. Cardiovascular Interventions*. 2022; 15: 1202–1204.
- [15] Eid-Lidt G, Rivera Rodríguez A, Jimenez Castellanos J, Farjat Pasos JI, Estrada López KE, Gaspar J. Distal Radial Artery Approach to Prevent Radial Artery Occlusion Trial. *JACC. Cardiovascular Interventions*. 2021; 14: 378–385.
- [16] Cao G, Cai HX, Cao J. Advancement in Coronary Angiography or Percutaneous Coronary Intervention Using the Distal Transradial Artery Access in Acute Coronary Syndrome and Complex Coronary Artery Disease. *Anatolian Journal of Cardiology*. 2022; 26: 163–171.
- [17] Rodríguez Caamaño I, Barranco-Pons R, Klass D, de Dios Las Cuevas M, Chirife OS, Aixut S. Distal Transradial Artery Access for Neuroangiography and Neurointerventions: Pitfalls and Exploring the Boundaries. *Clinical Neuroradiology*. 2022; 32: 427–434.
- [18] Watanabe S, Usui M. Distal transradial artery access for vascular access intervention. *The Journal of Vascular Access*. 2022; 23: 157–161.
- [19] Wang Y, Liu Z, Wu Y, Li Z, Wang Y, Wang S, *et al*. Early prevention of radial artery occlusion *via* distal transradial access for primary percutaneous coronary intervention. *Frontiers in Cardiovascular Medicine*. 2022; 9: 1071575.
- [20] Eesa M, Mitha AP, Lewkonja P. Distal transradial access for targeted spinal angiography and embolization. *Interventional Neuroradiology: Journal of Peritherapeutic Neuroradiology, Surgical Procedures and Related Neurosciences*. 2023; 29: 498–503.
- [21] Al-Azizi KM, Grewal V, Gobeil K, Maqsood K, Haider A, Mohani A, *et al*. The Left Distal Transradial Artery Access for Coronary Angiography and Intervention: A US Experience. *Cardiovascular Revascularization Medicine: Including Molecular Interventions*. 2019; 20: 786–789.
- [22] Gitto M, Brizzi S, Cozzi O, Gohar A, Maurina M, Spada P, *et al*. Radial Artery Pseudoaneurysm Complicating Distal Transradial Access for Chronic Total Occlusion Recanalization. *Cardiovascular Revascularization Medicine: Including Molecular Interventions*. 2022; 40S: 279–281.
- [23] Tu L, Jin Y, Li S, Yu Q, Lu Y. Distal transradial access decreases radial artery occlusion rate in percutaneous coronary interventions. *American Journal of Translational Research*. 2023; 15: 2802–2810.
- [24] Hamandi M, Saad M, Hasan R, Megaly M, Abbott JD, Dib C, *et al*. Distal Versus Conventional Transradial Artery Access for Coronary Angiography and Intervention: A Meta-Analysis. *Cardiovascular Revascularization Medicine: Including Molecular Interventions*. 2020; 21: 1209–1213.
- [25] Fu Y, Zuo K, Yang Y, Gao Y, Liu L, Ding X, *et al*. Distal Transradial Access: a Safe and Feasible Approach for Coronary Catheterization in Cases of Total Radial Artery Occlusion. *Journal of Cardiovascular Translational Research*. 2022; 15: 1203–1211.