

Article

# Starting Pediatric VAD Program: Transforming Challenges into Opportunities; A Case Series of a Single Center

Matija Bakoš<sup>1,\*</sup>, Milivoj Novak<sup>1</sup>, Dalibor Šarić<sup>1</sup>, Dorotea Bartoniček<sup>1</sup>, Dražen Belina<sup>2</sup>, Željko Đurić<sup>2</sup>, Darko Anić<sup>2,3</sup>, Željko Čolak<sup>3,4</sup>, Sanja Konosić<sup>3,4</sup>, Marina Mihalec<sup>1</sup>, Filip Rubić<sup>1,3</sup>, Toni Matic<sup>1,3</sup>, Goran Međimurec<sup>2</sup>, Mislav Planinc<sup>2</sup>

<sup>1</sup>Department of Pediatrics, University Hospital Centre Zagreb, 10000 Zagreb, Croatia

<sup>2</sup>Department of Cardiac Surgery, University Hospital Centre Zagreb, 10000 Zagreb, Croatia

<sup>3</sup>University of Zagreb, School of Medicine, 10000 Zagreb, Croatia

<sup>4</sup>Department of Anesthesiology, University Hospital Centre Zagreb, 10000 Zagreb, Croatia

\*Correspondence: [mbakos11@gmail.com](mailto:mbakos11@gmail.com) (Matija Bakoš)

Submitted: 20 February 2023 Revised: 7 May 2023 Accepted: 14 June 2023 Published: 9 August 2023

## Abstract

**Background:** The prevalence of heart failure is constantly increasing in both children and adults. End-stage heart failure in children unresponsive to medical therapy has limited treatment options. Surgical options include heart transplantation or implantation of durable ventricular assist devices (VADs). To start the VAD program, it was necessary to train core team members, invite experienced proctors and adjust the organizational approach. **Methods:** We present our first seven pediatric patients who underwent a VAD implantation with primary indication end-stage dilated cardiomyopathy. **Results:** The median age on implant was four and a half years and the median duration of VAD support was 39 days with long term survival achieved in three patients. The causes of death were multiorgan failure, thromboembolic events, sepsis, and low cardiac output syndrome. Ischemic stroke was the reason for successful neurointervention during VAD support in two patients. **Conclusions:** To establish a VAD program, numerous specialties must be included with adequate training and learning for all team members.

## Keywords

ventricular assist device; children; cardiomyopathy; thromboembolic events; case series

## Introduction

From the first ventricular assist device (VAD) support implantation done by DeBakey in 1971 [1], 20 years have passed to a successful use of VADs in children. Adult-sized “Berlin Heart” VAD as a bridge to heart transplantation (BTT) was implanted to an 8 years-old boy with end-stage heart failure [2]. Soon thereafter the mechanical circulatory support (MCS) devices for smaller patients with a body weight less than 30 kg were developed [3]. The main

difference between VADs is based on flow used for providing cardiac output: long-term pulsatile flow VAD devices (EXCOR® Berlin Heart GmbH, Berlin, Germany) or short-term continuous flow VAD devices (HeartWare® HVAD System, Framingham, MA, USA; HeartMate, Abbot, Abbott Park, IL, USA; Infant Jarvik 2015, Jarvik Heart Inc., New York, NY, USA) [4]. The VAD support in children is used as a BTT – over a half of cases, bridge to myocardial recovery (BTR) or bridge to decision (BTD) [3,5]. The major postoperative concerns and issues in VAD patients is anticoagulation management, bleeding or thrombosis of the pump with neurological events as a consequence. There are three main protocols for anticoagulation management of children on VAD support: (1) the Edmonton Anticoagulation and Platelet Inhibition Protocol [3,6,7], (2) the Stanford protocol [6,8], and (3) Direct Thrombin Inhibitor (DTI) Harmonization protocol [6,8,9].

The following paper presents a single tertiary center experience in management and the obstacles of starting the pediatric VAD program in Croatia.

## Materials and Methods

Our study is a retrospective review from September 2016 to September 2021 of all children who underwent VAD implantation at University Hospital Centre Zagreb in Zagreb, Croatia. The clinical outcomes were collected prospectively. The summary of the patient’s data is shown in Table 1. The study was approved by the University Hospital Centre Zagreb Institutional Review Board (02/21 AG).

## Choosing the Ventricular Assist Device

In seven of our patients different VAD systems were used: a paracorporeal Berlin Heart EXCOR (Berlin Heart AG, Berlin, Germany), axial HeartWare Ventricular Assist System (Medtronic, Framingham, MA, USA) and magnetically levitated centrifugal Levitronix Centrimag (Abbott Laboratories, Abbott Park, IL, USA). The Berlin Heart EX-

COR was our preferred device for smaller patients (body surface area (BSA) <1.3 m<sup>2</sup>). The compressor-operated polyurethane pump varies in size from 10 to 80 milliliters (mL) [10]. Depending on the patients' body weight, 15 mL and 25 mL pumps were used. The decision for biventricular or left ventricular support only, although discussed before surgery, was finally made in the operating theatre. Along this, the HeartWare Ventricular Assist System was used only once, in an adolescent patient.

### *Surgical Implementation of the Ventricular Assist Device System*

The chest was opened via median sternotomy and prior to heparin administration left ventricular assist device (LVAD) cannulas were tunneled. After routine aortic and bi-caval venous cannulation a vent catheter was placed to decompress the heart, usually in the right upper pulmonary vein. After completion of heart mobilization, implantation of VAD cannulas began with the insertion of the LVAD inflow cannula, which was placed in the left ventricular apex on the beating or arrested heart. After coring the apex and checking for any residual thrombus formations in the left ventricle, a series of horizontal mattress monofilament sutures were brought transmurally from outside to inside on the ventricular wall, and then up through the flange on the apical cannula. The cannula was positioned in the left ventricle and sutures were tied. Proximal part of the graft was then sewn to the aorta with monofilament sutures and cross-clamp was released after meticulous deairing with no air bubbles to be observed on transesophageal echocardiography [11,12].

### *Anticoagulation Management*

In our patients with implanted Berlin Heart EXCOR, anticoagulation was started and managed according to The Edmonton Anticoagulation and Platelet Inhibition Protocol. The intravenous infusion of 10 international units per kilogram per hour (IU/kg/h) of unfractionated heparin for 24 hours or more after surgery was started. Its effect was monitored using activated partial thromboplastin time (aPTT) with the aim of maintaining around 50–60 seconds. For quick check-up of the heparin therapeutic effect, usually when dose of heparin was significantly lowered or increased, the activated clotting time (ACT) was used with a target value of 180–220 seconds. Antithrombin III levels were monitored twice daily and replaced if the value was below 75%. A switch to low molecular weight heparin (LMWH) was done after 48 hours. Anti-Xa was measured twice weekly with a target value of 0.3–0.5 U/mL. Depending on the Edmonton protocol dipyridamole, acetylsalicylic acid (ASA) and warfarin (target international normalized ratio (INR) level 2.7–3.5) were commenced. In one patient bivalirudin was also initiated.

### *Statistical Analysis*

Data were summarized as count and are presented in Table 1. Quantitative variables were expressed using median and interquartile range (IQR) values. Qualitative variables were expressed in the form of numbers and percentages. Due to the small sample size, statistical analysis was not performed.

### *Results*

Between September 2016 and September 2021, a total of 7 children underwent VAD support in our center. The summary of the patient's data is shown in Table 1. The study included three boys (patients 3, 6, and 7) and four girls (patients 1, 2, 4, and 5) with a median age at VAD implantation of four and a half years. Overall, three children (43%) survived (patients 2, 3 and 5) the support period and all of them were bridged (BTT) to orthotopic modified bicaval heart transplantation. In one child the indication for VAD support was intractable arrhythmia (patient 1), in five of them cardiomyopathy with two being diagnosed with restrictive (restrictive cardiomyopathy (RCM)) (patients 3 and 4), two with dilative ((dilative cardiomyopathy (DCM)) (patients 5 and 6) and one DCM with elements of non-compaction (patient 2). In one patient the VAD support was inserted due to postcardiotomy failure and extracorporeal membrane oxygenation (ECMO) treatment (patient 7). In the first patient in 2016 (patient 1), a 9-year-old girl, the indication for MCS was made after the diagnosis of dilated cardiomyopathy was confirmed, resistant arrhythmia occurred, and veno-arterial ECMO (V-A ECMO) initiated. In total, three different types of MCS have been exchanged during the treatment. The total VAD support (extracorporeal and intracorporeal) lasted for 79 days. In the second patient, the indication for MCS support was made after 6 months of conventional treatment of end-stage heart failure due to DCM with elements of non-compaction. Third patient presented initially with cardiac arrest after a work-out (patient 3). After the successful resuscitation, 21 days of ECMO and 58 days of VAD support, the BTT was performed as the ultimate modality of treatment. A thorough work-up revealed restrictive cardiomyopathy caused by autosomal dominant mutation of cardiac troponin I (*TNNI 3* gene).

The median duration of VAD support in our group was 39 days (1–124 days). The longest support of 124 days was implemented in a two-and-a-half-year-old girl (patient 4) born with RCM and a complicated clinical course. Due to cardiocirculatory failure, the central V-A ECMO was initiated. After 19 days of ECMO support, the implantation of Berlin Heart EXCOR support for the left ventricle was performed using a 15 mL pump. Despite efforts and although on Edmonton protocol, severe hematological complications on VAD support occurred: the patient first suffered acute

**Table 1. The summary of patients' data.**

Variables	Patient 1	Patient 2	Patient 3	Patient 4	Patient 5	Patient 6	Patient 7	Overall
Sex	F	F	M	F	F	M	M	
Diagnosis	DCM/myocarditis/ Intractable arrhythmia	DCM with elements of non- compaction	RCM	RCM	DCM	DCM	Supravalvular aortic stenosis, Williams-Beuren syndrome	
Age at VAD implantation (years and months)	9 y and 5 m	4 y and 5 m	14 y and 2 m	2 y and 6 m	11 y and 1 m	2 y and 5 m	3 y and 7 m	Median: 4 y and 5 m (IQR 2 y and 6 m–11 y and 1 m)
Weight at VAD implantation (kg)	37	13	57	10.4	24.9	8.3	15	Median: 15 kg (IQR 10.4–37)
BSA at VAD implantation (m <sup>2</sup> )	1.20	0.75	1.63	0.5	0.94	0.43	0.65	Median: 0.75 (IQR 0.5–1.2)
V-A ECMO run before LVAD	yes	no	yes	yes	yes	yes	yes	Yes/No (%) 6 (86%)/1 (14%)
Duration of ECMO (d)	5		21	19	37	8	12	Median: 15.5 (IQR 8–21)
Type of pump (LVAD, BiVAD)	LVAD	LVAD	LVAD	LVAD	LVAD	BiVAD	BiVAD	LVAD/BiVAD (%) 5 (71%)/2 (29%)
Type of pump flow (pulsatile/continuous)	Continuous	Pulsatile	Continuous	Pulsatile	Continuous	Pulsatile	Pulsatile	Pulsatile/Continuous (%) 4 (57%)/3 (43%)
Type of pump	Centrimag levitronix HeartWare intracorporeal	EXCOR Berlin Heart	Rotaflow Maquet Centrifugal pump with oxygenator	EXCOR Berlin Heart	Centrimag levitronix	EXCOR Berlin Heart	EXCOR Berlin Heart	
Size of implanted pump (mL)		25		15		15	15	
Anticoagulation management	Edmonton protocol	Edmonton protocol	Edmonton protocol	Edmonton and Stanford	Edmonton protocol	Edmonton protocol	Edmonton protocol	
Post-implantation complications								
Intracranial bleeding/ishemic stroke	yes	no	no	yes	yes	NA	NA	Yes/No/NA (%) 3 (4%)/2 (28.5%)/2 (28.5%)
Infection	yes	no	no	no	yes	no	yes	Yes/No (%) 3 (43%)/4 (57%)

Table 1. Continued.

Variables	Patient 1	Patient 2	Patient 3	Patient 4	Patient 5	Patient 6	Patient 7	Overall
Other	Acute and chronic surgical bleeding + tamponade	Perioperative bleeding	Perioperative bleeding		Pneumothorax, bleeding	Disfunction of RV		
Hemodialysis	yes	no	yes	yes	no	no	yes	Yes/No (%) 4 (57%)/3 (43%)
System exchange	yes, 2 times	no	no	no	yes, 1 time	no	no	Yes/No (%) 2 (29%)/5 (71%)
Duration of LVAD support (d)	15 days extracorporeal 64 days intracorporeal	1	58	124	39	1	10	Median: 39 (IQR 1–79)
Outcome	Dead	Alive/HTX	Alive/HTX	Dead	Alive/HTX	Dead	Dead	
Reason for death	Septic shock			Multiorgan failure		Postsurgical, LCOS	Multiorgan failure	
Neurological outcome (PCPC Score)		normal	normal		permanent vegetative state			

F, female; M, male; DCM, dilative cardiomyopathy; RCM, restrictive cardiomyopathy; VAD, ventricular assist device; y, years; m, months; kg, kilogram; BSA, body surface area; m<sup>2</sup>, square meter; ECMO, extracorporeal membrane oxygenation; d, day; LVAD, left ventricular assist device; BiVAD, Biventricular assist device; mL, milliliter; NA, not applicable; HTX, heart transplantation; LCOS, low cardiac output syndrome; PCPC, Pediatric Cerebral Performance Category; IQR, interquartile range; V-A ECMO, veno-arterial ECMO.

thrombosis of the right middle cerebral artery which clinically manifested as acute onset of left sided hemiplegia. Neuroradiological thrombectomy procedure was successfully done on the same day while she was still on mechanical support (Fig. 1). About a month later, the patient suffered intracerebral hemorrhage with progression into ventricles which prompted external ventricular drainage. The patient's neurological status suggested a poor neurological outcome. During re-evaluation of anticoagulation and her nutrient and caloric intake, it was discovered that the girl was receiving turmeric in her dietary regimen given from parents during visits. From the point of discontinuation of turmeric intake, coagulation parameters started to change in a more predictable manner, according to the doses of warfarin given. The patient continuously deteriorated neurologically, couldn't be weaned from mechanical respiratory support, and gradually developed further cardiocirculatory instability due to septic shock. The resulting multi-organ failure was the reason for the lethal outcome. Neuroradiological thrombectomy procedure was also successfully performed on an 11-year-old patient (patient 5) with DCM in whom the VAD support started due to cardiogenic shock restrictive to therapy (Fig. 2).

The shortest time of VAD support was one day and was observed in two patients with different outcomes. A four-and-a-half-year-old female patient (patient 2) underwent orthotopic modified heart transplantation the day after the VAD system was implanted and in a two-and-a-half-year-old male patient (patient 6) in which the LVAD implantation was complicated with the early onset acute right heart failure which prompted addition of right ventricular support thus becoming biventricular assist device (BiVAD), but despite this patient succumbed to treatment. In the last patient (patient 7), the indication was made after postcardiotomy failure developed after supra-aortic stenosis repair. Patient was supported with central V-A ECMO for 12 days. Of seven patients, in six of them (86%) the ECMO run preceded VAD implantation, with median duration of ECMO support before use of VAD system of 15 and a half days.

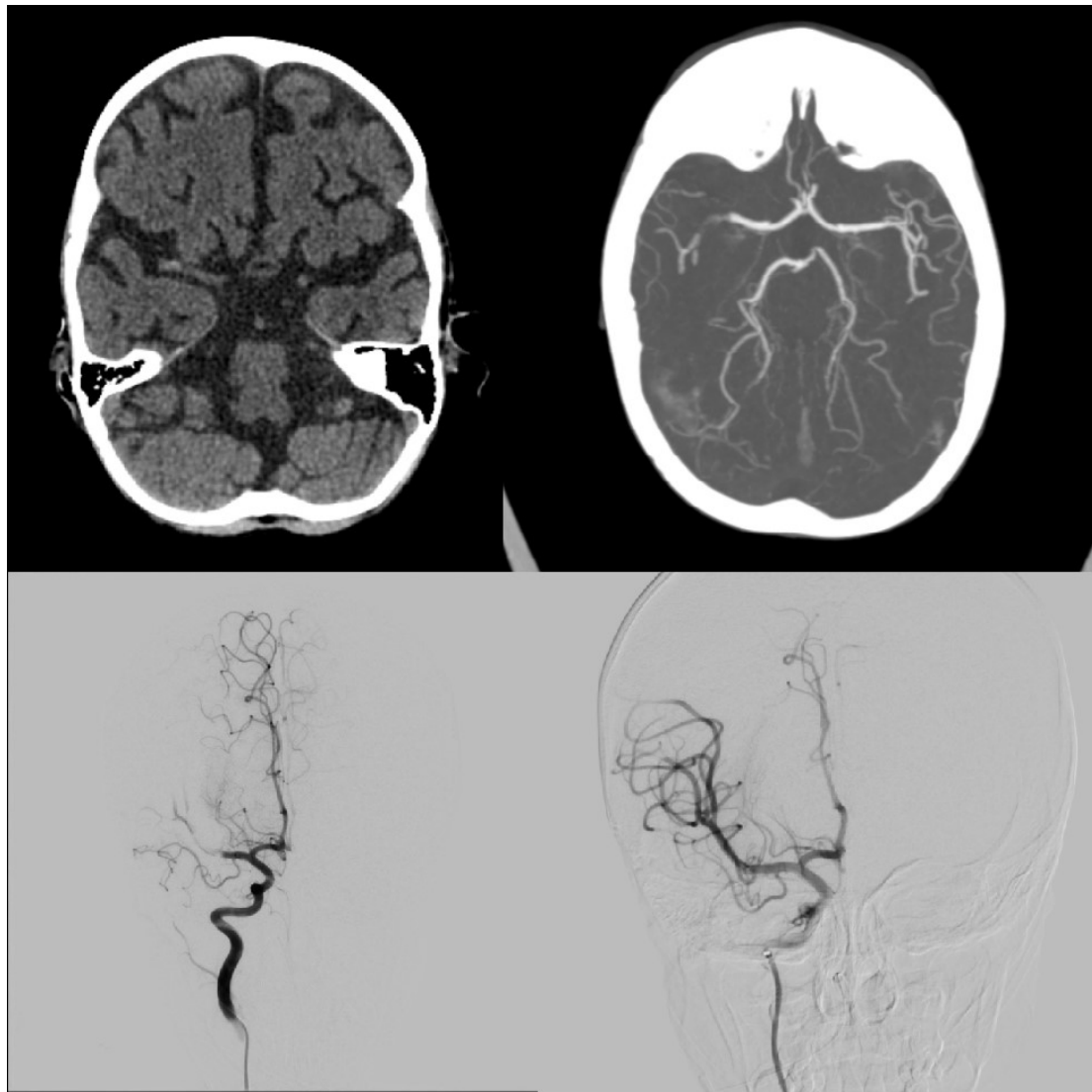
During the postoperative management, several adverse events occurred mostly including hematological complications: thromboembolic events and hemorrhage. Embolic or ischemic cerebrovascular events occurred in a total of 3 patients. The hemorrhage occurred in four patients (57%). Hemodialysis was performed in 4 patients; one of them is still alive, without neurological sequelae. In one of the patients (patient 5), supported by the Centrimag Levitronix system (Abbott Laboratories, Abbott Park, IL, USA), due to a system thrombosis the exchange of the system was deemed to be necessary and fibrin threads were found on the device (Fig. 3).

The neurological outcome of the children who survived VAD support was assessed by Pediatric Cerebral Performance Category Scale (PCPC). Two of the children belong to group 1 (patients 2 and 3), and one female patient in group 5 (patient 5).

## Discussion

Starting the VAD program in our institution brought upon many issues: patient selection, decision making, and hematologic challenges being most important. In end-stage heart failure there are three possible treatment options. Firstly, heart transplantation, with a disadvantage of insufficient number of donor organs and longer waiting times for allocation. In the modern era, more than a third of pediatric heart transplants are performed on VAD support [13]. Second and third options are BTT and BTR, respectively, using ECMO or MCS, which dramatically changed the heart failure management. Before the introduction of VADs in children, the use of ECMO provided only short-term MCS. After 10–20 days of ECMO use, the incidence of serious complications is increasing significantly and huge progress was made in 1990 when the first case of an 8-year-old boy treated with adult size VAD was published [2]. This device was approved in Europe in 1992 and in Canada and USA in late 2011 [14]. The first use of VAD support in children in Croatia was done in 2016 in our institution. From that point, a total of seven short or long term MCS implants have been done in our center. The survival rate of 42% is below some of the registries [15], but still about equal to other studies [5,12,16–18]. Considering that one child is in a permanent vegetative state, treatment success can only be said for 2/7 patients (29%). The explanation for the high mortality could be delayed implantation, inexperience of our team and struggling anticoagulation management. In majority of patients, the VAD started after ECMO support, which is also a common practice in other centres [19]. However, 86% of ECMO runs preceding VAD support is much higher than published elsewhere [19]. The lack of practical experience with MCS is the probable reason for delayed initiation of this treatment modality as well as for using a different VAD strategy, such as paracorporeal continuous flow pumps and pulsatile systems. In one of three surviving patients, the cardiocirculatory support before a BTT lasted for only 24 hours due to availability of donor organs. The median duration of VAD support was 39 days, which is much shorter than in other published studies [16,18,20]. Probable explanation lies in fact that our cohort is small, and that in two patients the VAD support lasted for 1 day (patients 2 and 6), and in one patient for 10 days (patient 7). Schweiger *et al.* [21] published a study about outcome of biventricular VAD support in 10 children after using HeartWare VAD. Overall survival was 6 out of 10, among which 5 were transplanted with one awaiting HT, and none have recovered [21]. A larger study reported by O'Connor *et al.* [22], included 35 patients with median age of 15.7 years (range 8.8–47.3 years) included also adult population [22]. Outcomes were excellent, with only 1 undesired outcome [22]. Another study, including only small children (<10 kg) was published by Woods and colleagues [23]. They presented outcomes of 5 children who underwent total artificial



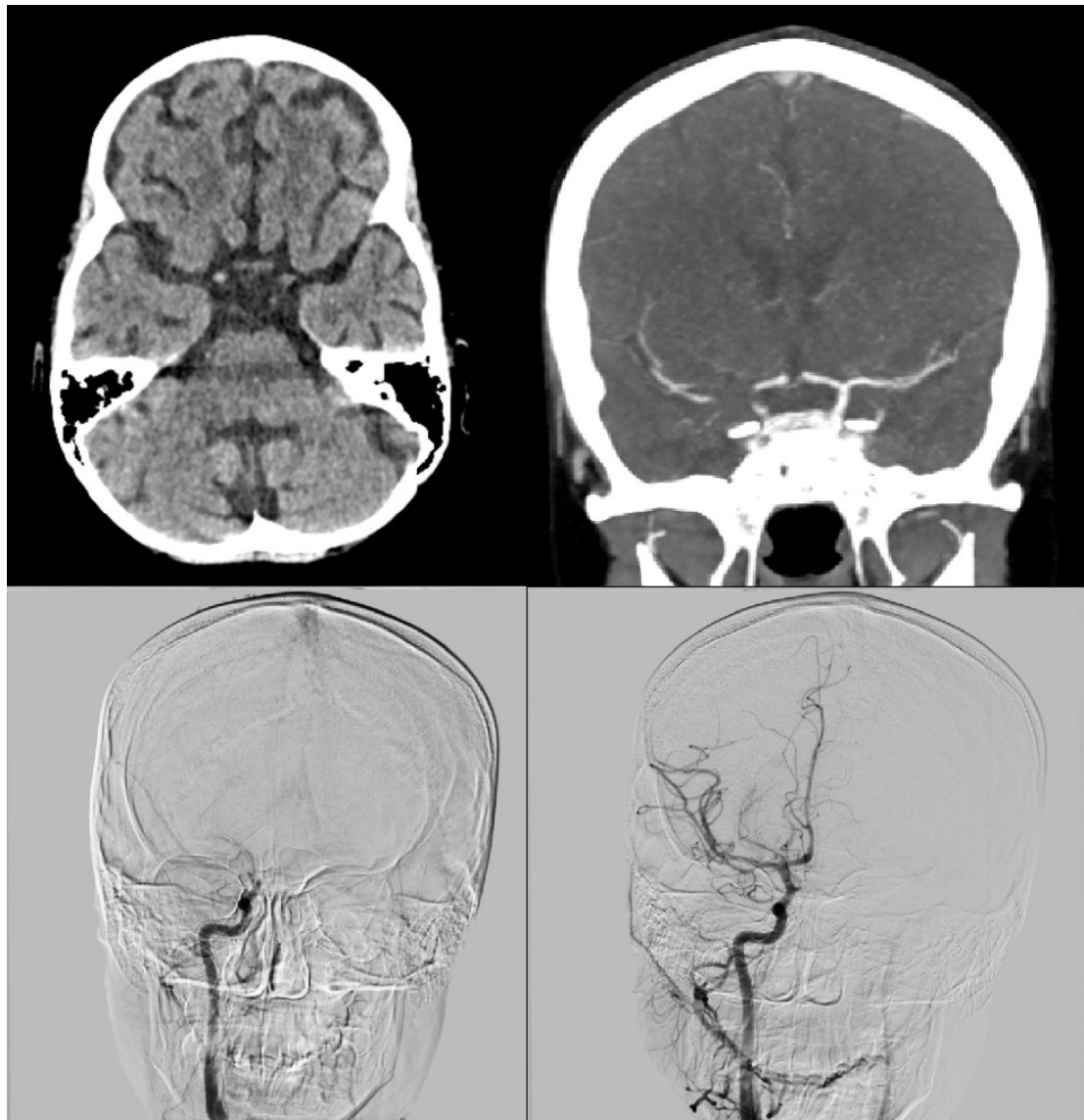


**Fig. 1. Mechanical thrombectomy procedure during ventricular assist device (VAD) support.** Upper left: native computed tomography (CT) scan of the brain; Upper right: CT angiography of the brain; Lower part: before and after mechanical thrombectomy of the right middle cerebral artery.

heart support, and three patients survived to transplantation and discharge. Two of them had single ventricle circulation. The management principles were the same as with biventricular VAD support [23]. In our cohort, no single ventricle patient was treated with VAD support. Anticoagulation management of this study because of patient age and weight, was of particular interest for our team. They initiated anticoagulation after resolution of surgical bleeding (about 12 to 24 hours postoperatively), and then started with an argatroban infusion to reach aPTT time 2–3 times above baseline level. Also, in patients with EXCOR pumps, both antiplatelet agents (aspirin and clopidogrel) were used [23].

The major concern observed during the medical course was anticoagulation management with both hemorrhagic and thromboembolic events. Both the Edmonton and Stanford protocols were considered in the treatment of spe-

cific coagulation issues which were observed in three of seven (43%) patients. The pulsatile flow devices, unlike continuous flow devices, seem to bring a higher thrombotic rate [24]. The high stroke rate in patients with pulsatile Berlin EXCOR support is caused mostly by thrombus formation on the valves of the device [25]. Opposite, continuous flow have programmed pump speeds with washouts to avoid thrombosis, still, there are reports of thrombosis on continuous-flow devices which is believed to be created on the rotors of its pump due to elevated shear stress [24,26]. Depending on 5th Pediatric Interagency Registry for Mechanical Circulatory Support (PEDIMACS) report paracorporeal continuous flow devices, unlike pulsatile devices, seem to bring a higher risk for non-gastrointestinal bleeding, while the incidence of gastrointestinal bleeding, infection, and neurologic dysfunction and both hemorrhagic and ischemic stroke is approximately equal [15]. In our case



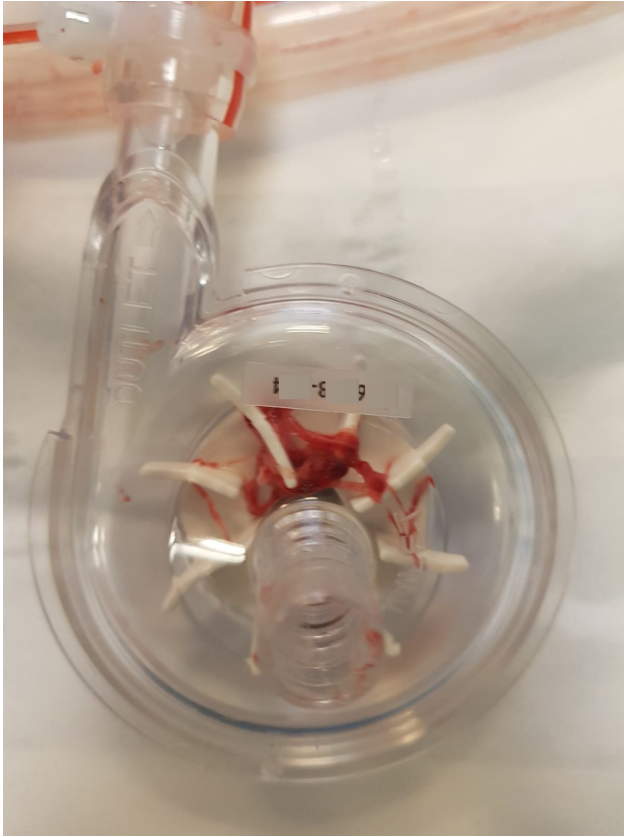**Fig. 2. Mechanical thrombectomy procedure during VAD support.** Upper left: native computed tomography (CT) scan of the brain; Upper right: CT angiography of the brain; Lower part: before and after mechanical thrombectomy of the right internal carotid artery.

series, in three patients the continuous flow VAD support was implanted (patients 1, 3 and 5), and in four patients the pulsatile Berlin Heart EXCOR system was used (patients 2, 4, 6 and 7). According to the Extracorporeal Life Support Organization (ELSO) registry, the prevalence of hemorrhagic complication in the pediatric MCS population is 39% [27]. In the recent Pedimacs registry report, the incidence of hemorrhagic stroke was 11% [8,15]. The study published by Fraser *et al.* [28] showed that serious adverse events including major bleeding (42–50%), infections (50–63%) and stroke (29%) occurred in the majority of study participants. In the same study it was presented that the incidence of stroke has decreased over the last few years with the adoption of multiple interventions mainly including steroids [29,30] and adoption of DTI for primary anticoagulation [8,31]. The treatment of ischemic stroke in pediatric patients supported with VADs is not commonly

published in the literature. However, the stroke has been addressed as the single most feared complication associated with use of the Berlin Heart EXCOR VAD [29]. Major progress in its treatment was made after the introduction of mechanical thrombectomy [32]. Making the diagnosis of ischemic stroke in children on VAD support could be difficult and the diagnosis should be confirmed only by doing consecutive computed tomography (CT) scans, which can reveal the exact area of ischemia [33]. Administration of recombinant tissue-plasminogen activator is not an option due to a recent cardiac surgery and anticoagulation management [28,33,34]. Two of our patients developed significant clinical manifestations of intracranial events. The literature referring to endovascular treatment of acute ischemic stroke in children is rare, and only few reports are published on VAD support [34]. Wilson *et al.* [35] published a population - based study of endovascular therapy in pedi-

**Table 2. Lesson learned after starting pediatric VAD program.**

Issues	Solutions
Ischemic stroke	Early neurointervention
Coagulation issues	Detailed control of nutrition
Time of implementation	Starting and doing the program under supervision



**Fig. 3. Fibrin threads found on the device.**

atric stroke and demonstrated that it is a very rare procedure (<1%), with a population of the patients tended to be older (>10 years). A review of mechanical thrombectomy in the general pediatric population published by Satti *et al.* [36] described a high recanalization rates and good clinical outcome, with the limitation of the study of small number of patients (n = 29). This population of children supported by the VAD system is a new population, and strict guidelines are still missing. Opposite, the aim is reducing the risk of stroke by better understanding and management of coagulation issues [29]. In patient 4, significant oscillations of coagulation parameters, mainly INR, was caused by dietary turmeric intake. Curcumin, a polyphenol responsible for the yellow color of turmeric, has anticoagulation properties [37].

In a recent publication on advances in MCS in critically ill children [38], authors stated that the crucial point in the decision-making process is an agreement on timely implementation and type of device for support, which is mainly dependent on circulatory or respiratory failure, on

acute or chronic type of disease and on anticipated time for recovery [38]. They also stated that in management of those patients, crucial point remains anticoagulation due to high risk for cerebrovascular injuries (both embolic stroke and intracranial bleeding) [38]. Still, no consensus on the optimal mode and range of the anticoagulation of these patients has been made [39].

Starting the VAD program brought many expected and unexpected issues (Table 2). The treatment problems started with the late decision on starting VAD support, with all the patients being the Interagency Registry for Mechanically Assisted Circulatory Support (INTERMACS) level 1 at initiation (critical cardiogenic shock). We were particularly concerned with anticoagulant and antithrombotic management. This therapy protocol varies constantly and, despite guidelines, should be modified individually. Lack of experience and delay in decisions resulted in unfavored outcomes. A network for discussion of therapy decisions is missing but is improving due to communication with experienced proctors. Although the learning curve is steep, the level of training of the whole team: surgeons, cardiologists, intensivists, and health care providers are not optimal due to the low number of cases. It can be improved by education in highly experienced centers, which is not only our wish but our need.

Issues in the postoperative management have arisen due to coagulation problems, thrombosis, and bleeding. Special attention should be paid to nutrition and food supplements due to possible significant interaction with coumarin agents. When the signs of thrombotic strokes are observed, an emergent neurointervention should be considered regardless of the low number of published data on the real long-term benefit of this procedure. Anticipating high mortality rate and adverse events, lack of training and experience and exploration of these questions can reverse initial experiences.

### Limitation of the Study

This study has some important limitations. It presents a single-center experience with a small sample size, which is understandable as there are not many indications for VAD support in children. Moreover, in two patients the use of VAD lasted for only one day. There are inconsistencies in patient profiles. As the number of patients is limited, the number of events is also small meaning that there are several factors affecting the outcome which cannot be included



in multivariable analysis. Furthermore, the variety of techniques were used with no indication that one technique was preferred. Secondly, all the data are retrospective spanning 6 years (2016–2021), except for neurological assessment of children who survived. Neurological assessment is based upon a simple scoring system. Using retrospective data, the absence of some data in a patient's history can be an important confounder.

## Conclusions

Mechanical circulatory support of the heart represents one of the more advanced methods of treating heart failure and as such must be developed in smaller centers as well. In implementing the program, it is important to be in contact with a more experienced center. Due to frequent problems with coagulation, special attention should be paid to nutritional management. In the case of ischemic stroke, emergent neurointervention should be considered.

## Abbreviations

VAD, ventricular assist device; BTT, bridge to heart transplantation; MCS, mechanical circulatory support; BTR, bridge to myocardial recovery; BTB, bridge to decision; DTI, direct thrombin inhibitor; BSA, body surface area; mL, milliliters; LVAD, left ventricular assist device; BiVAD, biventricular assist device; aPTT, activated partial thromboplastin time; ROTEM, rotational thromboelastometry; LMWH, low molecular weight heparin; ASA, acetylsalicylic acid; INR, international normalized ratio; IQR, interquartile range; RCM, restrictive cardiomyopathy; DCM, dilative cardiomyopathy; ECMO, extracorporeal membrane oxygenation; *TNNI3*, gene encoding cardiac Troponin I; V-A ECMO, veno-arterial ECMO; PCPC, pediatric cerebral performance category scale; USA, United States of America; PEDIMACS, Pediatric Interagency Registry for Mechanical Circulatory Support; ELSO, Extracorporeal Life Support Organization; CYP2C9, Cytochrome P450 family 2 subfamily C member 9; VKORC1, vitamin K epoxide reductase complex subunit 1; INTERMACS, Interagency Registry for Mechanically Assisted Circulatory Support.

## Availability of Data and Materials

The datasets generated and/or analyzed during the present study is available from the corresponding author on reasonable request.

## Author Contributions

MB, MP, and TM - the conception of the study, drafting the article. MN, DŠ, DB, DBe, ŽĐ, DA, ŽČ, SK, MM, FR and GM - interpretation of data, critically revising the article. All authors contributed to editorial changes in the manuscript. All authors read and approved the final manuscript. All authors have participated sufficiently in the work to take public responsibility for appropriate portions of the content and agreed to be accountable for all aspects of the work in ensuring that questions related to its accuracy or integrity.

## Ethics Approval and Consent to Participate

The study was approved by the University Hospital Centre Zagreb Institutional Review Board (02/21 AG).

## Acknowledgment

We would like to thank prof. Sandro Dessardo for critical revision of the manuscript, prof. Daniel Dilber, dr. Slobodan Galić, dr. Vanja Ille Matić and dr. Miran Cvitković for treating the patients pre- and postoperatively. Furthermore, we would like to thank assistant professor David Ozretić and dr. Ivan Jovanović for performing neurointerventions. Dr. Vanja Zvonar made a significant contribution in discovering the impact of turmeric on coagulation disorder.

## Funding

This research received no external funding.

## Conflict of Interest

The authors declare no conflict of interest.

## References

- [1] DeBakey ME. Left ventricular bypass pump for cardiac assistance. Clinical experience. *The American Journal of Cardiology*. 1971; 27: 3–11.
- [2] Wamecke H, Berdjis F, Hennig E, Lange P, Schmitt D, Hummel M, *et al*. Mechanical left ventricular support as a bridge to cardiac transplantation in childhood. *European Journal of Cardio-Thoracic Surgery*. 1991; 5: 330–333.
- [3] Javier Delmo EM, Javier MFD, Hetzer R. The role of ventricular assist device in children. *Cardiovascular Diagnosis and Therapy*. 2021; 11: 193–201.
- [4] Mascio CE. The use of ventricular assist device support in children: the state of the art. *Artificial Organs*. 2015; 39: 14–20.

- [5] Blume ED, VanderPluym C, Lorts A, Baldwin JT, Rossano JW, Morales DLS, *et al.* Second annual Pediatric Interagency Registry for Mechanical Circulatory Support (Pedimacs) report: Pre-implant characteristics and outcomes. *The Journal of Heart and Lung Transplantation.* 2018; 37: 38–45.
- [6] Giorni C, Rizza A, Favia I, Amodeo A, Chiusolo F, Picardo SG, *et al.* Pediatric Mechanical Circulatory Support: Pathophysiology of Pediatric Hemostasis and Available Options. *Frontiers in Cardiovascular Medicine.* 2021; 8: 671241.
- [7] Almond CS, Buchholz H, Massicotte P, Ichord R, Rosenthal DN, Uzark K, *et al.* Berlin Heart EXCOR Pediatric ventricular assist device Investigational Device Exemption study: study design and rationale. *American Heart Journal.* 2011; 162: 425–435.e6.
- [8] Ghbeis MB, Vander Pluym CJ, Thiagarajan RR. Hemostatic Challenges in Pediatric Critical Care Medicine—Hemostatic Balance in VAD. *Frontiers in Pediatrics.* 2021; 9: 625632.
- [9] Taylor T, Campbell CT, Kelly B. A Review of Bivalirudin for Pediatric and Adult Mechanical Circulatory Support. *American Journal of Cardiovascular Drugs.* 2021; 21: 395–409.
- [10] Hetzer R, Kaufmann F, Delmo Walter EM. Paediatric mechanical circulatory support with Berlin Heart EXCOR: development and outcome of a 23-year experience. *European Journal of Cardio-Thoracic Surgery.* 2016; 50: 203–210.
- [11] Rockett SR, Bryant JC, Morrow WR, Frazier EA, Fiser WP, McKamie WA, *et al.* Preliminary single center North American experience with the Berlin Heart pediatric EXCOR device. *ASAIO Journal.* 2008; 54: 479–482.
- [12] Hetzer R, Potapov EV, Alexi-Meskishvili V, Weng Y, Miera O, Berger F, *et al.* Single-center experience with treatment of cardiogenic shock in children by pediatric ventricular assist devices. *The Journal of Thoracic and Cardiovascular Surgery.* 2011; 141: 616–623.e1.
- [13] Lichtenstein KM, Tunuguntla HP, Peng DM, Buchholz H, Conway J. Pediatric ventricular assist device registries: update and perspectives in the era of miniaturized continuous-flow pumps. *Annals of Cardiothoracic Surgery.* 2021; 10: 329–338.
- [14] Fraser CD, Jr, Jaquiss RDB. The Berlin Heart EXCOR Pediatric ventricular assist device: history, North American experience, and future directions. *Annals of the New York Academy of Sciences.* 2013; 1291: 96–105.
- [15] Rossano JW, VanderPluym CJ, Peng DM, Hollander SA, Maeda K, Adachi I, *et al.* Fifth Annual Pediatric Interagency Registry for Mechanical Circulatory Support (Pedimacs) Report. *The Annals of Thoracic Surgery.* 2021; 112: 1763–1774.
- [16] Hetzer R, Javier MFD, Delmo Walter EM. Role of paediatric assist device in bridge to transplant. *Annals of Cardiothoracic Surgery.* 2018; 7: 82–98.
- [17] Rossano JW, Lorts A, VanderPluym CJ, Jeewa A, Guleserian KJ, Bleiweis MS, *et al.* Outcomes of pediatric patients supported with continuous-flow ventricular assist devices: A report from the Pediatric Interagency Registry for Mechanical Circulatory Support (PediMACS). *The Journal of Heart and Lung Transplantation.* 2016; 35: 585–590.
- [18] Sharma MS, Forbess JM, Guleserian KJ. Ventricular assist device support in children and adolescents with heart failure: the Children’s Medical Center of Dallas experience. *Artificial Organs.* 2012; 36: 635–639.
- [19] Redondo A, Davies B, Jones R, O’Callaghan M, Kostolny M. Durable mechanical circulatory support in paediatric heart failure: The experience at Great Ormond Street Hospital. *Cirugía Cardiovascular.* 2019; 26: 30–34.
- [20] Javier Delmo EM, Javier MFD, Böthig D, Ruffer A, Cesnjevar R, Dandel M, *et al.* Heart failure in the young: Insights into myocardial recovery with ventricular assist device support. *Cardiovascular Diagnosis and Therapy.* 2021; 11: 148–163.
- [21] Schweiger M, E Mascio C, Kanter KR, Marasco S, Eghtesady P, Miera O, *et al.* Intracorporeal Biventricular Assist Devices Using the Heartware Ventricular Assist Device in Children. *ASAIO Journal.* 2020; 66: 1031–1034.
- [22] O’Connor MJ, Lorts A, Davies RR, Fynn-Thompson F, Joong A, Maeda K, *et al.* Early experience with the HeartMate 3 continuous-flow ventricular assist device in pediatric patients and patients with congenital heart disease: A multicenter registry analysis. *The Journal of Heart and Lung Transplantation.* 2020; 39: 573–579.
- [23] Woods RK, Kindel S, Mitchell ME, Hraska V, Niebler RA. Evolving understanding of total artificial heart support of young infants and children. *The Journal of Thoracic and Cardiovascular Surgery.* 2020; 159: 1075–1082.
- [24] George AN, Hsia TY, Schievano S, Bozkurt S. Complications in children with ventricular assist devices: systematic review and meta-analyses. *Heart Failure Reviews.* 2022; 27: 903–913.
- [25] Beasley GS, Nelson-McMillan K, Vricella L, Thompson WR, Ravekes W. Direct Echocardiographic Imaging of Berlin Heart Valves Can Aid in Early Detection of Berlin Heart Valve Dysfunction. *ASAIO Journal.* 2019; 65: e4–e6.
- [26] Fatullayev J, Samak M, Sabashnikov A, Zeriouh M, Rahmanian PB, Choi YH, *et al.* Continuous-Flow Left Ventricular Assist Device Thrombosis: A Danger Foreseen is a Danger Avoided. *Medical Science Monitor Basic Research.* 2015; 21: 141–144.
- [27] Werho DK, Pasquali SK, Yu S, Donohue J, Annich GM, Thiagarajan RR, *et al.* Hemorrhagic complications in pediatric cardiac patients on extracorporeal membrane oxygenation: an analysis of the Extracorporeal Life Support Organization Registry. *Pediatric Critical Care Medicine.* 2015; 16: 276–288.
- [28] Fraser CD, Jr, Jaquiss RDB, Rosenthal DN, Humpl T, Canter CE, Blackstone EH, *et al.* Prospective trial of a pediatric ventricular assist device. *The New England Journal of Medicine.* 2012; 367: 532–541.
- [29] Rosenthal DN, Lancaster CA, McElhinney DB, Chen S, Stein M, Lin A, *et al.* Impact of a modified anti-thrombotic guideline on stroke in children supported with a pediatric ventricular assist device. *The Journal of Heart and Lung Transplantation.* 2017; 36: 1250–1257.
- [30] Byrnes JW, Prophan P, Williams BA, Schmitz ML, Moss MM, Dyamenahalli U, *et al.* Incremental reduction in the incidence of stroke in children supported with the Berlin EXCOR ventricular assist device. *The Annals of Thoracic Surgery.* 2013; 96: 1727–1733.
- [31] Medar SS, Hsu DT, Lamour JM, Bansal N, Peek GJ. Use of bivalirudin as a primary anticoagulant in a child during Berlin Heart EXCOR ventricular assist device support. *Perfusion.* 2020; 35: 172–176.
- [32] Goyal M, Demchuk AM, Menon BK, Eesa M, Rempel JL, Thornton J, *et al.* Randomized assessment of rapid endovascular treatment of ischemic stroke. *The New England Journal of Medicine.* 2015; 372: 1019–1030.
- [33] Madaelil TP, Kansagra AP, Cross DT, Moran CJ, Derdeyn CP. Mechanical thrombectomy in pediatric acute ischemic stroke: Clinical outcomes and literature review. *Interventional Neuroradiology.* 2016; 22: 426–431.
- [34] Stowe RC, Kan P, Breen DB, Agarwal S. Mechanical thrombectomy for pediatric acute stroke and ventricular assist device. *Brain & Development.* 2018; 40: 81–84.
- [35] Wilson JL, Eriksson CO, Williams CN. Endovascular Therapy in Pediatric Stroke: Utilization, Patient Characteristics, and Outcomes. *Pediatric Neurology.* 2017; 69: 87–92.e2.
- [36] Satti S, Chen J, Sivapatham T, Jayaraman M, Orbach D. Mechanical thrombectomy for pediatric acute ischemic stroke: review of the literature. *Journal of Neurointerventional Surgery.* 2017; 9: 732–737.
- [37] Keihanian F, Saeidinia A, Bagheri RK, Johnston TP, Sahebkar A. Curcumin, hemostasis, thrombosis, and coagulation. *Journal of Cellular Physiology.* 2018; 233: 4497–4511.
- [38] Yuerek M, Kozyak BW, Shankar VR. Advances in Extracorporeal Support Technologies in Critically Ill Children. *Indian Journal of Pediatrics.* 2023; 90: 501–509.
- [39] Steffen RJ, Miletic KG, Schraufnagel DP, Vargo PR, Fukamachi K, Stewart RD, *et al.* Mechanical circulatory support in pediatrics. *Expert Review of Medical Devices.* 2016; 13: 507–514.