

Mitral Valve Replacement Adopting Chimney Technique in Mitral Insufficiency And Extensive Mitral Annular Calcification: A Case Report

Jianrui Ma, MS,^{1,2} Tong Tan, MS^{1,2} Xiaohua Li, MD, PhD,¹ Jiaoyang Li, MD, PhD,³ Zhen Zhang, MD, PhD,¹ Haiyun Yuan, MD, PhD^{1,2}

¹Department of Cardiovascular Surgery, Guangdong Cardiovascular Institute, Guangdong Provincial People's Hospital, Guangdong Academy of Medical Sciences, Guangzhou, China; ²Shantou University Medical College, Shantou, China; ³Ultrasound Department, Guangdong Provincial People's Hospital, Guangdong Academy of Medical Sciences, Guangzhou, China

ABSTRACT

Extensive and serious mitral annular calcification represents a troublesome obstacle in intracardiac mitral valve replacement due to time-consuming requirements and the potential of decalcification-associated complications. We report the case of a high-risk patient with extremely severe mitral insufficiency and difficult-to-debride annular calcification who received mitral replacement using a chimney technique. This approach enabled not only the minimization of mitral calcification debridement but also the reduction of surgery time. Consequently, the surgery was successful with a great postoperative outcome. Thus, this technique is a safe and feasible option to deal with intractable mitral annular calcification during mitral valve surgery.

INTRODUCTION

Mitral annular calcification (MAC), an active inflammatory or chronic degenerative non-inflammatory disorder, will damage the valve apparatus and contribute to the development of mitral stenosis and insufficiency [Urena-Torres 2020]. Extensive MAC during mitral valve replacement is technically challenging as complete calcification debridement places patients at risk of atrioventricular junction rupture, ventricular wall dissection, and intractable bleeding. Some institutes recommend a reconstruction using a pericardial patch after complete MAC debridement. However, it takes massive time and sometimes is impossible to finish complete MAC debridement. Here, we report a mitral valve replacement employing the chimney technique in a high-risk patient with simultaneous extremely severe mitral insufficiency and extensive MAC to minimize the calcification debridement and reduce operative time.

This study was approved by the Ethics Committee of the Guangdong Provincial People's Hospital. Informed consent of this patient for the study was obtained.

Received July 17, 2022; accepted August 6, 2022.

Correspondence: Haiyun Yuan, Department of Cardiovascular Surgery, Guangdong Cardiovascular Institute, Guangdong Provincial People's Hospital, Guangdong Academy of Medical Sciences, Guangzhou, 510080, China; +86-13430300328 (e-mail: yby_yun@163.com).

CASE REPORT

A 58-year-old female weighing 42kg was admitted to our center, due to shortness of breath at rest in New York Heart Association Class IV. She was diagnosed with extremely severe mitral insufficiency. Electrocardiogram revealed rapid atrial fibrillation and ST-T change. Transthoracic echocardiogram suggested extremely severe mitral insufficiency and posterior leaflet prolapse, with a suspicious rupture of chordae tendineae. A significant calcification within the mitral posterior leaflet, chordae, and annulus was detected. Furthermore, moderate tricuspid insufficiency, moderate pulmonary hypertension, and moderate pericardial effusion also were diagnosed. Computed tomography angiography of the full aorta demonstrated heart enlargement and mitral valve thickening and calcification (Figure 1).

After an establishment of cardiopulmonary bypass, the mitral valve was approached through an incision of the right atrium and atrial septum. As expected, severe mitral insufficiency resulting from multiple chordae tendineae and regional valve prolapse, and extensive calcification of posterior calcification from left fibrous trigone to right fibrous trigone was visualized. Mitral valve replacement using the chimney technique was performed as the extensive annular calcification led to failure in completing debridement. A customized composite valve graft was assembled by St-Jude 27 valve prosthesis and 30 mm TERUMO artificial blood vessel with running 4-0 polypropylene sutures. The length of the graft margin was tailored to approximately 1 cm

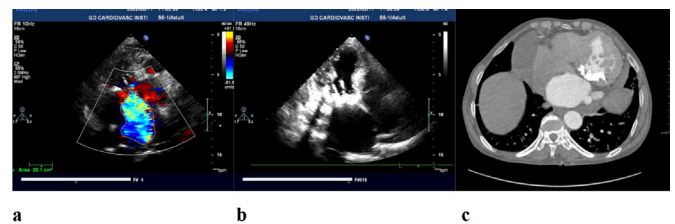


Figure 1. An extensive calcification was detected within the posterior mitral leaflet root, the sub-valve chordae, and the annulus (a). An extremely severe mitral insufficiency with a regurgitation area of 20.1cm² and posterior leaflet prolapse was observed (b). Mitral valve thickening and severe calcification were detected (c).

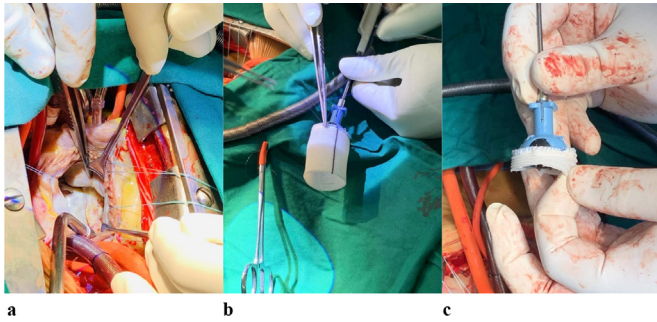


Figure 2. Intraoperative visualization of mitral apparatus (a). The composite valve graft was assembled by sewing St-Jude 27 valve prosthesis and 30 mm TERUMO artificial blood vessel (b). The length of the graft margin was tailored to approximately 1 cm with the one-side left slightly longer (c).

to prevent kinking, with the one-side left slightly longer. After the excision of both the anterior and posterior valves, the valve replacement was obtained by anterior annular sewing in situ but supra-annular sewing of posterior annular with 4-0 prolene sutures. And 2-0 Dacron pledget mattress sutures were utilized to stabilize the composite valve graft. A tricuspid valvuloplasty also was performed with 2-0 Dacron sutures (Figure 2). The cardiopulmonary bypass was eventually weaned, and the atrial septum and right atrium were closed.

Warfarin was administered to maintain the INR between 1.8 to 2.5. The symptoms and signs related to heart failure significantly were relieved to New York Heart Association Class II. The transthoracic echocardiogram at one-month follow up demonstrated a great performance of the composite mechanical valve through the chimney technique (Figure 3).

DISCUSSION

Complete debridement of extensive MAC in intracardiac valve surgery remains challenging because of the technical difficulty and potential complications. In this case, we demonstrated the safety and feasibility of the chimney technique by supra-annular implantation in mitral valve replacement for a high-risk patient with extremely severe mitral insufficiency and difficult-to-debride MAC.

Out of concern regarding debridement safety in extensive MAC, Uchimuro et al further reconstructed the mitral annulus with a pericardial patch after thorough MAC decalcification. It yielded favorable early and midterm outcomes, in terms of acceptable postoperative morbidity and mortality [Uchimuro 2016]. However, this approach might be time-consuming and not applicable to those with difficult-to-debride MAC. Bagaev et al adopted a hybrid technique by integrating transcatheter and operative approaches during mitral valve replacement to avoid MAC debridement, including the initial anterior leaflet resection, anchor suture placement, and eventual visual deployment control of the balloon-expandable prosthesis. This novel technique

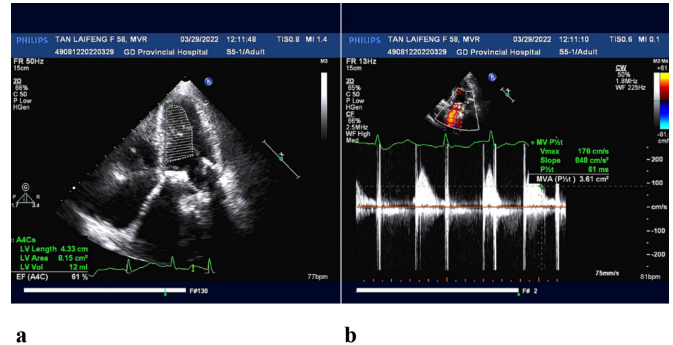


Figure 3. The echocardiogram in one-month follow up showed that the composite graft was in situ with normal motion and without an abnormal paravalvular echo (a). Neither postoperative mitral insufficiency nor stenosis was detected (b).

could avoid massive MAC debridement and address issues of transcatheter-based valve replacement like paravalvular leakage and prosthesis dislocation risk [Bagaev 2022]. But this hybrid approach requires a principal operator with expertise in both transcatheter invention and surgery. In our case, preoperative CT and intraoperative visualization demonstrated a widespread and serious MAC, which is impossible to completely debride. The patient also was at high risk and probably intolerant to long-time surgery, due to deteriorating heart function and comorbidity of atrial fibrillation. Furthermore, apart from mitral valve replacement, the patient required tricuspid valvuloplasty in the plan as well. We thereby needed to minimize the MAC debridement and limit the surgery time to as short as possible.

The chimney technique has been reported to be used to solve patient-prosthesis mismatch in pediatrics undergoing mitral valve replacement and in adults undergoing Bentall procedure [Gonzalez 2013; Song 2020]. Interestingly, Go et al first reported the use of the chimney technique in a patient with severe mitral stenosis and massive MAC, suggesting its feasibility to avoid complete MAC debridement during mitral valve surgery [Go 2020]. We considered it also might be applicable and thereby used it in the extremely severe mitral insufficiency patient combined with massive MAC during mitral valve replacement. Given the impossibility of posterior annulus calcification, the composite graft was secured with supra-annulus sewing of the posterior annulus and annulus sewing of the anterior annulus. The edge of the posterior side of the conduit in the composite graft was thereby left slightly longer than the other side to accommodate the level difference of sewing sites. Another important technical point would be the reinforcement of the graft to prevent paravalvular leakage. Given the native annulus size bigger than the graft, additional 2-0 Dacron pledget mattress sutures were utilized to secure and reinforce the graft.

Therefore, the chimney-based mitral valve replacement is a safe and feasible alternative in mitral insufficiency patients with difficult-to-debride MAC, which can minimize the calcification debridement and reduce surgery time.

ACKNOWLEDGEMENT

We are grateful for the helpful comments from each member of Chen's group.

REFERENCES

Bagaev E, Ali A, Saha S, et al. 2022. Hybrid Surgery for Severe Mitral Valve Calcification: Limitations and Caveats for an Open Transcatheter Approach. *Medicina (Kaunas)*. 58.

Go S, Furukawa T, Yamada K, Hiraoka T, Mochizuki S. 2020. A case of supra-annular mitral valve replacement using chimney technique for severe mitral stenosis with extensive mitral annular calcification. *Gen*

Thorac Cardiovasc Surg. 68:1199-1202.

Gonzalez Rocafort A, Aroca A, Polo L, Rey J, Villagra F. 2013. Chimney technique for mitral valve replacement in children. *Ann Thorac Surg*. 96:1885-7.

Song L, He G, Imin E, et al. 2020. "Chimney" Bentall Procedure in the Small Aortic Root After Prior Aortic Valve Operations. *Ann Thorac Surg*. 110:e241-e243.

Uchimuro T, Fukui T, Shimizu A, Takanashi S. 2016. Mitral Valve Surgery in Patients With Severe Mitral Annular Calcification. *Ann Thorac Surg*. 101:889-95.

Urena-Torres P, D'Marco L, Raggi P, et al. 2020. Valvular heart disease and calcification in CKD: more common than appreciated. *Nephrol Dial Transplant*. 35:2046-2053.