

Transapical Transcatheter Aortic Valve Implantation for Aortic Regurgitation in Takayasu Arteritis

Xiao-Ping Ning, MD,¹ Wei Wang, MD,¹ Fang-Lin Lu, MD, PhD,¹ Meng-Xing Li, MD,² He Wang, MD,¹ Ning Li, MD,¹ Guang-Wei Zhou, MD,¹ Fan Qiao, MD, PhD,¹ Zhi-Yun Xu, MD, PhD,¹ Hao Tang, MD, PhD¹

¹Department of Cardiovascular Surgery, Changhai hospital affiliated to the Naval Medical University, Shanghai, China;

²Department of Thoracic Surgery, Changhai hospital affiliated to the Naval Medical University, Shanghai, China

ABSTRACT

Transcatheter aortic valve implantation (TAVI) has become a popular treatment for surgical high-risk patients with severe aortic stenosis (AS). Recently, we have applied TAVI to the treatment of aortic regurgitation (AR). Compared with conventional surgical procedures, TAVI is less invasive and considered a useful option for these high-risk patients. In this study, we reported a patient who underwent transapical TAVI. The patient was a 52-year-old female with Takayasu arteritis (TA) for 25 years, as well as with severe aortic regurgitation, porcelain aortas, and heart failure. Transapical TAVI successfully was accomplished without neurological complications, and heart failure immediately improved postoperatively.

INTRODUCTION

Takayasu arteritis, known as ‘pulseless disease,’ first was described by Takayasu in 1908. TA is a chronic inflammatory condition predominantly affecting young Asian females. It is a rare large vessel vasculitis disease that mainly involves the aorta and its main branches [Zhang 2020]. Occasionally, it complicates porcelain aorta, coronary artery ostial stenosis, and aortic regurgitation (AR) with or without stenosis. The incidence of AR in patients with TA is between 13%-25%, and AR is considered an important risk factor for mortality in patients with this disease [Miyata 2003]. The conventional treatment of AR associated with TA is aortic valve replacement (AVR). It is of severe trauma and complex complications, especially in patients with porcelain aorta. In addition, intimal calcification of the aorta caused by TA makes it difficult to manipulate in the artery. In this case, we successfully performed the operation of transapical TAVI for aortic regurgitation and porcelain aorta in TA.

CASE REPORT

A 52-year-old woman first presented with exertional dyspnea and chest tightness for 3 years. She was admitted to our hospital in October 2020, due to progressive and increasing exertional dyspnea and chest tightness one month prior to admission. She had a 25-year history of TA and was not regularly treated. Physical examination revealed her blood pressure was 145/72mmHg, and there was no significant difference between the upper and lower extremities. The aortic valve auscultation area could be heard, and a diastolic grade 3/6 sigh-like murmur. Serological tests were negative for C-reactive protein (CRP), erythrocyte sedimentation rate (ESR), and syphilis. Transthoracic echocardiography (TTE) showed severe aortic regurgitation with an ejection fraction (EF) of 33% (Figure 1A and 1B). (Figure 1) The diameters of the aortic annulus, Valsalva sinus, sinotubular junction, and ascending aorta were 25mm, 44mm, 35mm, and 37mm, respectively. Carotid ultrasound revealed the right common carotid artery was occluded, and the internal carotid artery was supplied by the external carotid artery. Femoral artery ultrasound revealed bilateral femoral artery intimal thickening with small plaque formation. Digital subtraction and computed tomography angiograms (CTA) documented a circumferential aortic calcification between the aortic root and descending aorta (Figure 2A and 2B). (Figure 2) Coronary angiogram revealed 30% stenosis of the proximal left coronary artery and no stenosis of the left coronary artery. In view of the patient's porcelain aorta, we decided to perform transapical TAVI to treat aortic regurgitation.

Transesophageal echocardiography (TEE) was performed to evaluate the morphology of the aortic root and monitor the whole process of valve positioning and deployment. A pigtail catheter was inserted above the non-coronary sinus of Valsalva by the Seldinger method through the right femoral artery. Ascending aortic root angiogram was performed before operation, which showed massive regurgitation of the aortic valve. A minimal left thoracic incision was made over the optimal intercostal space and a purse-string suture was made on the left ventricle apex as hexagonal shapes. The primary aortic root angiogram was performed through the pigtail catheter to set the optimal angle of C-arm. Then, TAVI using 27-mm J-Valve by transapical approach was performed. Another ascending aortic root angiogram showed no paravalvular leak and completely normal of the left coronary artery

Received May 19, 2022; accepted July 11, 2022.

Correspondence: Hao Tang, Department of Cardiovascular Surgery, Changhai Hospital, 168# Changhai Road, Yangpu District, Shanghai, China, 200433, Telephone +8613601965418 (e-mail: doctor_tanghao2020@163.com).

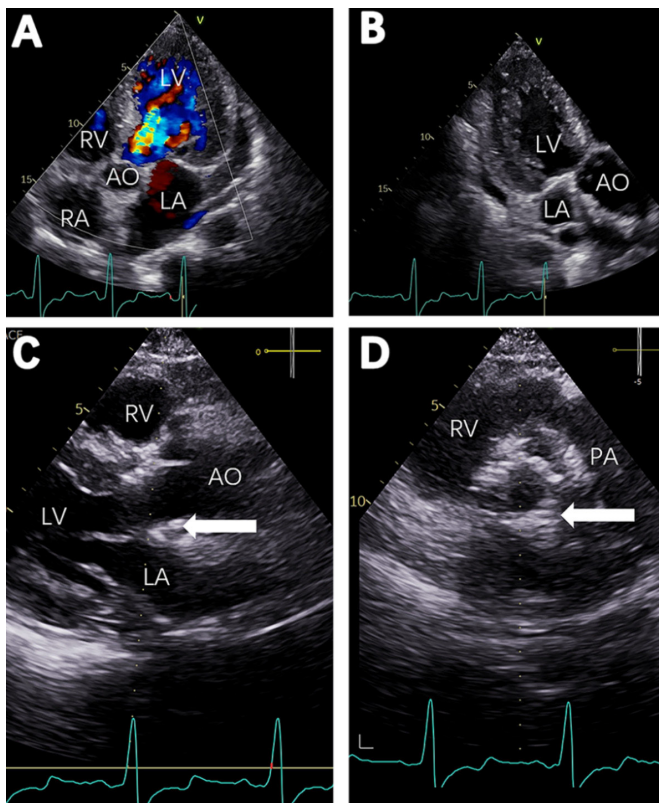


Figure 1. Preoperative echocardiograms (A and B) indicated severe aortic regurgitation. Postoperative echocardiograms at 0.5-year follow-up (C and D) showed the aortic valve prosthesis (arrow). AO, ascending aorta; LA, left atrium; LV, left ventricle; PA, pulmonary artery; RV, right ventricle; RA, right atrium

and right coronary artery. Neither arrhythmia nor hemodynamic instability occurred during the operation. The postoperative course was uneventful, and the patient was discharged at postoperative day 10. TTE at 0.5-year follow up showed no paravalvular leak with an ejection fraction of 59%, and the position of the bioprosthesis was normal, with good opening and closing (Figure 1C and 1D). Postoperative enhanced computed tomography showed the stent of the aortic valve prosthesis (Figure 2C and 2D).

DISCUSSION

A study indicated that TA patients with severe complications have a poor prognosis [Ishikawa 1994]. In this case, the patient had severe AR with heart failure and obvious symptoms. Therefore, operation for AR was suitable for this patient. However, conventional aortic valve replacement under cardiopulmonary bypass and cardiac arrest was difficult because of the porcelain aorta. Therefore, we gave up surgical treatment and chose interventional treatment.

It is reported that transfemoral TAVI performed in patients with porcelain aorta is likely to be associated with higher rates of stroke than transapical TAVI [Useini 2020]. The incidence

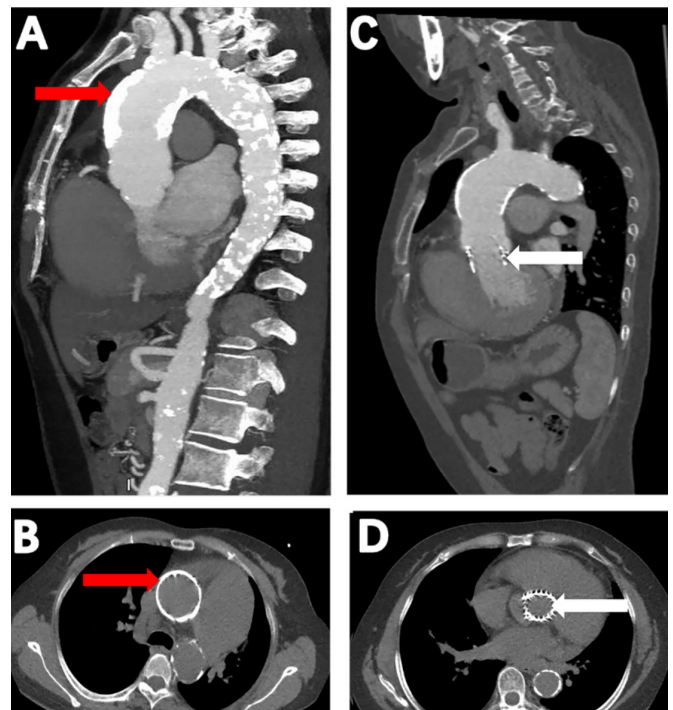
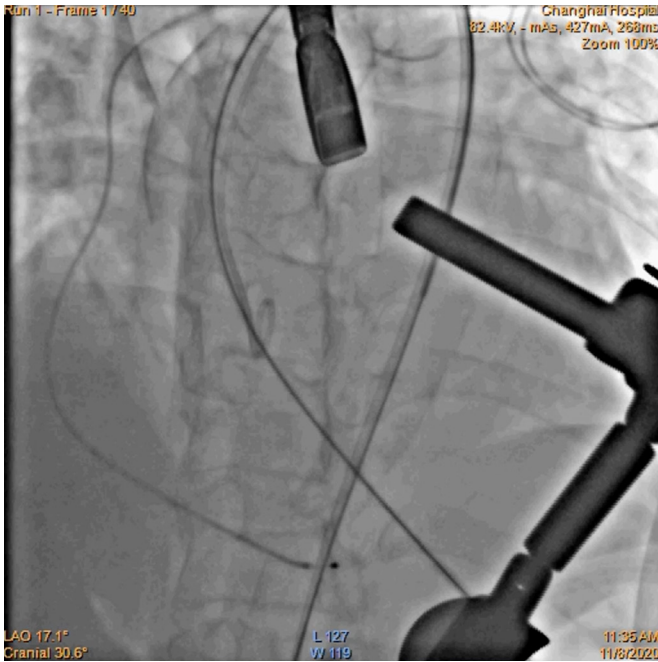


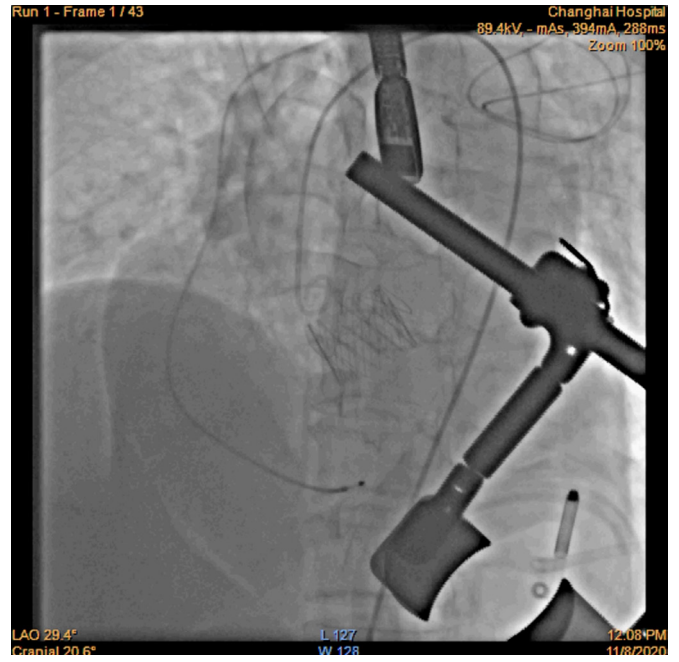
Figure 2. A and B, Preoperative enhanced computed tomography showed the porcelain aorta (red arrow). C and D, Postoperative enhanced computed tomography showed the stent of the aortic valve prosthesis at 0.5-year follow-up (white arrow).

of cerebral embolism, following the transfemoral TAVI, is reported to be over 70% as evaluated by diffusion-weighted magnetic response imaging [Kahlert 2010]. Therefore, it is important to prevent brain embolism in patients with porcelain aortas. The large Transcatheter Valve Therapies registry suggested that the composite outcome of mortality and stroke occurs in 26.0% of patients over 1 year of follow up [Holmes 2015]. Although transfemoral TAVI has been reported to treat AR with porcelain aorta, it is of high risk to use it in this case. Transcaval access TAVI delivers large vascular sheaths into the abdominal aorta via the femoral vein through the inferior vena cava [Greenbaum 2014]. Before this complicated procedure, contrast-enhanced CT was used to select an optimal caval-aortic crossing trajectory to avoid the least-calcified aortic wall. Although transcaval TAVI has been reported, it was impossible to perform it in this case because of the calcification of the aortic arch. Based on these facts, we chose transapical TAVI for this patient. Her EF on postoperative day 4 had a dramatic increase compared with her preoperative EF, from 33% to 44%. Due to damage to myocardial cells during the operation and because of unclear long-term results after transapical, follow-up TTE is crucial for this patient. We recommend TEE be conducted every 3-6 months in this case.

This case presentation demonstrated that transapical TAVI is considered a safe method to treat AR in TA patients with porcelain aorta. Meanwhile, it was an effective procedure to avoid aortic manipulation to reduce neurological



Video 1 Legend: Preoperative ascending aortic root angiogram showed massive regurgitation of the aortic valve. (<https://vimeo.com/747360708>)



Video 2 Legend: Postoperative ascending aortic root angiogram showed no paravalvular leak of the aortic valve. (<https://vimeo.com/747362267>)

complications. The early clinical and echocardiography outcomes in such cases are promising. Long-term results of transapical TAVI and its durability need to be confirmed in further study.

REFERENCES

Greenbaum AB, O'Neill WW, Paone G, et al. 2014. Caval-aortic access to allow transcatheter aortic valve replacement in otherwise ineligible patients: initial human experience. *J Am Coll Cardiol.* 63:2795-2804.

Holmes DR, Jr., Brennan JM, Rumsfeld JS, et al. 2015. Clinical outcomes at 1 year following transcatheter aortic valve replacement. *JAMA.* 313:1019-1028.

Ishikawa K, Maetani S. 1994. Long-term outcome for 120 Japanese patients with Takayasu's disease. Clinical and statistical analyses of related prognostic factors. *Circulation.* 90:1855-1860.

Kahlert P, Knipp SC, Schlamann M, et al. 2010. Silent and apparent

cerebral ischemia after percutaneous transfemoral aortic valve implantation: a diffusion-weighted magnetic resonance imaging study. *Circulation.* 121:870-878.

Lederman RJ, Greenbaum AB, Rogers T, Khan JM, Fusari M, Chen MY. 2017. Anatomic suitability for transcaval access based on computed tomography. *JACC Cardiovasc Interv.* 10:1-10.

Miyata T, Sato O, Koyama H, Shigematsu H, Tada Y. 2003. Long-term survival after surgical treatment of patients with Takayasu's arteritis. *Circulation.* 108:1474-1480.

Useini D, Haldenwang P, Schlömicher M, et al. 2020. Mid-term outcomes after transapical and transfemoral transcatheter aortic valve implantation for aortic stenosis and porcelain aorta with a systematic review of transfemoral versus transapical approach. *The Thoracic and Cardiovascular Surgeon.* 68:623-632.

Zhang Y, Fan P, Zhang H, et al. 2020. Surgical treatment in patients with aortic regurgitation due to Takayasu arteritis. *Ann Thorac Surg.* 110:165-171.