

# Comparison of Sternal Fixation Strategies After Open-Heart Surgery Via a Median Sternal Incision

Jianzhou Liu\*,<sup>1</sup> Xiaokun Chen\*,<sup>2</sup> Guotao Ma,<sup>1</sup> Xingrong Liu,<sup>1</sup> Xiaofeng Li,<sup>1</sup> Qi Miao,<sup>1</sup> Chaoji Zhang<sup>1</sup>

<sup>1</sup>Department of Cardiac Surgery, Peking Union Medical College Hospital, Chinese Academy of Medical Sciences, Beijing, China;

<sup>2</sup>Department of Surgery, Peking Union Medical College Hospital, Chinese Academy of Medical Sciences, Beijing, China

## ABSTRACT

**Objectives:** To explore the personalized treatment strategy of sternal fixation and closure of sternal median incision in open cardiac surgery.

**Methods:** A total of 293 patients who underwent open-heart surgery with a median sternal incision at Peking Union Medical College Hospital from January 2019 to March 2021 were divided into two groups, according to the timing and type of treatment. The first 169 patients received single-wire fixation and closure (control group), while the subsequent 124 patients received double-wire fixation and closure (study group). The patients were followed up for three months to observe the duration of pain, sternal instability, and occurrence of chest wound infection.

**Results:** The average age was 53±30 years in the control group and 55±34 years in the study group ( $P = 0.594$ ). There were no significant differences in baseline data between the two groups ( $P > 0.05$ ). Compared with the control group, the study group had a shorter duration of pain ( $P < 0.05$ ), smaller drainage volume within three days postoperatively (650 ml vs. 770 ml,  $P < 0.05$ ), lower incidence of superficial sternal wound infection (2.4% vs. 8.9%,  $P = 0.042$ ), and lower incidence of sternal instability (1.6% vs. 8.3%,  $P = 0.026$ ). Deep sternal wound infection occurred in two patients in the control group and none in the study group; however, this difference was not significant. No surgery-related deaths occurred.

**Conclusions:** Selecting the appropriate sternal fixation and closure method, according to the characteristics of patients, can reduce the incidence of sternal incision complications. We proposed a personalized selection strategy for sternal fixation and closure, which requires verification in clinical studies.

## INTRODUCTION

A median sternal incision provides good exposure for open-heart surgery and is still the most common surgical approach for cardiac surgery. Although the incidence of sternal wound infection has decreased to 1%–4% for deep sternal incisions, this complication still has a mortality rate of 14%–50% and reduces the long-term life expectancy [Milano 1995; Braxton 2000; El 1996; Schimmer 2008]. Deep sternal wound infection remains one of the most disastrous complications after cardiac surgery. This complication prolongs the length of hospital stay and significantly increases the cost of hospitalization [Gray 2017].

Previous studies have reported that sternal wound complications are related to risk factors, such as the female gender, obesity, sternal osteoporosis, advanced age, renal insufficiency, chronic obstructive pulmonary disease (COPD), and harvesting of the bilateral internal thoracic arteries [Gray 2017; Filsoufi 2009; Eklund 2006; Alebrahim 2020]. Furthermore, sternal wound infection is associated with sternal dehiscence and instability [Braxton 2000; Robicsek 2000]. Stable fixation and closure of the sternal wound is necessary to achieve integration of both sides of the sternum and help rebuild local blood supply and nutrition. These findings suggest that surgeons must fully consider the individual patient's risk factors in the process of sternal closure, and that a tailored sternal fixation and closure method plays a key role in the prevention of deep sternal wound infection. For example, steel sutures can easily cut the osteoporotic sternum when tightened, while strengthening of the integrity of the sternum reduces sternal wound complications. There are several techniques used for sternal closure after cardiac surgery, but the optimal technique for sternal fixation and closure in high-risk patients has not been determined due to a lack of randomized controlled clinical studies and the heterogeneity of the existing literature.

Herein, we summarize the methods and outcomes of sternal fixation and closure techniques used in 293 patients, who underwent open-heart surgery with a median sternal incision in our hospital from January 2019 to March 2021, and review the relevant literature. The aim of this study was to evaluate the effect of different sternal closure techniques on the clinical outcomes and to explore the strategy of individualized sternal fixation and closure techniques after median sternotomy.

Received May 6, 2022; received in revised form June 13, 2022; accepted June 14, 2022.

\*Jianzhou Liu\*, MD Xiaokun Chen, MD contributed to this paper equally.

Correspondence: Chaoji Zhang, Department of Cardiac Surgery, Peking Union Medical College Hospital, Chinese Academy of Medical Sciences, Beijing, China, 100730, Telephone +86-10-69152820, Fax +86-10-69152820 (e-mail: [chaojizhang@163.com](mailto:chaojizhang@163.com)).

## MATERIALS AND METHODS

**Data collection:** In this retrospective cohort study, we screened 293 patients, who underwent anterior midline cardiac surgery in our hospital from January 2019 to March 2021. We excluded patients with emergency surgery, perioperative death, and secondary surgery. The Ethics Research Board of PUMCH approved this retrospective study. The collected data included patients' baseline data, surgical method, method of sternal closure, postoperative drainage volume, duration of postoperative chest pain, sternal dehiscence, superficial sternal tissue infection, and deep sternal wound infection.

**Surgical technique:** All patients underwent an anterior median sternal incision with a single wide blade retractor (Millennium Surgical Corp., Narberth, PA, USA). After the attainment of good hemostasis and placement of the drainage tube, different methods or combinations of sternal closure were selected based on each patient's situation. The following five sternal closure methods were used: (1) single steel wire fixation: one steel wire was inserted through the sternal manubrium, and five single steel wires were respectively fixed through the first to the fifth rib spaces; (2) double steel wire fixation: one steel wire was passed through the sternal manubrium, and five double-steel wires were used to close both sides of the sternum through the first to the fifth rib spaces; (3) combined fixation using the Robicsek technique + steel wire (single or double): a steel wire was used to cross the intercostal region and surround the ribs along one side of the sternum, and single- or double-steel wire was used to cross the weaved steel wire on the outside of the braided wire to close and fix the sternum; (4) combined fixation using sternal allogeneic cancellous bone transplantation + steel wire (single or double): when the patient was found to have weak sternum, severe osteoporosis, or large cancellous bone defect (>5mm) during the operation, the allogeneic cancellous bone would be filled before the sternum was fixed and closed with steel wire; (5) combined fixation with a steel plate and steel wire: after fixing and closing the sternum with single steel wires in the first, second, and fifth intercostal spaces, bone reduction forceps were used to pull both sides of the sternum together to achieve complete approximation, and at least two appropriate steel plates were selected to fix the sternum.

**Postoperative follow up:** All patients who were discharged received follow up for three months. The collected data included the duration of pain, wound healing state, and the occurrence of incision complications, which were defined as terminal events. The incision complications included sternal instability and superficial and deep chest tissue infections. Sternal instability was defined as a sternal fracture with no signs of infection. Superficial tissue infection was defined as infection involving the subcutaneous soft tissue without osteomyelitis. Deep infection was defined as sternal infection caused by bacteria or clinically proven sternal osteomyelitis.

**Statistical analysis:** The body mass index of each patient was derived from their height and weight. Continuous variables were expressed as mean  $\pm$  standard deviation and analyzed by the Student's *t* test. Categorical variables were

expressed as rates and percentages and compared using Fisher's exact test. A *P*-value of less than 0.05 was considered statistically significant. Statistical software (SPSS, version 18.0) was used for the statistical analysis.

## RESULTS

From January 2019 to March 2021, 293 patients who underwent open-heart surgery were screened for study eligibility. Among the 293 patients, 169 patients received sternal closure using the single-wire fixation technique and 124 patients underwent sternal closure via the double-wire technique. All operations were performed by the same surgeon. Patient baseline data are summarized in Table 1. (Table 1)

Compared with the control group, the study group had a significantly shorter duration of pain ( $P < 0.05$ ), significantly smaller mean drainage volume within three days postoperatively (650 mL vs. 770 mL,  $P < 0.05$ ), significantly lower incidence of superficial sternal wound infection (2.4% vs. 8.9%,  $P = 0.042$ ), and significantly lower incidence of sternal instability (1.6% vs. 8.3%,  $P = 0.026$ ). During three months of follow up, deep sternal wound infections occurred in two patients in the control group and no patients in the study group; however, this intergroup difference was not statistically significant. There were no surgery-related deaths in the two groups. (Table 2)

## DISCUSSION

Although great progress has been made in the treatment of chest wound infections, deep chest wound infection still has a high mortality rate, which affects the prognosis of cardiac surgery. The main cause of chest wound complications is instability of the sternum. Techniques used to improve the stability of the sternum after fixation include the use of special chest openers or auxiliary devices to protect the sternum [Kirbas 2011], improved sternal closure and fixation methods [El 1996; Cleeland 1994; Song 2004], and the application of auxiliary materials to increase the support force of the sternum. For more than half a century, the strength and simplicity of stainless-steel wire has made wire fixation of the sternum a standard technique for thoracotomy. However, due to the occurrence of complications after wire sternal closure, such as sternal dehiscence, mediastinitis, sternal osteomyelitis, and infection, clinicians are prompted to develop new sternal closure techniques. The main sternum fixation methods include single wire fixation, double wire fixation, Robicsek technique, steel plate fixation, steel strap fixation, synthetic polymer strap fixation, etc. [Cataneo 2019].

According to related research [Nenna 2019; Nooh 2021], we choose obesity, COPD, diabetes and harvesting of the bilateral internal thoracic arteries as crucial risk factors affecting the stability of the sternum postoperative. After making reasonable judgments on the patient's health status and the quality of the sternum, we worked out a personalized sternal fixation and closure plan.

Table 1. Summary of baseline data for 293 median sternotomy patients

| Characteristic              | Group A (N = 169) | Group B (N = 124) | P     |
|-----------------------------|-------------------|-------------------|-------|
| Age, years                  | 53 ± 30           | 55 ± 34           | 0.594 |
| Male                        | 108 (64)          | 82 (66)           | 0.787 |
| BMI, kg/m <sup>2</sup>      | 31.2 ± 10         | 30.5 ± 11         | 0.554 |
| Hypertension                | 51 (30)           | 39 (31)           | 0.916 |
| Obesity <sup>b</sup>        | 41 (24)           | 40 (32)           | 0.177 |
| Kidney disease <sup>c</sup> | 20 (12)           | 18 (15)           | 0.617 |
| Sternal osteoporosis        | 28 (17)           | 20 (16)           | 0.952 |
| COPD                        | 15 (9)            | 13 (10)           | 0.794 |
| Corticosteroid use (>6 mo)  | 20 (12)           | 13 (12)           | 0.909 |
| LVEF <0.30                  | 15 (8.9)          | 16 (13)           | 0.360 |
| Diabetes mellitus           | 61 (36)           | 40 (32)           | 0.577 |
| Smoking history             | 40 (24)           | 31 (22)           | 0.901 |
| Infection endocarditis      | 20 (12)           | 18 (15)           | 0.617 |
| Isolated CABG               | 88 (52)           | 54 (44)           | 0.186 |
| Isolated valve surgery      | 50 (30)           | 35 (28)           | 0.901 |
| Bilateral ITA harvesting    | 3 (1.8)           | 4 (3.2)           | 0.677 |
| Other surgery               | 31 (18)           | 35 (28)           | 0.063 |
| Aortic occlusion time (min) | 59 ± 31.2         | 56 ± 29.1         | 0.404 |
| CPB time (min)              | 89.2 ± 34.6       | 85.8 ± 37.5       | 0.423 |
| Operative time (min)        | 241.2 ± 49.5      | 235.4 ± 51.6      | 0.331 |
| Evidence of fractured       | 25 (15)           | 24 (19)           | 0.381 |
| Robiscek's technique        | 19 (11)           | 8 (6)             | 0.231 |
| Rigid plate                 | 5 (3)             | 3 (2.4)           | 0.934 |
| Bone allografts             | 21 (12)           | 18 (14.5)         | 0.729 |

Group A, single wire suture; Group B, double wire suture

a) Unless otherwise noted, data are presented as mean ± standard deviation or number (%). *P* < 0.05 was considered statistically significant; b) body mass index > 30 kg/m<sup>2</sup>; c) creatinine level > 113 μmol/l; d) at the time of sternal closure. COPD, chronic obstructive pulmonary disease; LVEF, left ventricular ejection fraction; CPB, cardiopulmonary bypass; CABG, coronary artery bypass grafting

It is common to use a single stainless-steel wire in sternotomy and closure surgery. The infection rate of sternal wounds closed using six or less wires is reportedly 4.2%, while the infection rate of sternal wounds closed using seven or more wires is 0.4% [Friberg 2006]. Adding a second wire can further resist tearing of the sternum and better distribute the forces acting on the sternum. An autopsy study confirmed that the double-wire fixation technique is more biomechanically stable than the single-wire fixation technique [Losanoff 2007]. Studies identified that the use of double steel wires reduces sternal dehiscence compared with a single steel wire in patients with obesity [Sharma 2004; Loladze 2017; Shafi 2021], but no further clinical data have been reported. The present results prove that double-wire fixation of the sternum increases the stability of the sternum and reduces the incidence of chest wound infections. For those patients with

more than one risk factor, we always choose double-wire fixation and closure.

Sternal osteoporosis is a major risk factor for sternal instability and chest wound infection after open-heart surgery. The incidence of osteoporosis is 2% to 8% in men and 9% to 38% in women in developed countries [Muehrcke 2009], and about 13% in China [Wade 2014]. Previous studies have revealed that for osteoporotic patients, allogeneic bone grafting of the osteoporotic sternum not only increases the support for the fragile sternum, but also improves the stability of the sternum and reduces the wound drainage volume, thereby reducing the risk of complications [Liang 2018]. In our study, allogeneic cancellous bone sternum transplantation was performed in 40 cases. Meanwhile, the number of combined risk factors determines whether to use double steel wires for fixation.

Table 2. Postoperative outcomes

| Characteristic                      | Group A (N = 169) | Group B (N = 124) | P     |
|-------------------------------------|-------------------|-------------------|-------|
| Ventilation time, days              | 1 (0-31)          | 1 (0-36)          | 1.000 |
| Length of ICU stay, days            | 2 (1-35)          | 2 (1-53)          | 0.802 |
| Length of hospital stay, days       | 12 (7-98)         | 11 (7-105)        | 0.153 |
| Postoperative drainage, the first 3 | 770 (250-1400)    | 650 (200-1350)    | 0.032 |
| Duration of chest pain, >3d         | 50 (30)           | 21 (17)           | 0.018 |
| Sternal instability                 | 14 (8.3)          | 2 (1.6)           | 0.026 |
| Superficial sternal wound infection | 15 (8.9)          | 3 (2.4)           | 0.043 |
| Deep sternal wound infection        | 2 (1.2)           | 0 (0)             | 0.618 |
| Sternum-related death               | 0 (0)             | 0 (0)             |       |

Data are presented as number (%) for categorical variables, mean ± SD for normally distributed variables, and median (range) for non-normally distributed variables

The Robicsek technique comprises longitudinal weaving beside the sternum, followed by lateral fixation with steel wire, and is a good choice for high-risk patients with sternal osteoporosis [Losanoff 2007]. The steel wire braided next to the sternum disperses the shearing force of the transverse steel wire on the sternum, enabling the achievement of close convolution and fixation of the sternum and preventing movement of the sternum on both sides. However, this method also has disadvantages, including a decreased blood supply to the sternum and ribs on both sides, leading to local malnutrition, bone healing difficulties, sternal instability, and other complications [Kiessling 2005]. Other drawbacks include increased operation time and the inability of wire braiding to reach the head and tail of the sternum. Robicsek's braided sternum was performed in 27 cases in our study, including 19 cases with single-wire and eight cases with double-wire. A prospective study identified that Robicsek's braided sternum should be used for high-risk patients to minimize postoperative complications and morbidity [Narang 2009]. The Robicsek technique was widely used in the single-wire fixation group, while in the double-wire fixation group, it was mainly used in patients with an off-center or weak semi-sternum, or when the sternum was crossed in more than two places during thoracotomy. Overall, when using the Robicsek method, clinicians must try to avoid reducing the blood supply from the sternal collaterals.

Studies proved that sternal fixation using a steel plate increases the stability of the sternum, reduces postoperative pain, and improves the primary bone healing rate in comparison with wire fixation [Tam 2018; Snyder 2009]. A meta-analysis which included three randomized controlled trials and five observational studies identified that there was no significant difference between the plate fixation group and the steel wire fixation group, in terms of sternal complications. Further analysis in the high-risk subgroup of sternal complications shows that plate fixation effectively can reduce the complications of chest wounds in high-risk patients, improve the perioperative survival rate, and shorten the length of hospital stay [Tam 2018]. Plate fixation is an ideal choice for patients

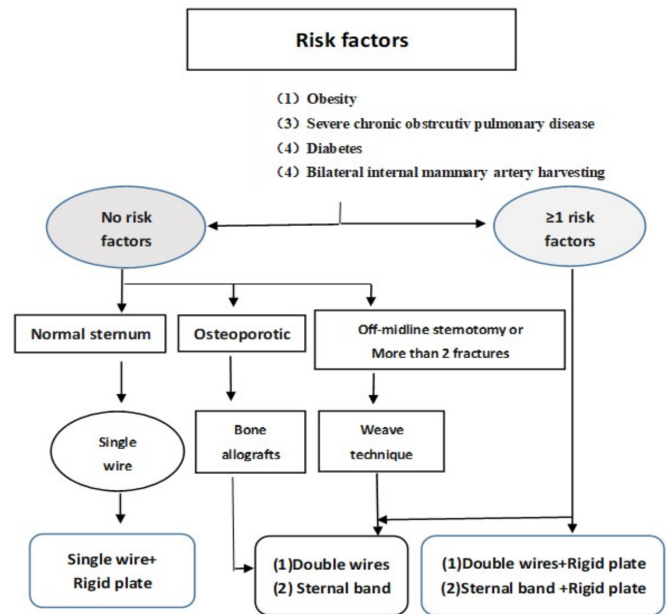


Figure 1. Algorithm of tailored sternal closure

with obesity or patients with chronic obstructive pulmonary emphysema. For patients with emphysema, plate fixation reduces the incidence of perioperative pneumothorax due to wire piercing. However, surgeons must carefully consider the medical costs, potential damage to nearby structures caused by screw drilling, and the inconvenience of emergency chest opening after plate fixation. Furthermore, the application of plate fixation is limited for osteoporotic patients, as they cannot withstand drilling of the sternum.

The combination of steel plate + steel wire to fix and close the sternum realizes the advantages of the steel plate while enhancing the lateral stability of the sternum. Application of this combined technique also alleviates part of the financial burden and is gradually becoming accepted by cardiologists.

Another option for sternal fixation is the use of steel straps. There are two types of straps for clinical applications – steel straps and polymer straps. The strap is similar to the double steel wires, allowing the shear force to be distributed over a larger surface area to avoid cutting the fragile sternum. Studies have shown that patients who undergo sternal closure with a steel strap have a lower incidence of sternal dehiscence and mediastinitis than those who undergo sternal closure with a single wire, suggesting that steel strap closure may be an effective way to reduce the complications in high-risk patients [Franco 2009; Bhattacharya 2007]. However, the rigidity of the straps means that they do not fit well with the sternum and are not easy to cut during emergency chest opening. Polymer straps have the advantages of steel straps. At the same time, the soft strap material can more perfectly adapt to the sternum, increase the contact area, better disperse the shearing force, and avoid sternal cutting. In emergency surgery, polymer straps are easier to cut than steel straps [Nezafati 2019].

In this group, the chest wound-related infection rate of 2.4% is consistent with the report [Friberg 2006]. Based on previous literature and combined with the author's clinical data, we believe that choosing different sternal fixation methods according to patient characteristics (Figure 1) can reduce chest wound-related complications, while not increasing the operation time. (Figure 1)

## CONCLUSION

Although the ideal sternal closure technique is still controversial, a stable sternal closure technique is strongly correlated with a reduction in postoperative chest wound complications. This requires clinicians to consider not only patient risk factors, but also the effectiveness, durability, and cost-effectiveness of the sternal closure technique. Surgeons must create a personalized sternal closure plan for each patient. We have proposed a personalized selection strategy for sternal fixation and closure technology; the effectiveness of this strategy needs to be verified in clinical studies.

## ACKNOWLEDGEMENTS

We thank all the patients, their families, the investigators, and medical staff. We also thank Kelly Zammit, BVSc, from Liwen Bianji (Edanz) ([www.liwenbianji.cn/](http://www.liwenbianji.cn/)) for editing the English text of a draft of this manuscript.

## REFERENCES

- Alebrahim K, Al-Ebrahim E. 2020. Prevention, Classification and Management Review of Deep Sternal Wound Infection[J]. *Heart Surg Forum*. 23(5): E652-E657.
- Bhattacharya S, Sau I, Mohan M, et al. 2007. Sternal bands for closure of midline sternotomy leads to better wound healing[J]. *Asian Cardiovasc Thorac Ann*. 15(1): 59-63.
- Braxton JH, Marrin CA, Mcgrath PD, et al. 2000. Mediastinitis and long-term survival after coronary artery bypass graft surgery[J]. *Ann Thorac Surg*. 70(6): 2004-2007.
- Cataneo DC, Dos RT, Felisberto G, et al. 2019. New sternal closure methods versus the standard closure method: systematic review and meta-analysis[J]. *Interact Cardiovasc Thorac Surg*. 28(3): 432-440.
- Cleeland CS, Ryan KM. 1994. Pain assessment: global use of the Brief Pain Inventory[J]. *Ann Acad Med Singap*. 23(2): 129-138.
- Eklund AM, Lyytikainen O, Klemets P, et al. 2006. Mediastinitis after more than 10,000 cardiac surgical procedures[J]. *Ann Thorac Surg*. 82(5): 1784-1789.
- El OR, Wright JE. 1996. Postoperative mediastinitis: classification and management[J]. *Ann Thorac Surg*. 61(3): 1030-1036.
- Filsoufi F, Castillo JG, Rahmanian PB, et al. 2009. Epidemiology of deep sternal wound infection in cardiac surgery[J]. *J Cardiothorac Vasc Anesth*. 23(4):488-494.
- Franco S, Herrera AM, Atehortua M, et al. 2009. Use of steel bands in sternotomy closure: implications in high-risk cardiac surgical population[J]. *Interact Cardiovasc Thorac Surg*. 8(2): 200-205.
- Friberg O, Dahlin LG, Soderquist B, et al. 2006. Influence of more than six sternal fixation wires on the incidence of deep sternal wound infection[J]. *Thorac Cardiovasc Surg*. 54(7): 468-473.
- Gray AM, Murphy J, Altman DG, et al. 2017. One-year costs of bilateral or single internal mammary grafts in the Arterial Revascularisation Trial[J]. *Heart*. 103(21): 1719-1726.
- Kiessling AH, Isgro F, Weisse U, et al. 2005. Advanced sternal closure to prevent dehiscence in obese patients[J]. *Ann Thorac Surg*. 80(4): 1537-1539.
- Kirbas A, Celik S, Gurer O, et al. 2011. Sternal wrapping for the prevention of sternal morbidity in elderly osteoporotic patients undergoing median sternotomy[J]. *Tex Heart Inst J*. 38(2): 132-136.
- Liang M, Liu J, Miao Q, et al. 2018. Use of freeze-dried bone allografts in osteoporotic patients undergoing median sternotomy[J]. *Cell Tissue Bank*. 19(1): 27-33.
- Loladze G, Kuehnel RU, Claus T, et al. 2017. Double-Wire versus Single-Wire Sternal Closure in Obese Patients: a Randomized Prospective Study[J]. *Thorac Cardiovasc Surg*. 65(4): 332-337.
- Losanoff JE, Basson MD, Gruber SA, et al. 2007. Single wire versus double wire loops for median sternotomy closure: experimental biomechanical study using a human cadaveric model[J]. *Ann Thorac Surg*. 84(4): 1288-1293.
- Milano CA, Kesler K, Archibald N, et al. 1995. Mediastinitis after coronary artery bypass graft surgery. Risk factors and long-term survival[J]. *Circulation*. 92(8): 2245-2251.
- Muehrcke DD, Shimp WM, Aponte-Lopez R. 2009. Calcium phosphate cements improve bone density when used in osteoporotic sternums[J]. *Ann Thorac Surg*. 88(5):1658-1661.
- Narang S, Banerjee A, Satsangi DK, et al. 2009. Sternal weave in high-risk patients to prevent noninfective sternal dehiscence[J]. *Asian Cardiovasc Thorac Ann*. 17(2): 167-170.
- Nenna A, Nappi F, Dougal J, et al. 2019. Sternal wound closure in the current era: the need of a tailored approach[J]. *Gen Thorac Cardiovasc Surg*. 67(11): 907-916.
- Nezafati P, Shomali A, Kahrom M, et al. 2019. ZipFix Versus Conventional Sternal Closure: One-Year Follow-Up[J]. *Heart Lung Circ*. 28(3): 443-449.

- Nooh E, Griesbach C, Rosch J, et al. 2021. Development of a new sternal dehiscence prediction scale for decision making in sternal closure techniques after cardiac surgery[J]. *J Cardiothorac Surg.* 16(1): 174.
- Robicsek F, Fokin A, Cook J, et al. 2000. Sternal instability after midline sternotomy[J]. *Thorac Cardiovasc Surg.* 48(1): 1-8.
- Schimmer C, Sommer SP, Bensch M, et al. 2008. Sternal closure techniques and postoperative sternal wound complications in elderly patients[J]. *Eur J Cardiothorac Surg.* 34(1): 132-138.
- Shafi A, Abuelgasim E, Abuelgasim B, et al. 2021. Sternal closure with single compared with double or figure of 8 wires in obese patients following cardiac surgery: A systematic review and meta-analysis[J]. *J Card Surg.* 36(3): 1072-1082.
- Sharma R, Puri D, Panigrahi BP, et al. 2004. A modified parasternal wire technique for prevention and treatment of sternal dehiscence[J]. *Ann Thorac Surg.* 77(1): 210-213.
- Song DH, Lohman RF, Renucci JD, et al. 2004. Primary sternal plating in high-risk patients prevents mediastinitis[J]. *Eur J Cardiothorac Surg.* 26(2): 367-372.
- Tam DY, Nedadur R, Yu M, et al. 2018. Rigid Plate Fixation Versus Wire Cerclage for Sternotomy After Cardiac Surgery: A Meta-Analysis[J]. *Ann Thorac Surg.* 106(1): 298-304.
- Wade SW, Strader C, Fitzpatrick LA, et al. 2014. Estimating prevalence of osteoporosis: examples from industrialized countries[J]. *Arch Osteoporos.* 9: 182.