

Complete Thoracoscopic Resection of Left Ventricular Myxoma – A Case Report

Gang Li, MM,¹ Jian Wang, MD,² Zhi-Ping Liu, MM,² Yi-Ri Du, MD,³ Ze-Xiang Tian, MM²

¹Inner Mongolia Medical University, Hohhot, China;

²Cardiac And Vascular Surgery, The Affiliated Hospital of Inner Mongolia Medical University, Hohhot, China;

³Department of Anesthesia, The Affiliated Hospital of Inner Mongolia Medical University, Hohhot, China

ABSTRACT

Cardiac myxoma is a common cardiac tumor. Most are found in the left cardiac system, of which 75% of myxomas are located in the left atrium [Pinede 2001], and the origin of the left ventricle is relatively rare. Surgical resection is the most effective method for the treatment of myxoma, but because of the complex anatomy of the left ventricle, most of the reported cases are performed through the traditional median thoracotomy through the ascending aorta and vena cava to establish cardiopulmonary bypass. It is rare to establish cardiopulmonary bypass through the femoral artery and femoral vein to remove left ventricular myxoma under complete video-assisted thoracoscopy. This paper reports the surgical process and perioperative echocardiographic, magnetic resonance, radiological and pathological features of a completely thoracoscopic resection of left ventricular myxoma.

CASE PRESENTATION

A 68-year-old woman was admitted to the hospital, complaining of dyspnea after activity. She had no history of cardiac disease, but a previous history of hypertension for five years. In inpatient physical examination, the patient's HR was 68 beats/min, and the BP was 140/80 mmHg. Grade II-III systolic murmur could be heard in the mitral valve auscultation area. Coronary computed tomography angiography (CCTA) and cardiac magnetic resonance imaging (CMRI) revealed a hypointense mass in the left ventricle. (Figure 1) Transesophageal echocardiography revealed strong echo masses in the left ventricle and moderate mitral regurgitation. The size of the mass was about 1.5 cm × 1.2 cm with a broader range of motion.

As a multidisciplinary decision and at the request of the patient and family members, complete thoracoscopic removal of the mass was planned.

The operation was performed through thoracoscopic assistance. The patient was placed in the supine position and turned 20 degrees to the left. Three surgical incisions were created in the mid-axillary line between the third intercostal space and in the anterior axillary line between the fourth and fifth intercostal spaces. A disadvantage of small surgical incisions is the limited exposure to the surgical area. The use of full video-assisted thoracoscopy overcomes this problem [Tang 2020]. The establishment of extracorporeal circulation through the femoral artery and femoral vein, the right femoral artery (18F), and the femoral vein (26F) were cannulated. After blocking the ascending aorta, stopping fluid and myocardial protective fluid were instilled through the aortic root cannula. To rule out possible atrial myxoma, the right and left atria should carefully be explored during ventricular myxoma surgery. Therefore, we considered the right atrium incision first, through the atrial septum, left atrium, and mitral valve to remove the tumor. This method simultaneously can explore the left and right atrium. If the surgical approach is difficult to remove the tumor, we try to use the aortic incision or left ventricular incision. After cardiac arrest, the right atrium and atrial septum were incised, and no tumor was found in the left or right atrium. The mitral valve was suspended, both the 1.5cm of fragile myxoma and the attached portion of the stalk clearly were visualized through the mitral valve and easily excised en masse from the left ventricle. The mass was seen to be located in the anterolateral wall of the left ventricle, which was consistent with pre-surgical imaging. (Figure 2)

After complete removal of the mass, the atrial septum and right atrium sequentially were sutured, and the patient was weaned from cardiopulmonary bypass. The resected mass was about 1.5cm × 1.0cm in size, brown and tremeloid mass, and deep red blood clots could be seen inside. (Figure 3) In pathology, with myxoid areas and thrombus organization, it eventually was diagnosed as myxoma. (Figure 4)

This patient recovered well and was discharged from the hospital on the seventh postoperative day. A transthoracic echocardiogram showed no evidence of residual mass or mitral valve abnormality one month after surgery.

The patient gave informed consent to the procedure and allowed the use of her surgical images.

DISCUSSION

Myxoma is the most common cardiac tumor but left ventricular myxoma is rare. Most patients find myxoma because

Received March 13, 2022; received in revised form March 26, 2022; accepted March 28, 2022.

Correspondence: Jian Wang, MD, Cardiac and Vascular Surgery, The Affiliated Hospital of Inner Mongolia Medical University, Hohhot, China, 010000 (e-mail: 15396607@qq.com).

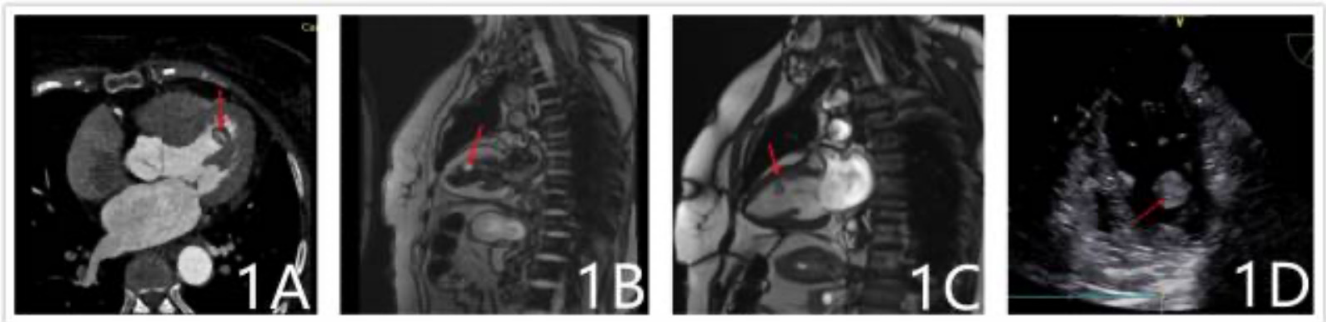


Figure 1. Imageology. A) Coronary computed tomography angiography demonstrated the mass was hypointense (diameter 1.5x1.2 mm), and a hyperintense vascular shadow can be seen; B) Cardiac magnetic resonance imaging demonstrating it was hyperintense on T1 sequences; C) Hypointense on T2 sequences; D) Transesophageal echocardiography reveals strong echo masses in the left ventricle and moderate mitral regurgitation.

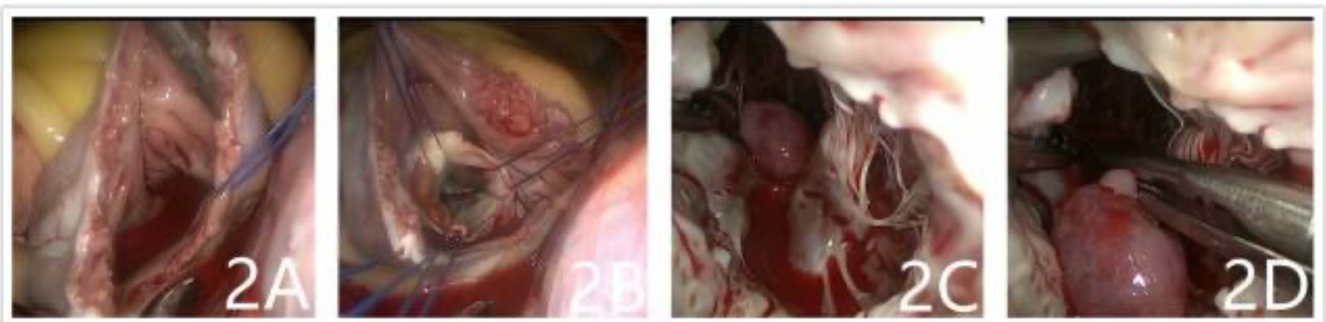

Figure 2. Surgical act. A) After the cutdown of the right atrium; B) Atrial septum; C) The mass can be seen in the anterior wall of the left ventricle; D) Complete excision of the mass.

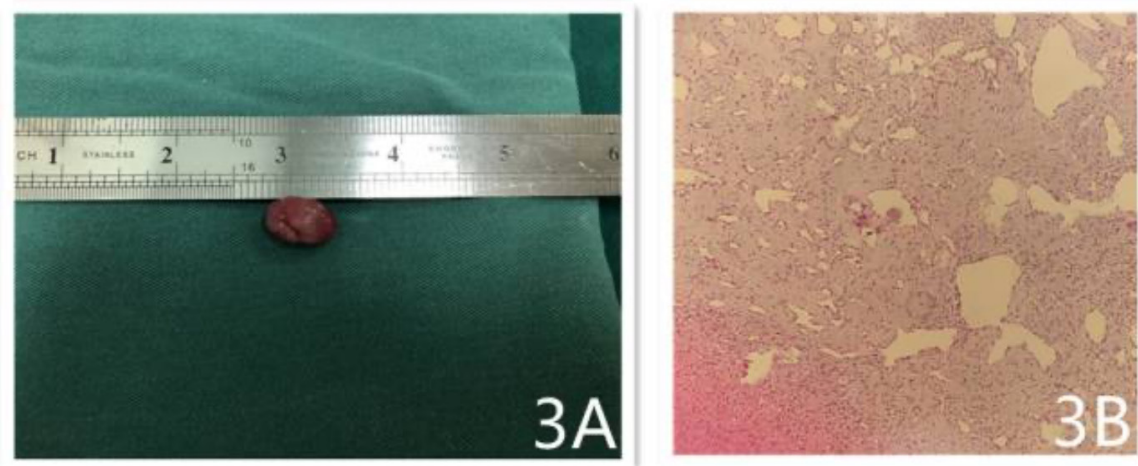


Figure 3. The mass is ovoid, it was about 1.5cm × 1.0cm in size, brown and tremelloid, brittle and friable, and deep red blood clots could be seen inside.

of symptoms of embolism in a limb or vital organ [Acebo 2003]. At the same time, there are reports that myxoma should be included in the differential diagnosis when diagnosing symptoms that resemble left ventricular outflow obstruction [Vásquez 2007]. As with other tumors, early diagnosis of myxoma is important. Smaller mucinous tumors in early stages are easier to treat and cause fewer effects on the patient.

However, myxoma is difficult to detect in the early stages because it lacks specific symptoms. In this case, the patient was seen for dyspnea and a mucinous tumor was detected by transthoracic echocardiography. Considering the possibility of serious complications of cardiac tumors, whenever a patient presents with heart-related symptoms, transthoracic echocardiography should be used for differential diagnosis.

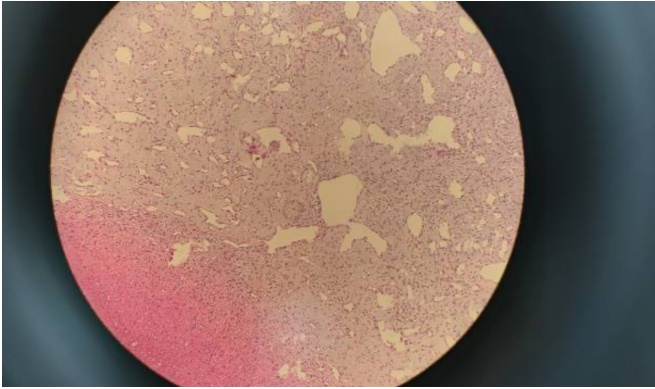


Figure 4. Hystology. The tumor cells were irregularly shaped or asteroidal, surrounded by a hollow halo, scattered, with a loose interstitium, and rich in eosinophilic blue material, as seen in the 20× microscopic image. The tumor cells were surrounded by vascular mechanization.

Correctly performed transthoracic echocardiography can detect the presence of a lesion in the heart cavity with 100% efficiency [Konka 2003]. But specific details of the procedure and what to expect during the procedure can be gained from CMRI or CCTA. Surgery currently is the treatment of choice for cardiac myxoma, and most resections for left ventricular myxoma are performed with a full median sternotomy and conventional extracorporeal circulation. However, because

of the special location of the left ventricular myxoma, care should be taken not to damage the mitral valve structure while avoiding recurrence when removing the left ventricular myxoma. With the gradual maturation of thoracoscopic surgery technology, it becomes the better choice. Thoracoscopic surgery allows for more careful handling, while reducing subsidiary injury and complications associated with the procedure. This procedure deserves further promotion to reduce the pain and financial burden on patients.

REFERENCES

- Acebo E, Val-Bernal, et al. 2003. Clinicopathologic Study and DNA Analysis of 37 Cardiac Myxomas. *Chest*. 123(5):1379-1379.
- Konka M, Sitko T, Szajewski T, Hoffman P. 2003. Sluzak drogi odpływu prawej komory. *Kardiologia Pol.*
- Pinede L, Duhaut P, Loire R. 2001. Clinical presentation of left atrial cardiac myxoma. A series of 112 consecutive cases. *Medicine (Baltimore)*. 80(3):159-72.
- Tang Y, Li J, Zhao F, Chen T. 2020. Total thoracoscopic surgery for biatrial cardiac myxoma: a case report. *Ann Transl Med*. 8(23):1608.
- Vasquez JC, Rosales E, Dueñas R, et al. 2007. A Large Pediculated Myxoma of the Left Ventricle Causing Outflow Obstruction in a Young Man. *J Am Soc Echocardiogr*. 20(12):1413.e1-1413.e3.