

Dealing with a Septal Hematoma after Switch Operation with Ventricular Septal Defect Closure

Steven Jacobs, Filip Rega, Dirk Vlasselaers, Marc Gewillig, Bart Meyns

Departments of Cardiac Surgery and Pediatric Cardiology, University Hospitals Leuven, Leuven, Belgium



Dr. Jacobs

ABSTRACT

We report the case of a 7-day-old boy who underwent operation for transposition of the great arteries with a ventricular septal defect. An intraseptal hematoma occurred postoperatively. Because of the rarity of this complication, the optimal strategy for treating this problem is not known. We opted for a conservative approach. In the "Discussion," we elaborate on the existing literature.

CASE REPORT

A 7-day-old boy was referred to our hospital with the diagnosis of transposition of the great arteries (TGA) complicated with a large ventricular septal defect (VSD). The pregnancy had been unremarkable. Prenatal ultrasound studies showed no anomalies.

The child was born after 41 weeks of gestation. The Apgar scores at 1 and 5 minutes after childbirth were 7 and 7, respectively. Because of respiratory and circulatory problems, the boy was intubated and ventilated. An echocardiography evaluation showed a complex transposition of the great arteries. A Rashkind procedure was performed. The ductus arteriosus was kept patent with an intravenous infusion of alprostadil (Prostin VR®, 0.005 µg/kg per minute; Pfizer, New York, NY, USA).

On admission in our hospital, the boy weighed 3.7 kg. An echocardiography evaluation confirmed a TGA and a perimembranous VSD with a diameter of 5 mm and a moderate shunt, mainly from right to left. The patient underwent an arterial switch procedure with patch closure of the VSD on day 7. The procedure was performed with the use of cardiopulmonary bypass (CPB) and moderate hypothermia. The patient was easily weaned from CPB with low-dose inotropes, and he was in sinus rhythm. Because of the low birth weight, a transesophageal echocardiography examination could not be performed.

Received October 26, 2009; accepted February 2, 2010.

Correspondence: Filip Rega, University Hospitals Leuven, Department of Cardiac Surgery, Herestraat 49, B-3000 Leuven, Belgium; +32-16344260; fax: +32-16344616 (e-mail: filiprega@uzleuven.be).

Upon arrival in the intensive care unit, the patient went into circulatory shock. An emergency echocardiography evaluation showed a large ventricular septal hematoma (Figure 1) with left ventricular dysfunction. We stabilized the baby and decided not to reintervene. Our patient remained stable for the following days. The evolution of the hematoma was followed by echocardiography. Soon after the operation, a third-degree atrioventricular block with an escape rhythm of 60 beats/min developed, for which temporary pacing was started and a permanent epicardial pacemaker was implanted later. The hematoma regressed spontaneously over the following weeks (Figure 2).

DISCUSSION

An interventricular septal hematoma is a very rare complication after VSD repair. A literature review in the PubMed database revealed only 5 case reports (6 patients) concerning this kind of complication [Drago 2005; Bernasconi 2007; Jensen 2007; Padalino 2007; Zhuang 2008]. In the non-pediatric population, an interventricular septal hematoma has been described after myocardial infarction, chest trauma,

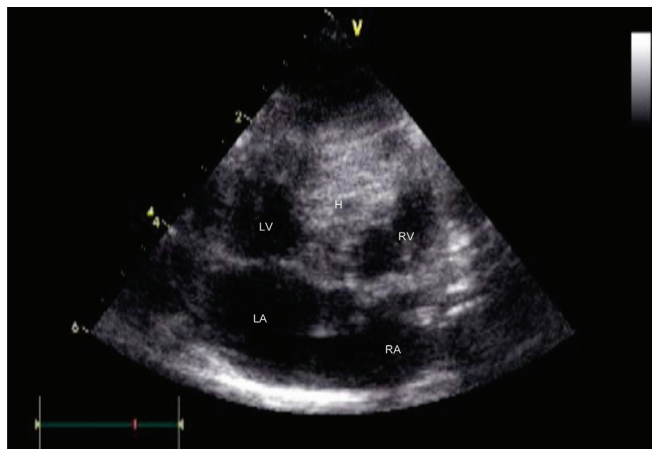

Figure 1. First postoperative images showing a large (20 × 22 mm) basal interventricular septal hematoma obstructing the left ventricle outflow tract. RA indicates right atrium; LA, left atrium; LV, left ventricle; RV, right ventricle; H, interventricular septal hematoma.

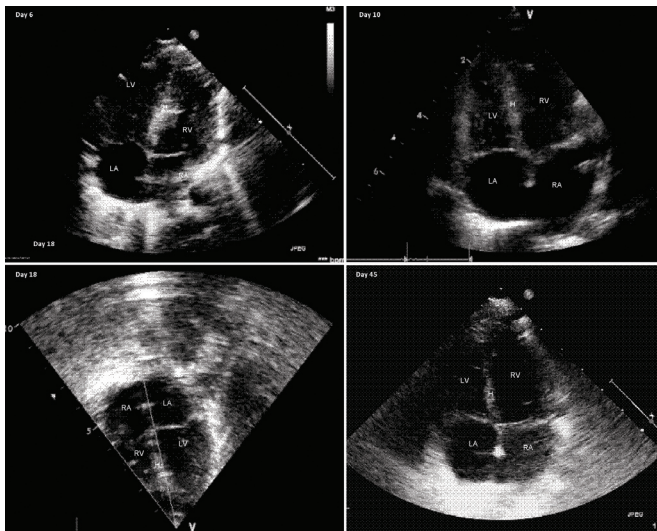


Figure 2. Consecutive images of the hematoma at days 6, 10, 18, and 45 after the operation showing spontaneous regression. RA indicates right atrium; LA, left atrium; LV, left ventricle; RV, right ventricle; H, interventricular septal hematoma.

and coronary artery bypass grafting [Hutchins 1980; Vargas-Barrón 2005]. After VSD repair, the hematoma is iatrogenic and most probably originates from damage to a septal perforator during suturing. One case report suggests spontaneous intraoperative development of a septal hematoma during operative repair of a large atrial septal defect [Bernasconi 2007]. In our case, the hematoma most likely was caused during suturing of the patch. Another possibility is a sting caused by the sharp point of a myocardial thermometer used to monitor the efficacy of cardioplegia administration.

Diagnosis is made easily and quickly by echocardiography. When a hematoma is diagnosed during the perioperative transesophageal echocardiography evaluation, immediate drainage with a needle puncture and ultrasonic guidance can be considered [Padalino 2007]. Because of the patient's low birth weight, no transesophageal echocardiography could be performed. Moreover, the boy was perfectly stable during the closing procedure.

The answer on how to deal with this issue is not obvious. In 2 of the reported cases, prompt reintervention was carried out because of hemodynamic instability, and the hematoma was drained [Drago 2005; Zhuang 2008]. In 3 other cases, a conservative approach was chosen [Bernasconi 2007;

Jensen 2007]. In all 3 of these cases, the septal hematoma regressed spontaneously over the course of subsequent months. Because of the hemodynamic stability of the baby, we also opted for expectant management. Of the 6 cases we found in the literature, only 1 patient died. This death occurred 8 months later, but the patient had a good ventricular function during his last checkup and had no complaints [Zhuang 2008]. The authors stated that his death was probably unrelated to the septal hematoma.

An interventricular septal hematoma can cause ventricular dysfunction but also can give rise to a block of the electrical circuitry of the ventricle, as in our case [Jensen 2007; Padalino 2007].

CONCLUSION

We have reported the case of a 7-day-old boy with an interventricular septal hematoma. We opted for conservative management because of the patient's hemodynamic stability. The outcome was favorable with spontaneous regression of the hematoma. Conservative management seems a good option for dealing with an interventricular septal hematoma.

REFERENCES

- Bernasconi A, Cavalle-Garrido T, Redington A. 2007. Spontaneous intraoperative ventricular haematoma in a neonate. *Heart* 93:898.
- Drago M, Butera G, Giamberti A, Lucente M, Frigiola A. 2005. Interventricular septal hematoma in ventricular septal defect patch closure. *Ann Thorac Surg* 79:1764-5.
- Hutchins GM, Moore GW. 1980. Isolated right atrial tamponade caused by hematoma complicating coronary artery bypass graft surgery. *Arch Pathol Lab Med* 104:612-4.
- Jensen R, Burg P, Anderson C, et al. 2007. Postoperative ventricular septal hematoma: natural history of two pediatric cases. *J Thorac Cardiovasc Surg* 133:1651-2.
- Padalino MA, Speggorin S, Pittarello D, Milanesi O, Stellin G. 2007. Unexpected interventricular septal hematoma after ventricular septal defect closure: intraoperative echocardiographic early detection. *Eur J Echocardiogr* 8:395-7.
- Vargas-Barrón J, Romero-Cárdenas A, et al. 2005. Long-term follow-up of intramyocardial dissecting hematomas complicating acute myocardial infarction. *J Am Soc Echocardiogr* 18:1422.
- Zhuang J, Chen JM, Huang X. 2008. Interventricular septal dissecting haematoma. *Eur Heart J* 29:2488.