

# Non-Invasive Imaging of Sutureless Vein Graft Anastomosis with 16-Slice Multi-detector Row Spiral Computed Tomography

Thomas Strecker,<sup>1</sup> Dieter Ropers,<sup>2</sup> Michael Weyand,<sup>1</sup> Richard Feyrer<sup>1</sup>

<sup>1</sup>Center of Cardiac Surgery; <sup>2</sup>Department of Cardiology, Friedrich-Alexander-University of Erlangen-Nuremberg, Erlangen, Germany

## ABSTRACT

Contrast-enhanced 16-slice multi-detector row spiral computed tomography (MDCT) has been shown to be useful for non-invasive visualization of aortocoronary bypass grafts (CABG). This new-generation scanner could be a good alternative to the common invasive coronary angiography. In this article, we report a patient operated on with the St. Jude Medical, Inc, Symmetry Bypass System (Aortic Connector System [ACS]) and subsequently studied by MDCT.

## CASE REPORT

A 63-year-old caucasian male with double-vessel coronary artery disease was referred to the cardiology department of our hospital. The patient suffered from unstable angina (CCS IV) and dyspnea (NYHA III-IV). At this stage the patient had already two coronary stents in the left anterior descending (LAD) artery and the circumflex coronary artery (CX) and therefore operative revascularization was considered. The angiogram showed an 80-90% stenosis of the LAD and an occlusion of the right coronary artery (RCA). Coronaries were well suited for revascularization. Left ventricular ejection fraction (LVEF) was 60%.

The off-pump technique was chosen for revascularization. After a median sternotomy, the left internal mammary artery (LIMA) was prepared. Following placement of deep pericardial exposure sutures, the beating heart was stabilized with the Genzyme retractor. After left coronary arteriotomy, a 2 mm intraluminal shunt was introduced and the distal anastomosis with the mammary artery was performed with a running 7-0 polypropylene suture.

The saphenous vein was harvested through small incisions, and inspected to determine its adequacy for the device. We tied all the branches to the vein in order not to interfere with the device deployment mechanism. The vein was introduced on the vein transfer sheath and then guided over the release system. The aortic cutter was used to make a hole without clamping the aortic wall, and bleeding from the hole was controlled with a finger. Then the delivery system was inserted into the anastomosis site, and the button was pushed for releasing the struts (Figure 1). Furthermore, we chose to implant the proximal anastomosis on the side, rather than on the top of the aorta, in order to avoid angulations. Finally, the distal anastomosis of the vein to the RCA was completed by using the Genzyme retractor and a running 7-0 polypropylene suture.

At the end of surgery the patient was transferred to the intensive care unit in a stable hemodynamic condition (blood pressure 120/80 mm Hg, heart rate 90/minute in sinus rhythm) with 0.092 mg/kg/minute epinephrine. It was possible to taper and withdraw inotropic support with stable hemodynamic parameters over the following hours. During the next days, the aPTT was adjusted in the range between 40 and 50 seconds. The patient was extubated on the operating day 5 hours after surgery and referred to the floor on day 2. Further postoperative recovery of the patient was uneventful. Before the patient left the hospital on postoperative day 14, echocardiography showed a normal LV function with an EF of 60% and good contractility of all areas. Postoperatively the patient received 100 mg aspirin permanent and 75 mg clopidogrel for 6 weeks.

Fourteen months after the operation a new contrast-enhanced 16-slice MDCT scanner (Siemens Sensation Cardiac, Germany, 12 × .75-mm collimation, gantry rotation time 420 milliseconds, table feed 2.8 mm per rotation, tube voltage of 120 KV) with retrospective ECG-gated image reconstruction has been shown to permit non-invasive visualization of coronary arteries and bypasses. The MDCT showed no significant stenoses in both bypass grafts (to the LAD and to the RCA) as well as in the mechanical proximal vein graft anastomosis. Patency of the LIMA and the vein graft was evidenced by complete filling of both bypass conduits. MDCT clearly demonstrated the star-shaped,

Received June 2, 2005; received in revised form June 17, 2005; accepted June 21, 2005.

Address correspondence and reprint requests to: Dr. Thomas Strecker, Center of Cardiac Surgery, Friedrich-Alexander-University of Erlangen-Nuremberg, Krankenhausstr. 12, D-91054 Erlangen, Germany; 49 9131 853 3985; fax: 49 9131 853 2768 (e-mail: [thomas.strecker@berz.imed.uni-erlangen.de](mailto:thomas.strecker@berz.imed.uni-erlangen.de)).

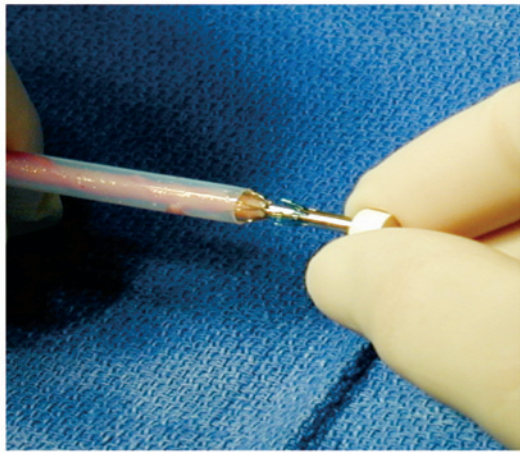
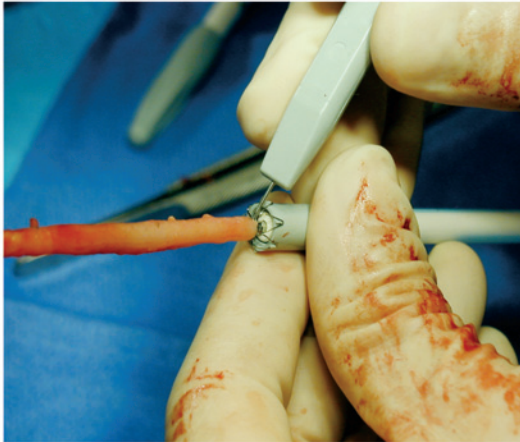


Figure 1. St. Jude aortic connector system for proximal vein anastomosis.

proximal aorto-venous bypass connector (Figure 2). There were little hardening artifacts surrounding the proximal connector.

## DISCUSSION

The St. Jude Medical aortic connector system was easy to handle and allowed quick creation of a reliable sutureless proximal vein graft anastomosis. In the reported case the anastomosis could be done without any clamping of the aorta. This is of special interest for OPCAB procedures, because aortic manipulation and therefore the risks of embolism and aortic dissection would be further minimized (Eckstein 2002, Hornik 2003). In another study aortic connector patients showed an increased incidence of early cardiac mortality, myocardial infarction or increased requirement for early revascularization of a previous target vessel and were predominantly in non-insulin-dependent diabetics (Dewey 2004). Furthermore, a Scandinavian working group present data where saphenous vein grafts anastomosed to the aorta with the connector system showed significant more occlusions or abnormalities related to the device than in

grafts with a traditional suture technique (Bergsland 2004). In this context the comments has to be added to the fact that graft occlusion can also put down to several other reasons like vein graft quality, angulations or performance of the distal anastomosis.

With significant and extremely fast technical improvements, non-invasive cardiac imaging has become a focal point in the diagnosis of cardiac disease. Thereby, the newly developed 16-slice row spiral MDCT with intravenous contrast injection and ECG-correlated image reconstruction has been shown to allow the visualization of coronary arteries and bypass grafts concerning calcifications, significant stenoses, and coronary plaques. The combination of multi-detector rows with sub-millimeter collimation and fast gantry rotation together with simultaneous acquisition of the ECG signal for retrospectively ECG-gated allows for imaging the heart, coronary arteries, and bypass grafts with high spatial temporal resolution. Due to an extremely high sensitivity for the detection of calcified structures, cardiac CT allows the depiction and quantification for coronary calcium. Furthermore, after intravenous injection of contrast agent, cardiac CT has been demonstrated to visualize the coronary artery lumen as a non-invasive coronary angiography. This could be a good alternative to conventional invasive cardiac catheterization (Ropers 2003, 2004, Zhang 2004). This and other studies have shown that MDCT of the new generation allows for accurate assessment of venous and arterial conduits in patients with previous aortocoronary bypass grafts with a high degree of sensitivity and specificity (Hoffmann 2004, Martuscelli 2004).

In conclusion, the aortovenous bypass connector is a simple, user-friendly, effective, quick, and reliable device for performing the proximal aortic anastomosis without the

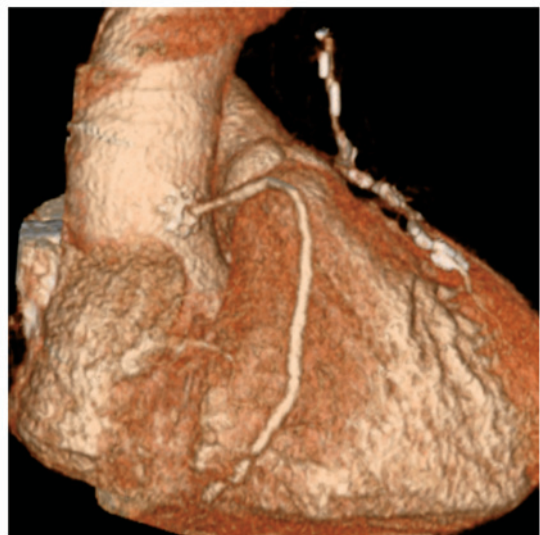


Figure 2. Visualization of the bypass grafts to the LAD and to the RCA as well as the mechanical proximal vein graft anastomosis by 16-slice row spiral multi-detector computed tomography (MDCT) reconstruction orthogonal to the vessel in the reference segment.

need for clamping the aorta. This system represents a further step to reduce manipulation of the aorta with the potential risk of embolization. Nevertheless, other studies point out, the new anastomotic device should not be introduced in routine coronary surgery until further controlled studies have been performed.

Clinically, cardiac CT can be helpful in the investigation of patients with coronary artery disease. The 16-slice row spiral MDCT has been shown to reliably permit assessment of coronary bypass grafts for patency versus occlusion and for the presence of stenoses in the body of the grafts. Furthermore, CT imaging permits reliable visualization and assessment of anastomoses with proximal aortic connectors.

## REFERENCES

- Bergsland J, Hol PK, Lingas PS, et al. 2004. Intraoperative and intermediate-term angiographic results of coronary artery bypass surgery with symmetry proximal anastomotic device. *J Thorac Cardiovasc Surg* 128:718-23.
- Dewey TM, Crumrine K, Herbert MA, et al. 2004. First-year outcomes of beating heart coronary artery bypass grafting using proximal mechanical connectors. *Ann Thorac Surg* 77:1542-9.
- Eckstein FS, Bonilla LF, Englberger L, et al. 2002. First clinical results with a new mechanical connector for distal coronary artery anastomoses in CABG. *Circulation* 106:1-4.
- Hoffmann U, Moselewski F, Cury RC, et al. 2004. Predictive value of 16-slice multidetector spiral computed tomography to detect significant obstructive coronary artery disease in patients at high risk for coronary artery disease: patient-versus segment-based analysis. *Circulation* 110:2638-43.
- Hornik L, Tenderich G, Minami K, et al. 2003. First experience with the St. Jude Medical, Inc, Symmetry Bypass System (Aortic Connector System). *J Thorac Cardiovasc Surg* 125:414-7.
- Martuscelli E, Romagnoli A, D'Eliseo A, et al. 2004. Evaluation of venous and arterial conduit patency by 16-slice spiral computed tomography. *Circulation* 110:3234-8.
- Ropers D, Baum U, Pohle K, et al. 2003. Detection of coronary artery stenoses with thin-slice multi-detector row spiral computed tomography and multiplanar reconstruction. *Circulation* 107:664-6.
- Ropers D, Regenfus M, Wasmeier G, Achenbach S. 2004. Non interventional cardiac diagnostics: computed tomography, magnetic resonance, real-time three-dimensional echocardiography. *Minerva Cardioangiol* 52:407-17.
- Zhang ZH, Jin ZY, Li DJ, et al. 2004. Non-invasive imaging of coronary artery with 16-slice spiral computed tomography. *Chin Med Sci J* 19:174-9.