

# A Giant Ascending Aortic Aneurysm Compressed the Left Main Bronchus and Esophagus: A Case Report

Shaofeng Yang, MD,<sup>1</sup> Shengqiang Zhang, MD,<sup>1</sup> Ge Liu, MD,<sup>1</sup> Yiyao Jiang, MD,<sup>1,2</sup> Chao Shi, MD<sup>1</sup>

<sup>1</sup>Department of Cardiovascular Surgery, First Affiliated Hospital of Bengbu Medical College, Bengbu, Anhui, China;

<sup>2</sup>Nankai University, Tianjin, China

## ABSTRACT

We report a 39-year-old Chinese man with a giant ascending aortic aneurysm that compressed the left main bronchus and esophagus. Cabrol procedure was successfully performed. The symptoms of dry cough, dysphagia, chest tightness, and asthma disappeared. Without any complications, the patient was discharged home.

## INTRODUCTION

The giant ascending aortic aneurysm has many clinical symptoms, among which compression is a typical manifestation. At the same time, the dissection of the aortic root also leads to the specificity of the surgical method for ascending aortic aneurysms. Here, we describe one case with the application of “Cabrol procedure” for a giant ascending aortic aneurysm with compression symptoms in the bronchus and esophagus.

## CASE PRESENTATION

A male patient, 39 years old, was admitted to our department due to the chief complaint of chest tightness, asthma, dry cough, and a choking feeling after eating for half a year. Computed tomography angiography (CTA) examination of the aorta revealed a true aneurysm of the ascending aorta with compression of the left main bronchus and middle segment of the esophagus. (Figure 1) Color Doppler examination of the heart showed that the aortic sinus was 63mm, ascending aorta was 95mm, aortic valve ring was 26mm, aortic regurgitation was large, left ventricular end-diastolic diameter was 68mm, and left ventricular ejection fraction was 60%.

Received September 4, 2021; accepted September 27, 2021

Correspondence: Yiyao Jiang, MD, Department of Cardiovascular Surgery, First Affiliated Hospital of Bengbu Medical College, Bengbu, Anhui 233004, China; Nankai University, Tianjin 300071, China; and Chao Shi, MD, Department of Cardiovascular Surgery, First Affiliated Hospital of Bengbu Medical College, Bengbu, Anhui 233004, China (e-mails: [jiangyiyao0309@sina.com](mailto:jiangyiyao0309@sina.com), [wuweisichao@126.com](mailto:wuweisichao@126.com)).

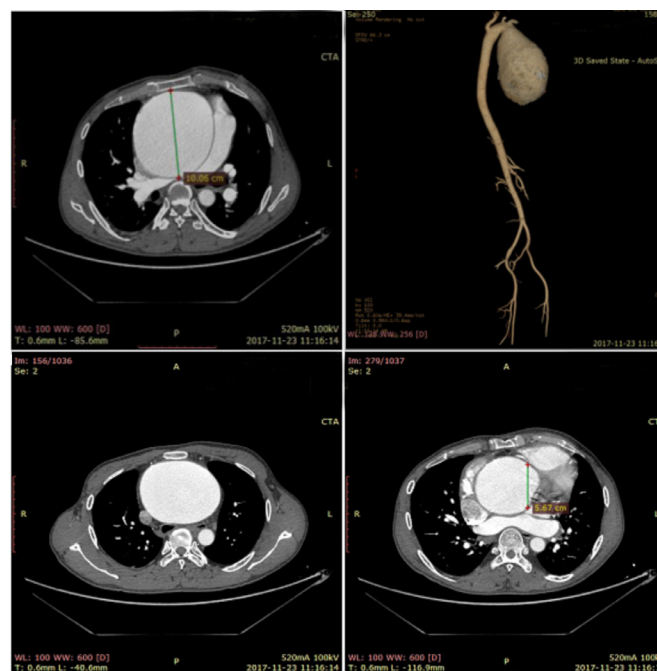


Figure 1. CTA of aorta

Surgical treatment was performed after medical therapy. The ascending aortic aneurysm intraoperatively was observed with severe dilatation of the aortic sinus, with a diameter of about 10cm, and a diameter of about 8cm above the sinus junction. During the operation, we found the distance between the opening position of the coronary artery and the aortic valve was less than 1.5cm. Considering the risk of tearing and bleeding of conventional coronary artery transplantation, Cabrol surgery was adopted. SJM25 aortic valve tube and Telmaw 8mm artificial vessel were selected, and both ends were anastomosed with the left and right coronary artery openings, respectively. Then, the artificial vessels were anastomosed with the aortic valve tube. After the operation, the patient had a persistent dry cough and decreased respiratory sounds in the left lung. The reason was bronchi softening by the aneurysm compression. For him, dissolving phlegm and relieving cough were applied to prevent from atelectasis and pulmonary infection. The patient was discharged home in the following 10 days. Postoperative CTA examination of the whole aorta showed normal

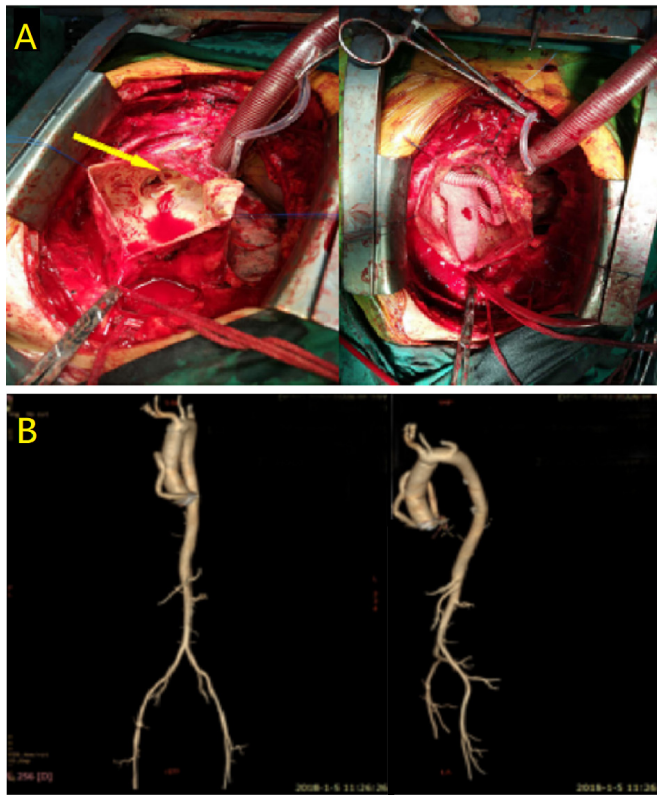


Figure 2. Intraoperative (A) and postoperative CTA examination (B)

morphology of the aortic sinus and ascending aorta. (Figure 2) The symptoms of dry cough, dysphagia, chest tightness, and asthma disappeared.

## DISCUSSION

Generally, it is considered that aortic diameter dilatation or bulge greater than 50% of normal artery diameter is called aneurysm. Among thoracic aortic aneurysm, ascending aortic aneurysm is the most common, followed by the main artery root aneurysm, descending thoracic aortic aneurysm and arch aneurysm [Sampson 2014]. In the diagnosis of aortic aneurysms, echocardiography is the most convenient. The widened mediastinum shadow is found in chest X-rays. These findings should be highly suspected of aortic broadening, extend the thoracic aortic aneurysms. Full-phase retrospective ECG-gated CT angiography can diagnose aortic aneurysm accurately and quickly [Yanagaki 2020].

Compression symptoms of thoracic aortic aneurysm are common. Most patients in the early stage lack specific clinical symptoms. They seek medical advice, when symptoms caused by the gradual compression of peripheral blood vessels, nerves, and lumen structures are more obvious. The key to the treatment of an aortic aneurysm depends on its size. When the diameter of the ascending aorta or the diameter of the sinus is greater than or equal to 5.5cm, surgical treatment should be performed; if the diameter growth rate of

the ascending aortic aneurysm exceeds 0.5cm/year, even if the diameter is less than 5.5cm, surgical treatment should be performed [Erbel 2014]. Due to severe dilation of the aortic sinus and obvious displacement of the coronary sinus opening, the patient chose the Cabrol surgery. Among thoracic aortic aneurysms that compress the main bronchus, descending aortic aneurysms account for the majority, and some patients received endotracheal stent treatment due to tracheomalacia [Reed 2012; Chen 2019]. Considering that the compression time was short and tracheomalacia symptoms were mild, the patient in this case did not receive endotracheal stent treatment, and the patient did not complain of cough and postural dyspnea after surgical treatment.

Among aortic root procedures, Cabrol can be used to perform coronary artery grafts without injury or increased tension, but the risk of thrombosis and distortion of artificial vessels has limited clinical application [Porterie 2020]. Therefore, there are many modified Cabrol methods in clinical practice. For example, superficial femoral artery transplantation also is a good choice for graft selection [Guenther 2020]. By lengthening the length of the artificial vessel, a larger curve was added to prevent the distortion of the artificial vessel, and a good effect was achieved [Tanaka 2020]. Cabrol has a smaller indication for aortic root surgery, but it is a better choice for surgeons, when appropriate.

Ascending aortic aneurysm has a variety of clinical manifestations, among which compression symptoms also are of high diagnostic value, especially unexplained dry cough, dysphagia. Aortic CTA can be diagnosed in time. There are many surgical methods for the treatment of ascending aortic aneurysm, and the specific surgical methods should be selected, according to the different conditions of the patient's aorta.

## ACKNOWLEDGEMENT

This work was supported by grants from the National Natural Science Foundation of China (81800214), Natural Science Foundation of Anhui Province (1808085QH236), Excellent Young Talents Fund Program of Higher Education Institutions of Anhui Province (gxyqZD2016167), Key Research and Development Projects of Anhui Province (1804h08020280), and Key project of translational medicine of Bengbu Medical College (BYTM2019041).

## REFERENCES

- Chen WC, Tu CY, Liang SJ, et al. 2009. Metallic stents for rescuing a patient with severe upper airway compression due to aortic aneurysm. *Am J Emerg Med.* 27: 256.e1-4.
- Erbel R, Aboyans V, Boileau C, et al. 2014. 2014 ESC Guidelines on the diagnosis and treatment of aortic diseases: Document covering acute and chronic aortic diseases of the thoracic and abdominal aorta of the adult. The Task Force for the Diagnosis and Treatment of Aortic Diseases of the European Society of Cardiology (ESC). *Eur Heart J.* 35: 2873-926.
- Guenther TM, Godoy L, Chen SA, et al. 2020. Homograft aortic root replacement with modified Cabrol extension using cryopreserved femoral

- artery for bioprosthetic aortic valve endocarditis. *JTCVS Tech.* 4: 65-67.
- Porterie J, Kalavrouziotis D, Mohammadi S. 2020. Commentary: Biologic mustache for the modified Cabrol technique. *JTCVS Tech.* 4:68-69.
- Reed AB, Reed MF. 2012. Endobronchial and Endovascular Management of Bronchial Compression by a Thoracic Aortic Aneurysm. *Ann Thorac Surg.* 94: 273-74.
- Sampson UK, Norman PE, Fowkes FG, et al. 2014. Global and regional burden of aortic dissection and aneurysms: mortality trends in 21 world regions, 1990 to 2010. *Glob Heart.* 9: 171-180.e10.
- Tanaka A, Al-Rstum Z, Zhou N, et al. 2020. Feasibility and Durability of the Modified Cabrol Coronary Artery Reattachment Technique. *Ann Thorac Surg.* 110: 1847-1853.
- Yanagaki S, Ueda T, Masuda A, et al. 2020. Detection of the intimal tear in aortic dissection and ulcer-like projection in intramural hematoma: usefulness of full-phase retrospective ECG-gated CT angiography. *Jpn J Radiol.* 38: 1036-1045.