

Pulmonary Artery Sling with Tracheal Stenosis Combined with A Large Ventricular Septal Defect in A Two-Month-Old Boy: A Case Report

Yi Zhang,¹ Yongjun Qian²

¹Anesthesia Operation Center of West China Hospital/West China School of Nursing, Sichuan University, Chengdu, Sichuan, People's Republic of China; ²Department of Cardiovascular Surgery, West China Hospital, Sichuan University, Chengdu, Sichuan, China

ABSTRACT

Pulmonary artery sling (PAS) is a rare congenital cardiovascular abnormality. In typical PAS patients, the left pulmonary artery (LPA) arises from the right pulmonary artery and passes between the trachea and esophagus, which possibly causes tracheal stenosis and some respiratory symptoms. PAS typically associates with other cardiovascular anomalies, which may cause difficulties to the treatment of patients. This report described a rare case of a two-month-old boy with PAS, VSD, and tracheal stenosis simultaneously and underwent procedures without tracheoplasty.

INTRODUCTION

Pulmonary artery sling (PAS) is a rare congenital cardiovascular anomaly, in which the left pulmonary artery (LPA) typically arises from the posterior part right pulmonary artery (RPA) instead of pulmonary trunk, and the abnormal LPA passes leftward between the esophagus and trachea [Potts 1954]. PAS patients have a higher incidence rate of congenital tracheal stenosis (CTS) than patients with other cardiovascular anomalies [Speggorin 2012; Chao 2016], and PAS patients with long-segment tracheal stenosis remained challenging, despite improved outcomes for PAS repair with left pulmonary artery reimplantation [Oshima 2008]. Two reasons possibly lead to this condition. The ligamentum arteriosum of PAS usually arises from the pulmonary trunk to the undersurface of the aortic arch and forms a vascular ring that surrounds the trachea together with the abnormal LPA [Lee 2021]. The exogenous trachea pressure caused by the vascular ring leads to some respiratory symptoms [Hong 2015]. Another reason may be the presence of complete cartilage ring, which is found in nearly 65% PAS patients [Hraska 2009]. Complete rings are O-shaped, compared with C-shaped normal cartilage rings and more easily cause diffuse tracheal stenosis. For patients with PAS in addition

to severe tracheal stenosis, operation includes LPA reimplantation and tracheoplasty [Fiore 2005], which can both correct cardiovascular deformity and solve the stenosis of trachea. However, recent conservative treatment of tracheal stenosis is reported valid [Lueck 2020].

PAS is associated with other cardiovascular abnormalities [Fiore 2005] like patent ductus arteriosus (PDA), atrial septal defect (ASD), ventricular septal defect (VSD), and double aortic arch (DAA). Combining with other anomalies may lead to special change of hemodynamics, which has vital influence to clinical manifestation and surgical decision of PAS patients. To our knowledge, few case reports described patients with PAS in addition to a large VSD who underwent LPA reimplantation without tracheoplasty [Matsumoto 2019]. This case report describes possible thoughts and methods of treatment for these kinds of patients.

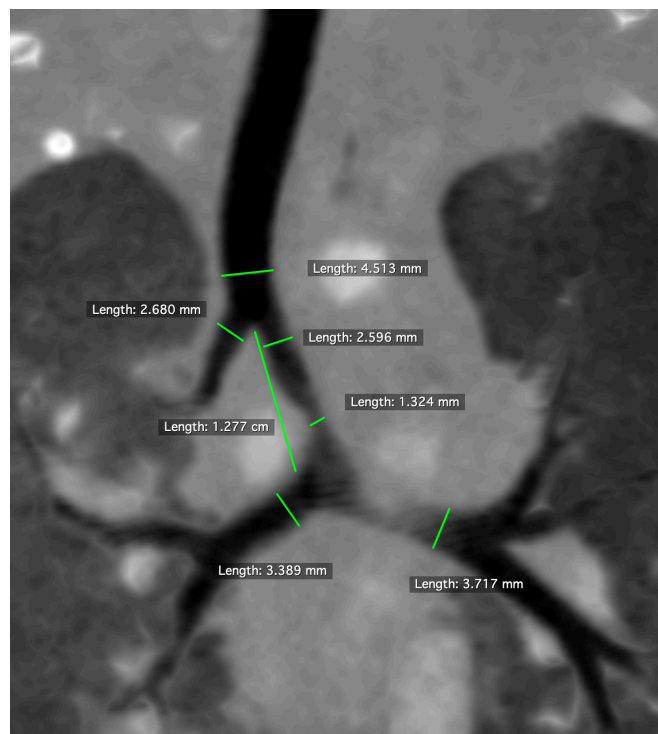

Figure 1. Axial view of computed tomography demonstrated the stenosis of trachea by specific value.

Received August 23, 2021; received in revised form October 21, 2021; accepted October 21, 2021.

Correspondence: Yongjun Qian, No. 37 GuoXue Xiang, Chengdu, Sichuan, 610041, People's Republic of China; +86-28-85422897; fax: +86-28-85422897 (e-mail: qianyongjun@scu.edu.cn).

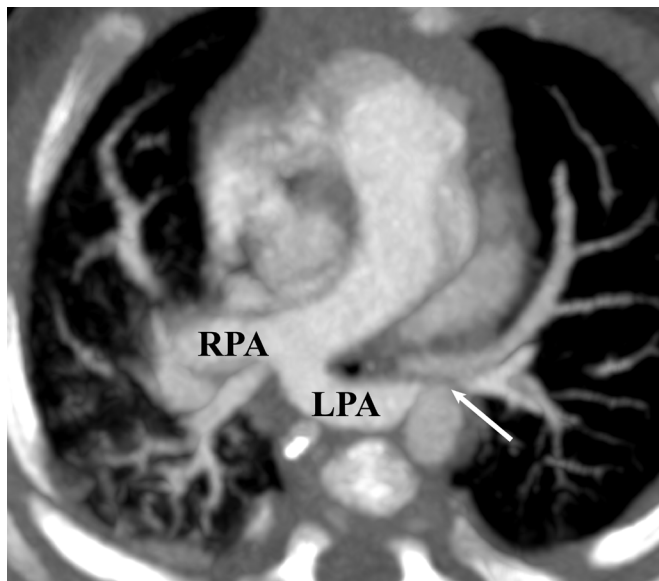


Figure 2. Chest computed tomography showed a typical imaging feature of pulmonary artery sling including pulmonary artery sling with an abnormal origin crossed between the esophagus and the main trachea and a small inner diameter of left pulmonary artery (arrow). (LPA, left pulmonary artery; RPA, right pulmonary artery)

CASE REPORT

A two-month-old boy was found to have a heart murmur in the child care clinic. In order to accept further diagnosis and treatment, the child was referred to our hospital. The child was known to have inspiratory dyspnea and a little poor feeding for a week. Physical examination revealed a normal growth level, while retraction signs of three fossae was found. On further investigation, electronic bronchoscope demonstrated an obvious stenosis in both the left and right main bronchus, in which distal bronchi cannot be seen by the bronchoscopy with external diameter of 3.1mm. Axial view of computed tomography (CT) demonstrated the stenosis more clearly and correct the result of electronic bronchoscope (Figure 1). The dominating stenosis was found in the main trachea with the 1.324mm inner diameter, which was identified as left main bronchus by bronchoscopy. In fact, neither left nor right main bronchus showed a significant stenosis, the narrow right main bronchus identified by bronchoscopy actually was an abnormal bronchus with a blind end that originated from the main trachea, which is named “tracheal bronchus” in many studies. Chest CT showed a typical imaging feature of PAS including LPA with an abnormal origin crossed between the esophagus and the main trachea and a small inner diameter of LPA (Figure 2). A large defect (perimembranous VSD, 1cm) at ventricular level was found on CT image, which was considered the reason for the heart murmur. CT three-dimensional reconstruction also demonstrated that LPA abnormally originated from RPA (Figure 3).

Given the clinical features and radiological findings, a one-stage operation was carried out, including VSD closure and LPA reimplantation. Most surgeons thought the dyspnea and

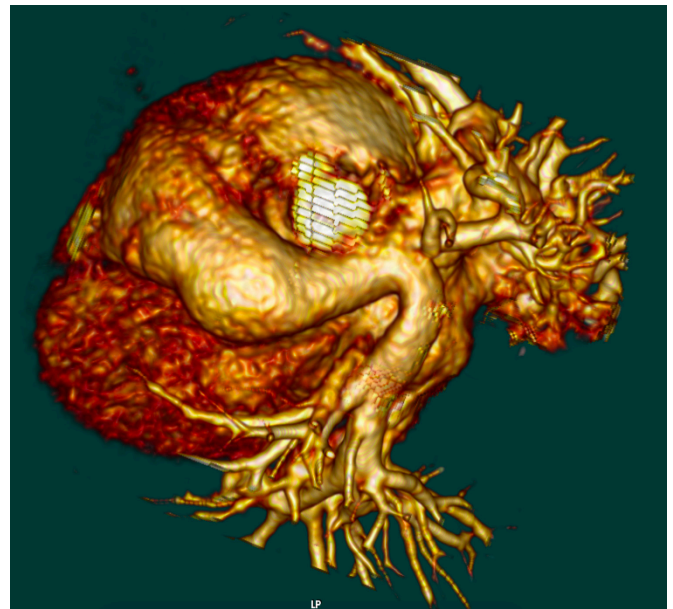


Figure 3. Computed tomography three-dimensional reconstruction demonstrated left pulmonary artery abnormally originated from right pulmonary artery.

high pulmonary artery pressure were aggravated by the large VSD, when the defect was closed, the clinical syndrome may relieve significantly. It means the stenosis of trachea could be temporary functional stenosis caused by VSD. Tracheoplasty was not used on the patient after deep discussion by surgeons. Postoperatively, the transesophageal echocardiography showed no residual shunting at the ventricular level. The boy was stable during the immediate postoperative period with no dyspnea, and he recovered uneventfully and was discharged from the hospital.

DISCUSSION

VSD is the most common cardiovascular anomaly in newborns. Patients with isolated VSD usually have a left to right shunt at the ventricular level of the heart, which can lead to an increase of blood volume in the right ventricular outflow tract and pulmonary artery. Because of high pulmonary resistance at birth, the left to right shunt is not obvious, and sometimes no symptoms can be seen. The pulmonary resistance decreases in the next few weeks, thus symptoms associated with heart failure and respiratory dysfunction appear. This explains why inspiratory dyspnea was found when the child was nearly two months old, rather than at birth.

Management of pulmonary artery sling with tracheal stenosis exists with controversy. While reimplantation of LPA has been considered a safe and efficient method to correct abnormal LPA, the problem is whether those patients must undergo tracheoplasty. Sometimes, surgeons are concerned about tracheal restenosis caused by post-tracheoplasty anastomotic

scar hyperplasia, which is much more difficult to cure than primary stenosis [Yong 2013]. It also is reported that tracheoplasty may result in dangerous outcomes like death or other complex complications [Li 2017]. Some research has shown that isolated reimplantation of LPA [Hong 2015] or conservative treatment like temporary tracheal stenting [Leuck 2020] may achieve satisfactory effects. On the other hand, as techniques of tracheal surgery improve, survival outcomes seem improved for patients who undergo these procedures. Some study reported that slide tracheoplasty could reduce the mortality rate of such patients [Manning 2011; Butler 2014]. It is reported that CTS could be divided into three types, according to clinical symptoms and CT images: mild, moderate, and severe [Antón-Pacheco 2006]. Some cases and studies reported that PAS with mild CTS should be treated by LPA reimplantation without tracheoplasty [van Son 1999], while combined operation of these two procedures is recommended in PAS with moderate or severe CTS [Oshima 2002; Torun 2021]. For the child described in this case, because of high pressure in the pulmonary artery caused by VSD, symptoms of tracheal stenosis would exacerbate. The anatomic stenosis was not as severe as imagined. It should be noted that dyspnea may be caused by the functional stenosis, which comes from PAS and VSD mainly, thus decisions based on symptoms and CT images is not precious. Tracheoplasty was not carried out in this patient for reasons that surgeons believed tracheoplasty would not benefit the child, and the tracheal stenosis may automatically be relieved after curing PAS and VSD. Postoperative outcomes confirmed this opinion. It still is necessary and meaningful for researchers to find the best operation choice for these kinds of patients.

REFERENCES

- Antón-Pacheco JL, Cano I, Comas J, et al. 2006. Management of congenital tracheal stenosis in infancy. *Eur J Cardiothorac Surg* 29: 991-996.
- Butler CR, Speggorin S, Rijnberg FM, et al. 2014. Outcomes of slide tracheoplasty in 101 children: a 17-year single center experience. *J Thorac Cardiovasc Surg* 147:1783-9.
- Chao YC, Peng CC, Lee KS, et al. 2016. The association of congenital tracheobronchial stenosis and cardiovascular anomalies. *Int J Pediatr Otorhinolaryngol* 83: 1-6.
- Fiore AC, Brown JW, Weber TR, et al. 2005. Surgical treatment of pulmonary artery sling and tracheal stenosis. *Ann Thorac Surg* 79: 38-46.
- Hong X, Zhou G, Liu Y, et al. 2015. Management of pulmonary artery sling with tracheal stenosis: LPA re-implantation without tracheoplasty. *Int J Clin Exp Med* 8: 2741-2747.
- Hraska V, Photiadis J, Haun C. et al. 2009. Pulmonary artery sling with tracheal stenosis. *Multimed Man Cardiothorac Surg. MMCTS 2009: mmcts.2008.003343.*
- Lee M, Landsem L. 2021. Pulmonary Artery Sling. *StatPearls* [Internet] 31.
- Li D, Feng Y, Hirata Y, et al. 2017. Sling Pulmonary Artery with Bridging Bronchus and Narrowing Airway: A Case Report. *Ann Thorac Cardiovasc Surg* 23: 265-267.
- Lueck S, Mohr M, Werner C, et al. 2020. Temporary Tracheal Stenting After Pulmonary Artery Sling Repair in a Newborn. *World J Pediatr Congenit Heart Surg* 11: Np69-np71.
- Manning PB, Rutter MJ, Lisek A, et al. 2011. One slide fits all: the versatility of slide tracheoplasty with cardiopulmonary bypass support for airway reconstruction in children. *J Thorac Cardiovasc Surg* 141:155-61.
- Matsumoto Y, Kamada M, Nakagawa N, et al. 2019. Double vascular ring: a case report of double aortic arch and concurrent pulmonary artery sling. *Eur Heart J Case Rep* 1:3(2).
- Oshima Y, Yamaguchi M, Yoshimura N, et al. 2002. Primary repair of pulmonary artery sling with double outlet right ventricle and distal tracheal stenosis. *J Cardiovasc Surg* 43: 849-851.
- Oshima Y, Yamaguchi M, Yoshimura N, et al. 2008. Management of pulmonary artery sling associated with tracheal stenosis. *Ann Thorac Surg* 86:1334-1338.
- Potts W J, Holinger P H, Rosenblum A H, et al. 1954. Anomalous left pulmonary artery causing obstruction to right main bronchus: report of a case. *J Am Med Assoc* 155:1409-1411.
- Speggorin S, Torre M, Roebuck D J, McLaren, et al. 2012. A new morphologic classification of congenital tracheobronchial stenosis. *Ann Thorac Surg* 93: 958-961.
- Torun EG, Yazici MU, Azapagasi E, et al. 2021. A Case of Pulmonary Artery Sling Anomaly with Tracheal Stenosis and Management of Difficult Airway. *J Pediatr Intensive Care* 10(3), 235-239.
- van Son JA, Hamsch J, Haas GS, Schneider P, and Mohr FW. 1999. Pulmonary artery sling: reimplantation versus antetracheal translocation. *Ann Thorac Surg* 68: 989-994.
- Yong M S, Zhu M Z L, Bell D, et al. 2019. Long-term outcomes of surgery for pulmonary artery sling in children. *Eur J Cardiothorac Surg*.