

A New Understanding for Preoperative Management in a Patient with Blunt Brachiocephalic Trunk Injury

Lei Wang,¹ Hong-mei Wang,¹ Dai-peng Zhou,² Yan-fei Xia,² Kai Kang²

¹Department of Anesthesiology, Pinghu First People's Hospital, Zhejiang, China

²Department of Anesthesiology, Zhejiang Hospital, Hangzhou, Zhejiang, China

ABSTRACT

We report a case of a 24-year-old male patient with blunt brachiocephalic trunk injury, who was given low-dose dexmedetomidine (DEX) for 2 weeks to help smoothly pass the preparation period before the recanalization operation. Because the patient's vital signs were stable after the injury, the surgeon did not perform emergency surgery. Taking into account the characteristics of blunt brachiocephalic trunk injury, it is necessary to avoid damage to or even rupture of brachiocephalic trunk resulting from irritability and high blood pressure. Patients should be sedated to avoid hemodynamic fluctuations that may be caused by cerebral ischemia and restlessness, and based on the patient's neurological symptoms, prevention or treatment of perioperative neurocognitive disorders (PNDs) cannot be ignored. Therefore, the choice of drugs for bridging the preoperative preparation stage is crucial. DEX is an α_2 -adrenergic receptor agonist with antianxiety, analgesic, and sedative effects. It can also stabilize hemodynamics, regulate neuroinflammation, and provide neuroprotection. Instead of using either β -adrenergic receptor antagonists or sedatives, the patient received only low-dose DEX during preoperative preparation. DEX achieved the effects of β -adrenergic receptor blockers, vasodilators, and other sedatives, and it also had certain benefits for the patient's PND. In short, based on our understanding of the relevant physiological factors, risk factors of brachiocephalic trunk injury, and the effects of DEX, low-dose DEX provides a good option for preoperative management in a patient with blunt brachiocephalic trunk injury.

BACKGROUND

Compared with blunt thoracic aorta injury, blunt brachiocephalic trunk injury has certain differentiating characteristics. This kind of extracranial blood vessel obstruction causes important changes in intracranial circulation that

cause different degrees of focal neurological symptoms. It is foreseeable and understandable in the short term that the decrease in cerebral blood flow will cause restlessness, insomnia, and even perioperative neurocognitive disorder (PND). Therefore, for patients who have not undergone emergency surgery, in choosing drugs for the bridging strategy during the preoperative preparation stage, we must consider not only the blunt thoracic aorta injury, but also the characteristics of blunt brachiocephalic trunk injuries. It is necessary to achieve a stable hemodynamic effect to avoid the risk of hypertension rupture, increased hypotension, and cerebral ischemia caused by sharp fluctuations in blood pressure; patients also need sedation to assist with sleep to prevent hemodynamic fluctuations caused by restless emotional stress. Moreover, cognitive function must be supported to prevent or treat PND.

Dexmedetomidine (DEX), an α_2 -adrenergic receptor agonist, has been widely used in clinical anesthesia and intensive care unit (ICU) sedation. In addition to antianxiety, analgesic, and sedative effects [Shan 2018], low-dose DEX could lower blood pressure and slow heart rate by inhibiting the conduction of sympathetic nerves and increasing the activity of vagus nerves. Therefore, a stable hemodynamic effect can be achieved during continuous intravenous (IV) infusion [Bloor 1992]. In addition to these effects, promising experiments and results raise the possibility that DEX could be used as a preventive pharmacological tool for PND [Lee 2019].

CASE PRESENTATION

A 24-year-old male patient was transferred to our hospital for chest trauma. There was a significant difference in blood pressure between his 2 sides: the right upper limb had lower blood pressure, 70/35 to 85/40 mmHg, and the left upper limb had higher blood pressure, 140/85 to 165/115 mmHg. Computed tomography angiography (CTA) of chest revealed that the brachiocephalic trunk artery was invisible (Figure 1). Electrocardiogram (ECG) monitoring revealed sinus tachycardia and a ventricular rate of 135 to 150 beats per minute. Meanwhile, the patient was irritated and anxious and had symptoms of PND. He was emotionally unstable, sometimes indifferent, and lacked interest in external reactions, which manifested as inattention when the doctor and family members asked questions. The patient sometimes showed strong aggressiveness and some inappropriate behavior and speech. He had difficulty falling asleep and occasionally felt chest pain.

Received February 16, 2021; received in revised form March 8, 2021; accepted March 15, 2021.

Correspondence: Kai Kang, Department of Anesthesiology, Zhejiang Hospital, No. 1229 Gudun Road, Hangzhou 310030, Zhejiang, China; 86-0571-81595068 (e-mail: 739550819@qq.com).

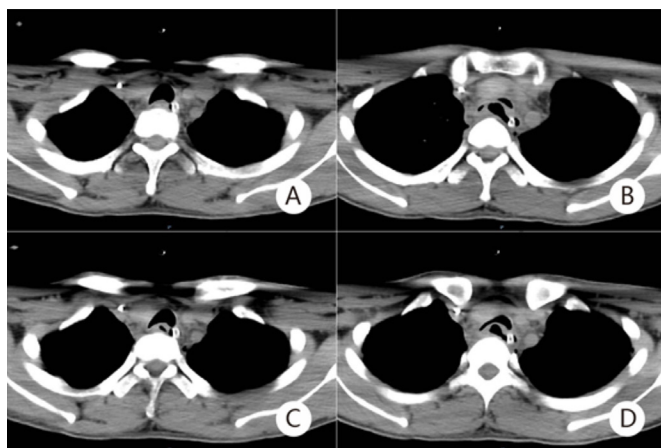


Figure 1. CTA of chest.

Because of the decision to delay surgery, the patient received continuous IV infusion of low-dose DEX as a bridging strategy in the preoperative preparation stage to give the patient sedation, relieve anxiety, stabilize mood, improve sleep, control blood pressure, and maintain stable hemodynamics. During the 2-week preparation, the patient was given a nasal oxygen catheter (2 L/min), and 0.3 $\mu\text{g}/\text{kg}/\text{h}$ DEX IV was continuously administered. The patient experienced satisfactory sedative effect: level 2 to 3 according to the Ramsay sedation scale. With the significant extension of sleep time (improved to 6 to 7 hours per night) and the control of blood pressure, the patient's PND symptoms also improved. We observed that the patient's mood was stable, and no further aggressiveness was shown.

Left upper limb blood pressure was measured once every 30 minutes, controlled at 100/55 to 125/80 mmHg. Other monitoring included continuous bedside ECG to control heart rate at 60 to 100 beats per minute and daily observation for 5P symptoms (pain, pallor, paresthesia, paralysis, and pulselessness) in the right upper limb. Monitoring continued until the day of surgery. The patient received surgical recanalization of the brachiocephalic trunk artery 2 weeks after trauma. He recovered uneventfully and was discharged 12 days after surgery.

DISCUSSION

Traumatic blunt thoracic aortic injury is rare and is traditionally regarded as a surgical emergency. However, the occurrence of simple blunt brachiocephalic trunk injury after trauma is even rarer (and rarely reported). In our case, the surgeons decided that because the patient had just suffered trauma and was in the high-incidence period of inflammatory response, the tissue around the brachiocephalic trunk was edema and exudation. Based on the fatality and disability rates of emergency surgery [Chen 2015], surgery may have been detrimental to the patient at that time. Although the patient had symptoms of anxiety, restlessness, night insomnia and dreams, and even PND, his overall condition was relatively

stable, and CTA images indicated no signs of pseudoaneurysm formation or rupture. Given the benefits of delayed surgery and comprehensive judgment [Akhmerov 2019; Di Eusano 2013], the surgeons chose nonoperative treatment first and waited 2 weeks for surgery.

Traditionally, nonoperative treatment uses β -adrenergic receptor blockers and supplements with vasodilators when necessary [Brinkman 2007]. Other guiding principles in related reports include antiplatelet therapy or anticoagulation therapy if the patient can tolerate it [Starnes 2012] or has a focal neurological event [Neri 2004]. In combination with the characteristics of blunt brachiocephalic trunk injury and the consideration of PND, it is not enough to choose simple β -adrenergic receptor blockers (such as metoprolol) and vasodilators (such as sodium nitroprusside and calcium-channel blockers). Also necessary are sedatives to relieve anxiety and aid sleep, and even other drugs to maintain stable hemodynamics and treat or prevent PND.

Because the patient had not been cared in the ICU, the selection of suitable sedatives (such as benzodiazepines or propofol) was a challenge involving the influence on respiration and circulation, as well as the relationship between sedatives and PND. Benzodiazepines are not recommended for patients with PND [Fan 2017], and prolonged IV infusion of propofol carries the risk of hypotension, further aggravating ischemia and possibly respiratory depression. Thus, as anesthesiologists, we considered DEX, a sedative that may simultaneously have the effects of β -adrenergic receptor antagonists, sedatives, and even vasodilators. It not only produces stable hemodynamic effects during continuous infusion, but it also has certain benefits for patients with PND or who may develop PND.

An α_2 -adrenergic receptor agonist with antianxiety, analgesic, and sedative effects, DEX has no significant inhibition on respiration [Keating 2015]. The infusion time of DEX has been extended from <24 hours to >24 hours [Gunter 2010], so it is widely used in clinical anesthesia and ICU sedation [Fan 2017]. In addition to sedation and analgesia, DEX produces a typical biphasic hemodynamic effect: that is, DEX produces hypotension at low doses and increases blood pressure at high doses [Keating 2015]. Previous research [Bloor 1992] also stated that low-dose DEX can act on the presynaptic α_2 receptor, inhibiting the release of norepinephrine, thereby inhibiting the conduction of the sympathetic nerves, which can increase the excitability of the vagus nerve and lead to a decline in blood pressure and heart rate. Therefore, stable hemodynamic effects can be produced during continuous IV infusion of DEX. For the patient with blunt brachiocephalic trunk injury, β -adrenergic receptor antagonists, other sedatives, and even vasodilators alone cannot meet these requirements.

As for the problem of PND during the perioperative period, according to extensive research in ICU settings, patients treated with DEX suffer significantly less PND than patients treated with propofol [Djaiani 2016] or midazolam [Riker 2009]. A recent study pointed out that neuroinflammation is a putative target for the prevention and treatment of PND [Saxena 2019]. In both preclinical and clinical trials,

DEX has the effect of modulating neuroinflammation and providing neuroprotection [Gao 2019]. These studies and results expand the practicability of DEX as a preventive and therapeutic strategy for PND [Lee 2019]. In fact, our patient's PND symptoms were relieved and improved within a few days of DEX administration. Therefore, continuous IV infusion of low-dose DEX not only achieves the effects of β -adrenergic receptor blockers, other sedatives, and even vasodilators, but also maintains stable hemodynamics and even benefits for PND in patients with blunt brachiocephalic trunk injury.

CONCLUSIONS

We report a case of a 24-year-old male patient with blunt brachiocephalic trunk injury, who was given low-dose dexmedetomidine for 2 weeks to help smoothly pass the preparation period before the recirculation operation. Based on our understanding of the relevant physiology, risk factors of brachiocephalic trunk injury, and effects of DEX, low-dose DEX may be a good choice for preoperative management in a patient with blunt brachiocephalic trunk injury.

ACKNOWLEDGMENTS

The authors appreciate the understanding of the patient and the support of the cardiac surgeon.

REFERENCES

- Akhmerov A, DuBose J, Azizzadeh A. Blunt thoracic aortic injury: Current therapies, outcomes, and challenges. *Ann Vasc Dis* 2019;12:1-5.
- Bloor BC, Ward DS, Belleville JP, et al. Effects of intravenous dexmedetomidine in humans. II. Hemodynamic changes. *Anesthesiology* 1992;77:1134-1142.
- Brinkman WT, Szeto WY, Bavaria JE. Overview of great vessel trauma. *Thorac Surg Clin* 2007;17:95-108.
- Chen S-W, Wang S-Y, Liao C-H, et al. Timing of intervention in blunt traumatic aortic injury patients: Open surgical versus endovascular repair. *Ann Vasc Surg* 2015;8:1559-1566.
- Di Eusanio M, Folesani G, Berretta P, et al. Delayed management of blunt traumatic aortic injury: Open surgical versus endovascular repair. *Ann Thorac Surg* 2013;95:1591-1597.
- Djaiani G, Silverton N, Fedorko L, et al. Dexmedetomidine versus propofol sedation reduces delirium after cardiac surgery: A randomized controlled trial. *Anesthesiology* 2016;124:362-368.
- Fan H, Zhao Y, Sun M, et al. Dexmedetomidine based sedation for post-surgery critically ill adults: A meta-analysis of randomized controlled trials. *Iran J Public Health* 2017;46:1611-1622.
- Gao J, Sun Z, Xiao Z, et al. Dexmedetomidine modulates neuroinflammation and improves outcome via α 2-adrenergic receptor signaling after rat spinal cord injury. *Br J Anaesth* 2019;123:827-838.
- Guinter JR, Kristeller JL. Prolonged infusions of dexmedetomidine in critically ill patients. *Am J Health Syst Pharm* 2010;67:1246-1253.
- Keating GM. Dexmedetomidine: A review of its use for sedation in the intensive care setting. *Drugs* 2015;75:1119-1130.
- Lee S. Dexmedetomidine: Present and future directions. *Korean J Anesthesiol* 2019;72:323-330.
- Neri E, Sani G, Massetti M, et al. Residual dissection of the brachiocephalic arteries: Significance, management, and long-term outcome. *J Thorac Cardiovasc Surg* 2004;128:303-312.
- Riker RR, Shehabi Y, Bokesch PM, et al. Dexmedetomidine vs midazolam for sedation of critically ill patients: A randomized trial. *JAMA* 2009;301:489-499.
- Saxena S, Lai IK, Li R, et al. Neuroinflammation is a putative target for the prevention and treatment of perioperative neurocognitive disorders. *Br Med Bull* 2019;130:125-135.
- Shan Y, Yang F, Tang Z, et al. Dexmedetomidine ameliorates the neurotoxicity of sevoflurane on the immature brain through the BMP/SMAD signaling pathway. *Front Neurosci* 2018;12:964.
- Starnes BW, Lundgren RS, Gunn M, et al. A new classification scheme for treating blunt aortic injury. *J Vasc Surg* 2012;55:47-54.