

# Interlocking Multi-Twisted Wires Versus Interrupted Simple Sternal Wires for Closure of Median Sternotomy

Faisal Mourad, MD, FRCS, Ihab Ali, MD, FRCS

Cardiothoracic Surgery Department, Faculty of Medicine, Ain Shams University, Cairo, Egypt

## ABSTRACT

**Background:** Although closure of a sternotomy incision is usually a simple procedure, failure to do so (sternal dehiscence) is a serious complication and is an independent factor that poses a high degree of morbidity or mortality after open heart surgery. Instability of the bone fragments can lead to complete sternal breakdown, sternal wound infection, and mediastinitis. The stainless-steel encircling wire used as either interrupted simple sutures or as figure of eight sutures is the current standard method of median sternotomy closure. Interlocking multi-twisted sternal wire closure is an alternative that provides rigid sternal fixation. We aim to identify the best method of sternal closure in order to implement it as a standardised protocol for our department.

**Methods:** Two-hundred patients aged 18-70 years were undergoing cardiac surgeries at Ain Shams University hospitals. They were divided into two groups: Group I included 100 patients with sternal closure using simple wire, and group II included 100 patients with sternal closure using interlocking multi-twisted wires. The day 7, 1 month, and 3 months sternal instability, superficial wound infection, ventilation time, cross-clamp time, length of ICU stay, and length of hospital stay were analyzed.

**Results:** The incidence of sternal instability on the 7th day, 1 month, and 3 months was significantly higher in the simple wire closure group ( $P < 0.05$ ). However, incidence of superficial wound infection, length of ICU stay, and duration of mechanical ventilation were comparable between the two groups.

**Conclusion:** The interlocking multi-twist is a safe, effective, and easily reproducible method for preventing sternal dehiscence.

## INTRODUCTION

Median sternotomy is still considered the gold standard approach for cardiac surgery, due to its unparalleled

exposure of mediastinal and pulmonary hilar structures [Durrleman 2006].

Since its inception as the standard approach for many open-heart operations, wiring, interlocking, plate-screw, and cementation techniques have been examined for sternotomy closure [Julian 1957]. All techniques have their advantages and disadvantages. The ideal sternal closure should ensure stability, reduced rate of postoperative complications, and a short hospitalization period, alongside cost effectiveness [Alhalawani 2013].

The stainless-steel encircling wire used as either interrupted simple sutures or as figure of eight sutures is the current standard method of median sternotomy closure in cardiothoracic operations [Goodman 1986].

Resuming sternal integrity following sternotomy for open heart surgery remains one of the mainstays for an expeditious recovery. Sternal split remains today a significant risk factor with an incidence of dehiscence and infection [Kotnis-Gqska 2018].

Although sternotomy closure is a reasonably straightforward step, it is not without complications. The reported incidence of sternal dehiscence varies from 20% to 25%. If not recognized early, instability of the bone fragments interferes with healing and can lead to complete sternal breakdown, sternal wound infection, and mediastinitis, which are major causes of morbidity and mortality after open heart surgery [Dell'Amore 2018].

Interlocking multi-twisted sternal wire closure has been biomechanically proven to provide a rigid sternal fixation in a simple non-time-consuming fashion [Casha 1999].

In this study, we tried to identify the best method of sternal closure in order to implement it as a standardised protocol for our department.

**Technique:** Simple interrupted wire closure involves placing all wires approximately 1-2 cm from the sternal edge or parasternally. Usually around eight wires are placed: five in the body of the sternum and another three in the manubrium. The two ends of each wire are then hand-twisted under tension, causing sternal edges to come together. An assistant approximates the sternum using the other wires to keep good tension. The resultant two-stranded twisted portions are then bent to lie along the surface of the sternum.

Interlocking multi-twisted sternal wire closure starts in a similar way, where eight wires are placed throughout the manubrium and the body of the sternum. However, in this method, approximation of wires starts by twisting adjacent wire ends. No tension is required at this stage. It is important

Received February 5, 2021; received in revised form March 4, 2021; accepted March 4, 2021.

Correspondence: Prof. Ihab Ali, MD, FRCS, Associate Professor of Cardiothoracic Surgery, Department of Cardiothoracic Surgery, Ain Shams University, Abbaseya Square, Cairo, Egypt (e-mail: [dribababdehrazek@hotmail.com](mailto:dribababdehrazek@hotmail.com)).

to keep the twisted portion of the wires at equal distance from where the wires exit the sternal half. The contralateral ends of the adjacent wires are then twisted under tension to bring the inner table of the two sternal edges together.

The two twisted ends of the wires are then twisted together, further tensioning all portions of the interlocking multi-twisted wires. The resultant four-stranded twisted portion is then bent to lie along the surface of the sternum. Removal of interlocking multi-twisted wires can be achieved by simply cutting the two wires on one side, followed by pulling the central four-stranded portion [Casha 1999]. (Figure 1) (Figure 2) (Figure 3)

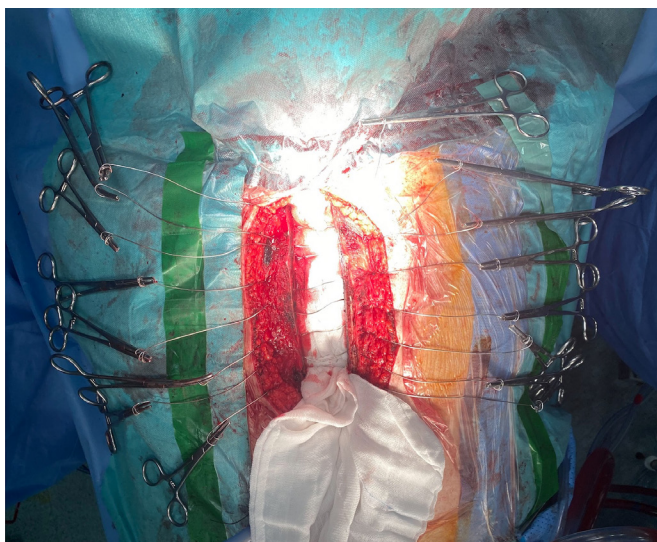


Figure 1. Interlocking multi-twisted wire closure. Placing of wires in manubrium and sternal body

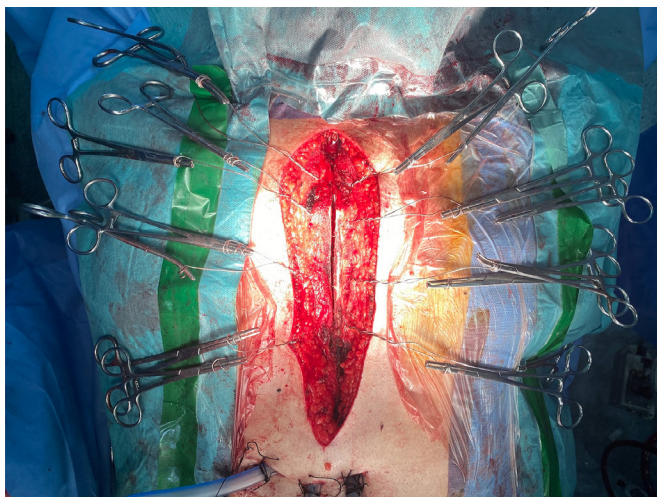


Figure 2. Interlocking multi-twisted wire closure. Twisting of every two ipsilateral ends of adjacent wires under tension with approximation of the sternum

## MATERIALS AND METHODS

**Ethical considerations:** Written informed consent was obtained from all patients before the start of the study. The study was reviewed and approved by the Institutional Review Board of Faculty of Medicine, Ain Shams University (Ain Shams University Protocol Record: FMASU R 71/2020) and was conducted in accordance with the Declaration of Helsinki.

**Patients:** This is a prospective study that included 200 patients, who underwent cardiac surgeries in the Cardiovascular and Thoracic Surgery Academy, Ain Shams University, Cairo, Egypt. The study took place from September 20, 2020 to December 20, 2020.

Patients were divided into two groups. Group I included 100 patients with sternal closure using simple wire. Group II included 100 patients with sternal closure using interlocking multi-twisted wires.

**Inclusion criteria:** Patients who had undergone elective first-time open heart surgery; patient age >18 and <70 years; and all patients had median sternotomy incisions.

Excluded were patients undergoing emergent surgery (defined as life threatening or unstable condition requiring surgery on the same day of the surgical consultation); patients undergoing redo surgery; and those receiving immunosuppressive drugs, prolonged steroids therapy, COPD, chronic cough, CRF, emergency open heart surgery and bilateral mammary artery harvesting.

**Study protocol:** Preoperative preparation involved patients having an antiseptic shower with diluted povidone-iodine and excessive hair in the chest wall removed the day

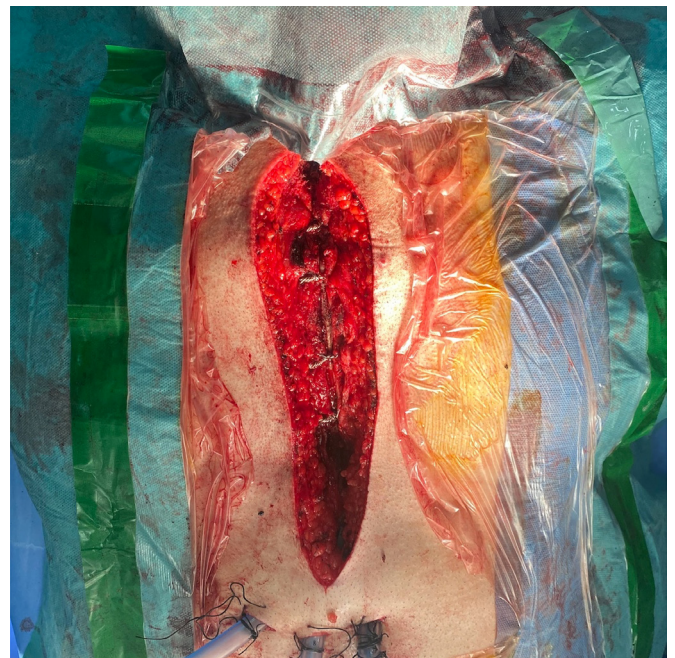

Figure 3. Interlocking multi-twisted wire closure. Opposite twisted ends are twisted together.

before surgery. Also before the skin incision, the patient's skin was disinfected with 10% povidone iodine solution.

**Antibiotic prophylaxis:** All patients received prophylactic antibiotics prior to surgery, according to our hospital infection control protocol (2g of 3rd generation cephalosporin, cefotaxime, two hours before surgery) and similar dose was given during the cardiopulmonary bypass. Additional post-operative doses were given during the ICU stay starting from the first day postoperative.

**The surgical technique:** All patients underwent elective cardiac surgeries via median sternotomy incisions and cardiopulmonary bypass. The sternum was closed using stainless steel wires no "5" and delayed absorbable sutures were used for the subcutaneous tissues. The skin was closed with subcuticular absorbable sutures. All LIMA harvesting for the purpose of this study was using a pedicled LIMA.

**Sternal instability:** Sternal instability was clinically assessed initially and was radiologically confirmed by CT scan and defined as sternal plate separation more than 3mm.

**Group I:** All patients were closed by simple single sutures utilizing the No. 5 stainless steel wire to make 8-10 stitch passes along the length of the sternum. In all patients, three simple wires were used for the manubrium. All wires passed through the sternum 1-1.5 cm from the free edge of the sternal body (transsternal/parasternal). The end of each wire was then closed in the opposite side using horizontal traction to bring the sternal ends close to each other.

Initial hand twisting of all ends was done; it was followed by vertical traction of each loop before the final twisting was done by the stainless-steel needle holder. No more than two-and-a-half times twisting of the wire was used in order to prevent excessive traction and mechanical breakdown.

**Group II:** All patients were closed by No. 5 stainless steel wire in an interlocking multi-twisted-wire fashion. Initial placement of wire sutures is identical to traditional sternal closure. We place all wires approximately 1-1.5 cm from the free sternal edge or parasternally in narrow sternums. Six to eight such wires are placed, four in the body of the sternum and two in the manubrium.

Initial hand twisting of all ends was done followed by vertical traction of each loop before the final twisting was done by the stainless-steel needle holder. It needs to be mentioned that equalization of the wire distance in this technique is very significant in preventing wire dehiscence to equally distribute the tension forces on the sternum. Postoperative follow up took place in the outpatient clinic at 1 and 3 months, with CT scan of the chest.

**Outcome measures:** The primary endpoint of the study was the 7th day/1month/3 months clinical sternal instability, which was radiologically verified using CT scan. The secondary endpoints included superficial wound infection, ventilation time, cross-clamp time, length of ICU stay, and length of hospital stay.

**Statistical analysis, sample size justification:** Sample size was calculated using STATA program, setting the type-1 error ( $\alpha$ ) at 0.05 and the power ( $1-\beta$ ) at 0.8. Results from previous study showed that sternal dehiscence occurred

among 9.3% of the interrupted sternal wire closure group, while among the interlocking multi-twisted group it was 0% [Loop 1990]. Calculation, according to these values, produced a sample size of 93 cases per group after taking in account a 10% drop out rate [Ramzisham 2009].

Statistical presentation and analysis of the present study was conducted, using the mean standard deviation. Unpaired student t-test was used to compare between the two groups in quantitative data. Qualitative data was expressed as frequency (number and percentage) by chi-square test, and multivariate logistic regression was used to adjust the confounding factors using data (IBM SPSS Statistics for Windows, Version 20.0. Armonk, NY: IBM Corp.).

## RESULTS

This study was conducted at the Cardiothoracic Academy from September 2020 to December 2020. A total of 200 patients were assessed for eligibility, and all were enrolled in our study with no single case of protocol violation. They were randomized, and their data were analyzed.

The two groups were matched with regard to age, sex, ejection fraction, and diabetic status. However, BMI was significantly higher in group II ( $P = 0.038$ ). (Table 1)

There was no significant difference between the two groups, in terms of cross-clamp time ( $P = 0.525$ ), length of ICU stay ( $P = 0.186$ ), duration of mechanical ventilation ( $P = 0.487$ ), and postoperative hospital stay ( $P = 0.067$ ). (Table 2)

There was a significant difference between the two groups, with regard to the incidence of sternal instability at day 7 ( $P = 0.030$ ), at 1 month ( $P = 0.014$ ), at 3 months ( $P = 0.015$ ), and sternal gap>3mm in CT ( $P = 0.030$ ), whereas, the incidence of superficial wound infection ( $P = 0.352$ ), wound discharge ( $P = 0.777$ ), and positive cultures retrosternal collection ( $P = 0.052$ ) were comparable. (Table 3)

Table 1. Comparison between the two study groups in terms of patient demographics and preoperative data

	Group I (N = 100)	Group II (N = 100)	Tests	
			t/ $\chi^2$	P-value
Sex				
Female	63(63%)	60(60%)	0.190	0.663
Male	37(37%)	40(40%)		
Age	54.01±7.62	55.10±7.73	1.004	0.317
BMI	33.07±3.65	34.12±3.44	2.092	0.038*
EF%	57.45±5.38	58.86±3.82	1.744	0.083
Diabetes	43(43%)	40(40%)	0.185	0.667

P-values <0.05 were considered statistically significant. BMI, body mass index. EF, ejection fraction

## DISCUSSION

Median sternotomy approach is still considered the golden classic exposure of the heart and the great vessels. The idea of using median sternotomy as an approach to thoracic organs dates as far back as the late 1800s. Nearly a century later, prevention and treatment of its infective complications remains an uneasy challenge for cardiothoracic and plastic surgeons, alike [Loop 1990]. The key factor in preventing sternal dehiscence is a stable sternal approximation until significant bone healing occurs.

Bony union depends on adequate reduction, fixation, and immobilization of the sternum. This relies on several factors: the technique of sternal closure, quality of the material used for sternal closure, and patient factors. Sternal dehiscence is defined as the separation of the bony sternum and is frequently associated with sternal wound infection, most often by *Staphylococcus aureus*. However, sometimes sternal wires can cut through the bone. Wires also can fracture or become untwisted. Glennie and colleagues showed that

twisting a wire more than four times damages it [Glennie 2003; Aykut 2011].

In this study, we describe our experience comparing two techniques of sternal closure: the simple (group I) versus the interlocking multi-twisted wires (group II).

Early diagnosis and treatment of sternum instability may prevent the spread of mediastinitis with its devastating sequelae. Operative treatment varies from simple drainage to extensive myo-cutaneous plastic procedures [El Oakley 1996].

With the small but troublesome risk of simple sternal rocking, further sequelae like sternal non-union (dehiscence with instability) with or without sternal osteomyelitis and superficial or deep wound infection poses additional threats. All techniques for sternotomy closure claim to maximize sternal stability, but it is difficult to scientifically differentiate between the merits of various techniques. Moreover, no median sternotomy closure technique is entirely free of the risk of sternotomy dehiscence [Dasika 2003]. Despite the lack of a significant statistical difference, the studied cohort showed a higher female sex predominance, which is explained

Table 2. Comparison between the two study groups in terms of operative and postoperative data

	Group I (N = 100)	Group II (N = 100)	Tests	
			t/ $\chi^2$	P-value
Cross clamp time (min.)	66.64±10.17	67.56±10.25	0.637	0.525
Length of ICU stay				
≤2 days	59(59%)	68(68%)	1.74	0.186
>2 days	41(41%)	32(32%)		
Duration of mechanical ventilation				
<10 hours	81(81%)	77(77%)	0.482	0.487
≥10 hours	19(19%)	23(23%)		
Postoperative hospital stay				
<10 days	63(63%)	75(75%)	3.366	0.067
≥10 days	37(37%)	25(25%)		

Table 3. Comparison between the two study groups in terms of postoperative results

	Group I (N = 100)	Group II (N = 100)	Chi-square	
			$\chi^2$	P-value
Sternal instability at day 7	17(17%)	7(7%)	4.735	0.030*
Sternal instability at 1 month	20(20%)	8(8%)	5.980	0.014*
Sternal instability at 3 months	17(17%)	6(6%)	5.944	0.015*
Sternum gap CT >3 mm	7(7%)	1(1%)	4.688	0.030*
SWI	7(7%)	4(4%)	0.866	0.352
Wound discharge	45(45%)	47(47%)	0.081	0.777
Positive cultures	13(13%)	8(8%)	1.330	0.249
Retro-sternal collection	8(8%)	2(2%)	3.789	0.052

M, month; SWI, superficial wound infection; mm, millimeters

by the fact that the majority of the cases were rheumatic structural heart disease, which has a more prevailing presence among females [Negi 2020].

In consistence with Abboud, Bitkover and The Parisian Mediastinitis Group, which found that increased BMI increases risk of instability, the results of the present study showed that increased BMI >30 was a significant risk factor for instability in both groups. In group I, the mean body mass index (BMI) was  $33.07 \pm 3.65$ ; in group II, it was  $34.12 \pm 3.44$ . This difference was statistically significant between the two groups ( $P$  value 0.038) [Abboud 2004; Bitkover 2000; The Parisian Mediastinitis Study Group 1996]. This statistical bias was observed due to the tendency of the operating surgeon to use the multi-twist technique for heavier patients as we believed that it would provide a more reliable sternal approximation.

The reported incidence of sternal dehiscence varies from 20%-25% [Olbrecht 2006]. We report a total incidence of 23% of our studied patient cohort at 3 months. Despite being comparable with other reports, we think this is relatively high and it is mainly attributed to our institution being a university teaching hospital and the final steps of the operation is left to the trainees.

In our study, we found that simple interrupted wire was more likely associated with increased sternal instability in patients undergoing median sternotomy. This difference was statistically significant in relation to the choice of sternal closure and its stability in day 7, 30 day, and 3 months post-operatively ( $P$  value 0.030, 0.014, and 0.015, respectively); this was similar with what Losanoff et al. found, where they described that the mechanical instability of peri-sternal single wire closure is significantly greater than that of figure eight peri-sternal and single transsternal closures [Losanoff 2004].

Casha and colleagues calculated that the force generated during coughing is approximately 150 kg, and they recommended that at least six simple interrupted wires should be used for sternal closure so that this force will be shared by all wires [Casha 1999].

We focused on two common techniques of sternal closure. To determine the effectiveness of each technique, one should consider the number of wires used, number of wire twists, strength of each twisted wire, force distribution, and likelihood of each twisted wire to cut through the bone or untwist.

Krejca and colleagues determined the force distribution in sternal wiring and the consequences of sternal closure rigidity between these two techniques. Twenty specimens of each type of suture were prepared. The sternum was studied under increasing tension to determine the plastic limit (appearance of irreversible deformation) and failure load of the suture. Krejca and colleagues stated that correct approximation and distribution of forces at weak points (twisting ends of wires and points where wires pass through the bone) are crucial for the effectiveness of the suture. For straight wire, it is very easy to approximate the sternal edges. They concluded that simple interrupted wires provide good fixation stability for durability of the sternum [Krejca 2003].

The interlocking multi-twist technique has more strength and is less likely to cut the sternum because of an advantageous

redistribution of shearing forces on the wire compared with straight closure. Several other reports also favored this technique because they are less likely to loosen or fracture the sternum, due to an oblique and horizontal angle of shearing forces instead of the direct perpendicular forces in simple interrupted suturing [Shih 2004].

In contrast to Casha and coworkers, who tested several wire closure techniques and found that parasternal simple wires performed best and figure-of-eight wires placed through the sternal bone performed worst, we believe that as in strands of a rope, that twisting increases the strength of the wire. To our minds, the net effect is the twisted wire corresponds to a larger gauge of wire [Casha 1999].

The advantages of the parasternal placement of our wires are multiple and include: 1) tensioning the wires together approximate all parts of the sternal bone altogether at the same time as one unit hence decreasing any possibility of causing any fracture(s) due to undue localization of the traction forces; 2) provides better lateral compression of the sternum, which by virtue of its configuration, results in distribution of the sternal stress over both cortices hence, avoiding wire-cutting through the sternal bone or causing its fracture; 3) provides a better stability to the fractured portions of the sternum and diminishes bleeding from the sternum and marrow; 4) provides better overall security against sternal dehiscence should any of these wires become accidentally broken or untwisted.

In our study, CT chest proved to be an important tool in following up patients with sternal instability, which is similar to what Ramzisham et al. found and started to classify the sternal gap found in x-ray to three groups. These patients were treated conservatively and repeat chest radiography after 3 months showed complete resolution of dehiscence [Ramzisham 2009]. Chest radiography can easily show a mal-positioned wire or cut-through of the wire by the bone fracture [Shih 2004].

In group I, patients with CT positive finding, including a sternal gap of 3mm or more, were found to be 7 (7%). In group II, positive CT finding was observed in one patient (1%). This difference was statistically significant ( $P = 0.030$ ).

The following classification was found to be very useful: type 1, asymptomatic with a mid-sternal strip <3 mm; type 2, mild to moderate sternal pain, rocking sternum, and a mid-sternal strip of 4–10mm with no infection; type 3, severe pain, sunken sternum during breathing, mid-sternal strip 4-10 mm, and mediastinitis [Ramzisham 2009].

The importance of this classification is in determining the patients who can be treated conservatively. For type 1, conservative management may be advocated, and assessment by serial chest radiographs is important to determine whether the dehiscence has resolved. For types 2 and 3, surgical intervention is imperative at the time of diagnosis to reduce the rates of morbidity and mortality. During our research, we found that retrosternal collection proven by CT- chest can be used as an early predictor for sternum instability between the two groups ( $P$  value 0.052), as most of our patients who developed instability in the form of sterile rocking had positive CT finding with retrosternal collection.

**Study limitation:** This is a single-center study with a relatively small sample size.

## CONCLUSION

A vast number of technical innovations have improved sternal closure outcomes, but until now there is no ideal procedure for an effective and robust sternal fixation. The appropriate technique should harmoniously contemplate several requirements, ranging from mechanical properties, operability, reproducibility, and even economical aspects. We believe that the interlocking multi-twist is a safe, effective, and easily reproducible method for preventing sternal dehiscence and will be employed as the routine closure technique in our department.

## REFERENCES

- Aboud CS, Wey SB, Baltar VT. 2004. Risk factors for mediastinitis after cardiac surgery. *Ann Thorac Surg.* 77:676–68.
- Alhalawani AM, Towler MR. 2013. A review of sternal closure techniques. *J Biomater Appl.* 28(4):483-97.
- Aykut K, Celik B, Acikel U. 2011. Figure-of-eight versus prophylactic sternal weave closure of median sternotomy in diabetic obese patients undergoing coronary artery bypass grafting. *Ann Thorac Surg.* 92:638-41.
- Bitkover CY, Marcusson E, Ransjo U. 2000. Spread of coagulase negative staphylococci during cardiac operations in a modern operating room. *Ann Thorac Surg.* 69:1110.
- Casha AR, Yang L, Kay PH, Saleh M, Cooper GJ. 1999. A biomechanical study of median sternotomy closure techniques, *Eur J Cardio-Thorac Surg.* vol. 15 (pg. 365-369).
- Dasika UK, Trumple DR, McGovern JA. 2003. Lower sternal reinforcement improves the stability of sternal closure. *Ann Thorac Surg.* 75:1618.
- Dell'Amore A, Domenica G, Stefano C, Giampiero D, Giacomo M, Sofia M, Niccolò D. 2018. Surgical options to treat massive sternal defect after failed Robicsek procedure. *J Thorac Dis.* 10(6): E410–E415.
- Durrleman N, Massard G. 2006. *Sternotomy. Multimedia Manual Cardio Thorac.*
- El Oakley R, Paul E, Wong PS, Yohana A, Magee P, Walesby R, Wright J. 1996. Mediastinitis in patient undergoing cardiopulmonary bypass: risk analysis and midterm results. *J Cardiovasc Surg.* 38: 595–600.
- Glennie S, Shepherd DET, Jutley RS. 2003. Strength of wired sternotomy closures: effect of number of wire twists. *Interact Cardiovasc Thorac Surg.* 2:3-5.
- Goodman G, Palatianos GM, Bolooki H. 1986. Technique of closure of mediansternotomy with trans-sternal figure-of-eight wires. *J Cardiovasc Surg.* 27:512–3.
- Julian OC, Lopez-Belio M, Dye WS, Javid H, Grove WJ. 1957. The median sternal incision in intracardiac surgery with extracorporeal circulation: a general evaluation of its use in heart surgery. *Surgery.* 42:753–61.
- Kotnis-Gqska A, Piotr M, Aldona O, Andrzej S, Malgorzata, Anetta U. 2018. Original Paper: Sternal wound infections following cardiac surgery and their management: a single-centre study. *Kardiochirurgia Torako-chirurgia Polska.* 15 (2): 79-85.
- Krejca M, Szmagala P, Skarysz J, Bochenek K, Ulczok R, Bis J, et al. 2003. Force distribution in wire sternum sutures: the consequences for sternal closure rigidity. *Med SciMonit.* 9:134–44.
- Loop FD, Lytle BW, Cosgrove DM, Mahfood S, Mc Henry J, Goormastic M, Stewart RW, Golding LA, Taylor PC. 1990. Maxwell Chamberlain memorial paper: Sternal wound complications after isolated coronary artery bypass grafting: early and late mortality, morbidity and cost of care. *Ann Thorac Surg.* 49:179-187.
- Losanoff JE, Richman BW, Jones JW. 2004. Disruption and infection of median sternotomy: a comprehensive review. *Eur J Cardiothorac Surg.* 21:831–9.
- Negi PC, Kandoria A, Asotra S, Kumar G, Merwaha R, Sharma R, Rao S, et al. 2020. Gender differences in the epidemiology of Rheumatic Fever/Rheumatic heart disease (RF/RHD) patient population of hill state of northern India; 9 years prospective hospital based, HP-RHD registry. *Indian heart journal,* 72(6), 552-556.
- Olbrecht VA, Barreiro CJ, Bonde PN, Williams JA, Baumgartner WA, Gott VL, et al. 2006. Clinical outcomes of noninfectious sternal dehiscence after median sternotomy. *Ann Thorac Surg.* 82:902–7.
- Ramzisham M, Awang RR, Mohd GK, Joanna OSM, Abdullah MF, Mohd DZ. 2009. Interrupted Sternal Wire Closure of Median Sternotomy, *Asian Cardiovasc Thorac Ann.* 17:587–91.
- Shih CC, Shih CM, Su YY, Lin SJ. 2004. Potential risk of sternal wires. *European Journal of Cardio-Thoracic Surgery.* 25 :812–818.
- The Parisian Mediastinitis Study Group. 1996. Risk factors for deep sternal wound infection after sternotomy: a prospective, multicenter study. *J Thorac Cardiovasc Surg.* Jun;111(6):1200-7.