

## Triple Coronary Bypass in a Child with Homozygous Familial Hypercholesterolemia

Mehmet Salih Bilal, MD, Prof, Numan Ali Aydemir, MD, Nihat Cine, MD, Ahmet Celebi, MD, Assoc. Prof, Mehmet Kaplan, MD, Assoc. Prof

Siyami Ersek Thoracic and Cardiovascular Surgery Training and Research Hospital, Istanbul, Turkey

### ABSTRACT

Here we report triple coronary bypass procedure in a 12-year-old girl with familial homozygous hypercholesterolemia and extensive coronary atherosclerosis. She had successful cardiopulmonary resuscitation at home by her father 4 months before the operation. Total cholesterol level was 1300 mg/dL initially without antilipidemic treatment. Extensive three vessel disease with right coronary proximal stenosis and left coronary ostial stenoses was determined by angiography. Left internal thoracic artery, left radial artery, and saphenous vein grafts were used for coronary revascularization. Saphenous vein graft to right posterior descending artery, radial artery graft to obtuse marginal artery, and LITA to left anterior descending artery anastomoses were performed consecutively. Ten months after the operation, she is in good condition under intensive antilipidemic therapy and weekly lipid apheresis.

### INTRODUCTION

Mutations in the low-density lipoprotein (LDL) receptor gene cause familial hypercholesterolemia. Homozygous familial hypercholesterolemia (HFH) is a very rare disorder (1:1,000,000) in which both genes for the LDL-receptor are mutated and LDL levels are markedly elevated. Cutaneous and tendinous xanthomata develop in childhood and are the most common finding for initial presentation. Severe aortic and coronary atherosclerosis usually occurs within the first or second decades of life [Marais 2004]. Before the introduction of advanced treatment modalities, mortality was very high in these patients mainly due to acute coronary insufficiency during the first three decades of life. Besides medical treatment of the disease, surgical management of cardiovascular complications is also of great importance. While aortic valve replacement and coronary bypass operations are feasible in adult patients, in childhood and puberty the choice of therapy poses important difficulties [Allen 1980].

Received June 7, 2005; accepted June 12, 2005.

Address correspondence and reprint requests to: Prof. Mehmet Salih Bilal, Igrip Sok, No: 37/4, Konak Apt, Fenerbahce, Kadikoy, 81040 Istanbul, Turkey; (90 216) 478 24 81; fax: (90 216) 368 22 72 (e-mail: [mehmetkaplan@superonline.com](mailto:mehmetkaplan@superonline.com)).

Here we present one of the youngest patients with HFH, who underwent triple coronary bypass surgery, and to the best our knowledge, this case is the first child patient who had long segment radial artery bypass graft.

### PATIENT

Twelve-year-old female patient weighing 27 kg had the diagnosis of HFH 7 years ago. She was under antilipidemic therapy because of very high blood cholesterol levels (1300 mg/dL). She was successfully resuscitated by her father at home 4 months ago. She was suffering from unstable angina since that time. During physical examination, big xanthomas on joints, tendons, and sacral region were seen. Echocardiographical study showed mildly depressed left ventricular function and mild aortic regurgitation and atherom plaques in the ascending aorta. Extensive three vessel disease with right coronary proximal stenosis (95%) and left coronary ostial stenoses (40%) was determined by angiography (Figures 1a and 1b). Angiography also revealed a rudimentary right internal thoracic artery (RITA) and normal developed left internal thoracic artery (LITA) (Figures 2a and 2b). After coronary angiography, she was taken to the ICU for electrocardiographical changes and cardiac enzyme elevation. Preoperative total cholesterol level was 724 mg/dL.

She was operated urgently. Following median sternotomy, left internal thoracic artery, left radial artery, and saphenous vein graft were harvested simultaneously. All grafts were in small size but good quality. LITA and radial artery grafts were dilated with 1:5 diluted intraluminal papaverine solution and then their in situ flows verified. Extracorporeal circulation was initiated by aortic and right atrial cannulation. Under systemic hypothermia at 30°C, diastolic arrest was established with hypothermic intermittent antegrade-retrograde blood cardioplegia. All anastomoses were constructed under 4.5X magnification with loop. It was difficult to choose a suitable place for anastomosis because of extensive atherom plaques visible externally on all coronary arteries. Coronary arteries were also thin and less than 1.0 mm in diameter. Saphenous vein graft to right posterior descending artery, radial artery graft to obtuse marginal artery and LITA to left anterior descending artery anastomoses were performed consecutively by using 8/0 poliprolen sutures. Calcification and plaque formation were present at the aortic root. Proximal anastomosis of the radial artery graft was performed on VSM graft's proximal

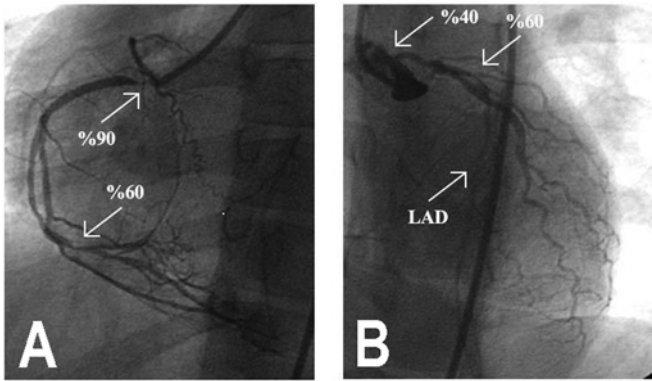


Figure 1. Right coronary (A) and left coronary angiograms (B). (LAD indicates left anterior descending artery.)

anastomosis during aortic cross-clamping period. Aortic cross-clamping period was 55 minutes. Cardiopulmonary bypass was terminated without any complication and in sinus rhythm.

The patient was discharged on postoperative day 10 after an uneventful course in the intensive care unit and the wards. Now, 10 months after the operation, she is asymptomatic and in New York Heart Association (NYHA) Class I, and she is receiving Cholestyramine, Carnitine, Lovastatin, Diltiazem, and Acetylsalicylic acid. Additionally, she has been also undergoing weekly plasma apheresis for the last 4 months, which reduced the total cholesterol and triglyceride levels to 669 mg/dL and 104 mg/dL, respectively.

## DISCUSSION

Most of the reports about coronary bypass surgery in childhood are related to Kawasaki disease or repairing of congenital coronary pathologies such as abnormal origin of left coronary artery from pulmonary artery. Treatment of iatrogenic coronary problems occurring intraoperatively constitutes another major group of patients [Mavroudis 1999]. We could see only a few articles reporting coronary bypass surgery in HFH. The youngest patient in the literature reported by Ersoy and Guvener was a 7-year-old boy and he had two aortocoronary saphenous vein grafts [Ersoy 2000].

Our strategy in coronary surgery is to perform as much arterial grafting as possible. Patency rate of vein grafts is lower markedly in hypercholesterolemic patients [Kawasuji 2000, Lau 2004]. In the presented case, we did not use RITA graft that was seen angiographically rudimentary. In these patients, arch vessels must be visualized angiographically before the operation because of high risk of stenosis. Usage of long segment radial artery conduit has not been reported in pediatric patients who underwent coronary bypass surgery. We could determine only one infant case with abnormal origin of the left coronary artery who had repair with a 6.5 cm long radial artery graft [Bromdan 1996]. In our case, LITA and radial artery grafts were in very small caliber but their distal flows were quite satisfactory. We performed coronary anastomoses longer than usual because of extensive atherosclerotic changes. Growing potential of LITA and vein

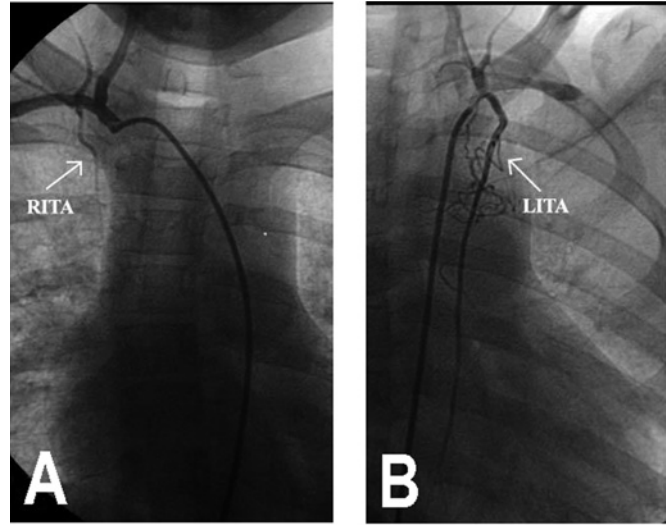


Figure 2. Angiographical view of rudimentary RITA (A) and normal LITA (B). (RITA indicates right internal thoracic artery; LITA, left internal thoracic artery.)

grafts in long term has been shown in pediatric patients with Kawasaki disease [Kitamura 1988, El-Khoury 1998].

Coronary ostial stenoses are not infrequent in children with HFH. Right coronary ostium stenosis has been reported to be associated with sudden death [Verdiere 1984]. Our patient had a cardiac event during her sleep, fortunately resuscitated successfully by her father.

The management of HFH is a medical challenge. The most promising treatment modality in preventing long-term complications in this patient population is statins and lipid apheresis [Naoumova 2004]. In our patient, lipid apheresis that was used during the last 4-month period resulted in a marked decrease in cholesterol and triglyceride levels. Lipid apheresis has been reported to be associated with regression in coronary plaques [Tatami 1992].

In conclusion, children with HFH must be monitored closely for development of coronary atherosclerosis. Arterial grafts offer long-term advantages in this specific group of patients. But long-term prognosis depends on reducing blood cholesterol levels by antilipidemic therapy and lipid apheresis.

## REFERENCES

- Allen JM, Thompson GR, Myant NB, Steiner R, Oakley CM. 1980. Cardiovascular complications of homozygous familial hypercholesterolemia. *Br Heart J* 44:361-8.
- Bromdan RF, Issenberg HJ, Glickstein JS, Frame R. 1996. Use of a free radial artery graft for correction of bland-white-garland syndrome. *Ann Thorac Surg* 62:1525-6.
- El-Khoury HM, Danilowicz DA, Slovis AJ, Colvin SB, Artman M. 1998. Saphenous vein graft growth 13 years after coronary bypass in a child with Kawasaki disease. *Ann Thorac Surg* 65:1127-30.
- Ersoy U, Guvener M. 2000. Coronary revascularization in seven-year-old boy with homozygous familial hypercholesterolemia. *Acta Paediatr* 89:1501-2.

- Kawasuji M, Sakakibara N, Fujii S, Yasuda T, Watanabe Y. 2000. Coronary artery bypass surgery with arterial grafts in familial hypercholesterolemia. *J Thorac Cardiovasc Surg* 119:1008-13.
- Kitamura S, Seki T, Kawachi K, et al. 1988. Excellent patency and growth potential of internal mammary artery grafts in pediatric coronary artery bypass surgery. New evidence for a "live" conduit. *Circulation* 78(3 Pt 2):1129-39.
- Lau GT, Lowe HC, Kritharides L. 2004. Cardiac saphenous vein bypass graft disease. *Semin Vasc Med* 4:153-9.
- Marais AD, Firth JC, Blom DJ. 2004. Homozygous familial hypercholesterolemia and its management. *Semin Vasc Med* 4:43-50.
- Mavroudis C, Backer CL, Duffy CE, Pahl E, Wax DF. 1999. Pediatric coronary artery bypass for Kawasaki congenital, post arterial switch, and iatrogenic lesions. *Ann Thorac Surg* 68:506-12.
- Naoumova RP, Thompson GR, Soutar AK. 2004. Current management of severe homozygous hypercholesterolaemias. *Curr Opin Lipidol* 15:413-22.
- Tatami R, Inoue N, Itoh H, et al. 1992. Regression of coronary atherosclerosis by combined LDL-apheresis and lipid-lowering drug therapy in patients with familial hypercholesterolemia: a multicenter study. The LARS Investigators. *Atherosclerosis* 95:1-13.
- Verdiere C, Drobinski G, Evans JI, Cahen C, de Gennes JL, Thomas D. 1984. Right coronary ostial stenosis in homozygotic hypercholesterolemia. Coronarographic and echocardiographic diagnosis. *Presse Med* 13:1770-2.