

## Insufficiency of an Aortic Valve Prosthesis due to Tissue Ingrowth: A Case Report

Stefan Christiansen, MD,<sup>1</sup> Wolfgang Fehske, MD,<sup>2</sup> Rüdiger Autschbach, MD<sup>1</sup>

<sup>1</sup>Department of Cardiothoracic Surgery, University of Aachen, Aachen, Germany;

<sup>2</sup>Department of Cardiology, Vinzenz-Hospital Köln, Köln, Germany

### ABSTRACT

Tissue ingrowth of a prosthetic heart valve usually leads to a stenosis. We report a rare case of a patient with a fixation of the prosthetic leaflet due to tissue ingrowth. This state caused a total prosthetic insufficiency. The therapy used to treat this prosthetic heart valve with tissue ingrowth is discussed in this report.

### INTRODUCTION

Dysfunction of heart valve prostheses may be caused by a variety of reasons such as paravalvular leakage, prosthetic thrombosis, structural dysfunction, prosthetic endocarditis, and tissue ingrowth, with the last being a rare cause [Korfer 1998]. We report on a patient with tissue ingrowth into an aortic valve prosthesis leading to a high-grade prosthetic insufficiency 10 years after aortic valve replacement.

### CLINICAL SUMMARY

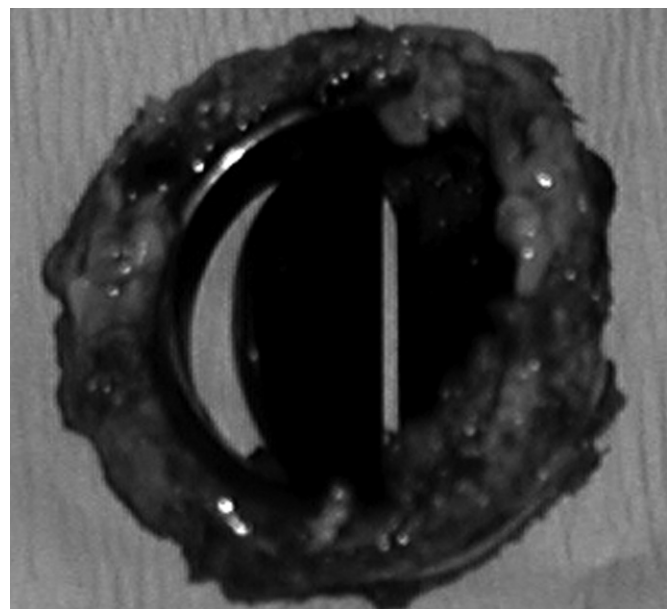
Our patient, a 51-year-old woman suffering fever symptoms of unknown origin, was being seen 10 years after implantation of a mechanical aortic prosthesis (23 mm; St. Jude Medical, St. Paul, MN, USA) in a supra-annular position due to a former congenital aortic stenosis. The results of the performed echocardiography showed a high-grade transprosthetic incompetence. A prosthetic endocarditis was presumed as the cause; however, inflammatory parameters (C-reactive protein, leukocytes) were not elevated. For therapy, a surgical procedure was initiated and a preoperative angiography was performed. The angiography results yielded no sign of coronary artery stenosis; however, the levocardiography showed a fixed mechanical valve disc in an opened position, explaining the prosthetic insufficiency.

Received July 21, 2006; received in revised form November 11, 2006; accepted December 15, 2006.

Correspondence: S. Christiansen, MD, Department of Cardiothoracic Surgery, University of Aachen, Pauwelsstr. 30, 52074 Aachen, Germany; 49-241-80-89221; fax: 49-241-80-82454 (e-mail: [schristiansen@ukaachen.de](mailto:schristiansen@ukaachen.de)).

After median sternotomy, induction of extracorporeal circulation, and cardioplegic arrest, the ascending aorta was incised and the aortic prosthesis inspected. The mechanical valve disc in front of the right coronary ostium was completely immobile and fixed in an open position due to a considerable subannular tissue ingrowth. The aortic prosthesis was excised (Figure) and replaced by another mechanical prosthesis (21 mm; St. Jude Medical) in the annular position. After the patient was weaned from extracorporeal circulation, a third-degree atrioventricular block was diagnosed and the heart was stimulated with a temporary external pacemaker. The postoperative course was uneventful, but unfortunately the atrioventricular block persisted, requiring implantation of a permanent pacemaker.

Two weeks postoperatively, the patient was discharged in good overall condition. The pathologic examination of the explanted valve demonstrated some amorphous, largely acellular tissue with few fibroblasts, which is consistent with tissue ingrowth associated with mechanical cardiac prosthesis.



The explanted mechanical aortic prosthesis with severe tissue ingrowth causing prosthetic dysfunction.

## DISCUSSION

Tissue ingrowth into prosthetic heart valves has been described for aortic as well as mitral prostheses [Hutchinson 1995; Munclinger 1998; Delgado 2000; Kuniyoshi 2003]. The reasons for tissue ingrowth after cardiac valve replacement are not known. The following criteria are being discussed: prosthetic design, biocompatibility, previous irregular endothelial surfaces, low-output conditions, high transvalvular gradients (especially in the mitral position), pregnancy, endocarditis, and inadequate anticoagulation (either individually or in combination to trigger fibroblast proliferation) [Vitale 1994]. Usually the ingrowth results in a stenosis of the prosthesis by obstruction of the orifice area/left ventricular outflow tract or restriction of the prosthetic valve disc movement [Hutchinson 1995; Kuniyoshi 2003], but rare symptoms such as intermittent electromechanical dissociation may also occur [Delgado 2000]. In our patient, the tissue ingrowth resulted in a fixation of one disc in an open position, leading to a severe prosthetic incompetence with surprisingly few symptoms.

Until now, it has been very difficult to differentiate between pure tissue ingrowth and prosthetic valve thrombosis (which is the most frequent complication after cardiac valve replacement) [Reddy 1994] since both complications may be associated with the same sequelae. A complete disc excursion may indicate a primary prosthetic thrombosis, whereas the disc movement is usually restricted in patients with a tissue ingrowth [Vitale 1994]. Since an operative change of a cardiac prosthesis is associated with a high mortality rate (up to 20%) [Reddy 1994], a systemic thrombolysis with a lower mortality (0%-10%) may be taken into consideration [Munclinger 1998]. But a thrombolytic therapy can be associated with

embolic and/or bleeding complications [Reddy 1994; Vitale 1994]. A rethrombosis of a cardiac valve prosthesis after an initial successful thrombolysis may occur in up to 20% of these patients, raising the question of whether surgical treatment or a second thrombolysis should be performed. It is probable that tissue ingrowth that cannot be treated effectively by thrombolysis is the reason for this high frequency of rethrombosis [Vitale 1994]. Therefore, we would recommend surgical treatment after a failed thrombolysis.

## REFERENCES

- Delgado C, Bonnin O, Garriga JM, et al. 2000. Intermittent electromechanical dissociation as an unusual sign of prosthetic valve thrombosis in a patient with prosthetic fibrous ingrowth. *J Am Soc Echocardiogr* 13:685-9.
- Hutchinson SJ, Lapkin L, Matthews S, et al. 1995. Cyclic intermittent opening of Bjork-Shiley mitral prosthesis caused by fibrous tissue ingrowth. *Am Heart J* 130:629-31.
- Korfer R, Kleikamp G. 1998. Prevention and management of dysfunction of prosthetic heart valves. *Herz* 23:448-52.
- Kuniyoshi Y, Koja K, Miyagi K, et al. 2003. Pannus formation in aortic valve prostheses in the postoperative period. *J Artif Organs* 6:179-82.
- Munclinger MJ, Patel JJ, Mitha AS. 1998. Thrombolysis of thrombosed St. Jude Medical prosthetic valves: rethrombosis—a sign of tissue ingrowth. *J Thorac Cardiovasc Surg* 115:248-9.
- Reddy NK, Padmanabhan TNC, Singh S, et al. 1994. Thrombolysis in left-sided prosthetic valve occlusion: immediate and follow-up results. *Ann Thorac Surg* 58:462-71.
- Vitale N, Renzulli A, Cerasuolo F, et al. 1994. Prosthetic valve obstruction: thrombolysis versus operation. *Ann Thorac Surg* 57:365-70.