

# Taming of the Tiger: A Novel Technique to Deal With Mitral Annular Calcification —A Case Series

Varghese T Panicker, MCH, Renjith Sreekantan, MCH, Sai Suraj Kotera, MS

Department of Cardiovascular and Thoracic Surgery, Sree Chitra Tirunal Institute for Medical Sciences and Technology, Trivandrum, India

## ABSTRACT

**Background:** Mitral valve surgery can be challenging for patients with mitral annular calcification (MAC). The prevalence of MAC in patients who undergo mitral valve replacement is 19.9%. The treatment options for MAC include complete decalcification and annular reconstruction with valve repair/replacement or performing a surgical valve repair or replacement without decalcification, accepting the risk of paravalvular leak. We describe three cases of mitral valve prolapse with posterior annular calcification, which were repaired using a unique technique that does not require decalcification.

**Case reports:** The mitral annular calcification was heavy and involved most of the posterior annulus just sparing the commissures in all the three cases. Leaflet prolapse was dealt with by using neochordae, closing any clefts, and leaflet plication. Since the MAC ring was not complete and there was chance of further dilatation of the annulus, a partial annuloplasty was done using a PTFE felt (cut as strip). There was trivial to no mitral regurgitation with this technique in the immediate postoperative and five-year follow-up period echocardiography in all the three cases.

**Conclusion:** This technique can benefit the major subset of pure mitral valve regurgitant lesions associated with MAC, which is limited to the posterior annulus.

## INTRODUCTION

Mitral valve surgery can be challenging for patients with mitral annular calcification (MAC). It is limited to the posterior annulus sparing the commissures in 90% of the cases [Carpentier 1996]. Mitral valve surgery in patients with MAC can be risky even in the most experienced hands, and it can result in a higher mortality [Bedeir 2018]. MAC usually occurs in older patients and more often in women. The risk factors associated with MAC are dyslipidemia, diabetes mellitus, hypertension, and peripheral vascular disease. The

prevalence of MAC in patients who undergo mitral valve replacement is 19.9% [Kaneko 2019]. The treatment options for MAC include complete decalcification and annular reconstruction with valve repair/replacement or performing a surgical valve repair or replacement without decalcification, accepting the risk of paravalvular leak. There also is an option of using a minimally invasive transcatheter or open self-expanding valve.

If the valve is repaired without decalcifying the MAC, the need to use an annuloplasty ring is reduced when there is no chance of further dilatation of the annulus and there exists a good coaptation length between the leaflets. Also, when the calcific ring is complete or involves both the commissures, there might not be a need to use an annuloplasty ring as the annulus is less likely to dilate [Smith 2012]. For incomplete rings of mitral annular calcium, unconventional repair techniques using a partial annuloplasty ring might help with increasing the durability of the repair. We describe three cases of mitral valve prolapse with posterior annular calcification

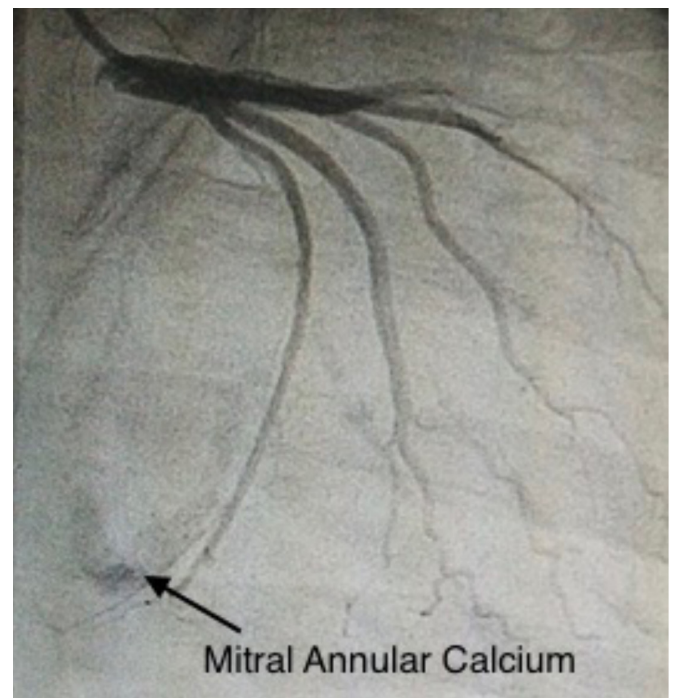


Figure 1. Coronary angiogram showing 'C' shaped mitral annular calcium.

Received July 24, 2020; accepted August 10, 2020.

Correspondence: Dr. Varghese T Panicker, MCH, Additional Professor, Department of Cardiovascular and Thoracic Surgery, Sree Chitra Tirunal Institute for Medical Sciences and Technology, Trivandrum, India, 695011; +91 9387801642 (e-mail: [vtpanicker@gmail.com](mailto:vtpanicker@gmail.com)).

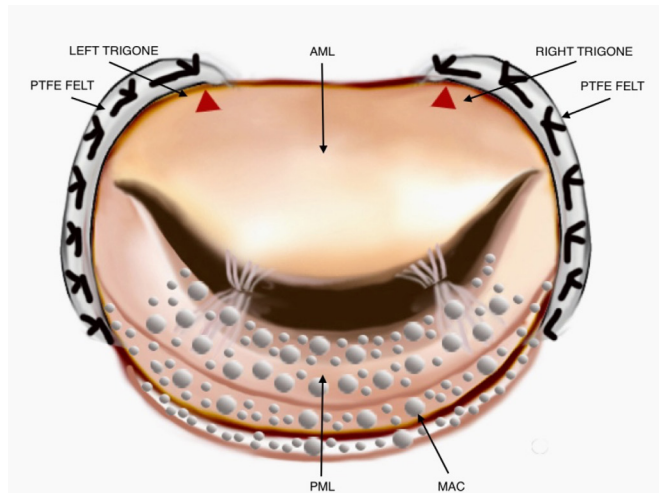


Figure 2. Partial annuloplasty ring (PTFE felt) connected to both trigones extending from the edge of the MAC ring on each side. Red arrows indicate the right and left trigones, and the white dots denote the calcium. AML, anterior mitral leaflet; PML, posterior mitral leaflet; MAC, mitral annular calcium; PTFE, poly tetra fluoroethylene

which were repaired using a unique technique that does not require decalcification.

## PATIENTS AND METHODS

**Case 1:** A 44-year-old female, without any known comorbidities, presented to the hospital with a history of dyspnea on performing less than ordinary physical activities, New York Heart Association (NYHA) functional class 3, and palpitations for two years. She was found to have valvular heart disease on clinical evaluation. Electrocardiogram (ECG) revealed a heart rate of 88 bpm, sinus rhythm, and left ventricular hypertrophy. Chest X-ray showed cardiomegaly and transthoracic echocardiography (TTE) revealed mitral valve prolapse (MVP) of the posterior mitral leaflet (PML) with severe mitral regurgitation (MR) and significant mitral annular calcification (MAC) across the posterior annulus, dilated left atrium (LA) and left ventricle (LV) with good left ventricular systolic function. The left ventricular internal diameter-diastolic (LVIDD) was 66 mm, and the left ventricular internal diameter-systolic (LVIDS) was 39 mm. There was no stenosis of the mitral valve. The treatment of choice was surgery, and mitral valve repair with partial annuloplasty was performed.

The approach was through the LA. Inspection of the mitral valve revealed primary chordal rupture of the P2 and P3 segments and ‘C’ shaped mitral annular calcification around the PML. The mitral annular calcium was heavy, involving most of the posterior annulus and sparing the commissures. Chordal reconstruction of primary chordae of the P2 and P3 segments was done with polytetrafluoroethylene (PTFE) sutures. Mitral annular calcium inclusive partial annuloplasty with PTFE felt was performed. Leaflet movements were tested by injecting saline into the LV cavity. The patient was

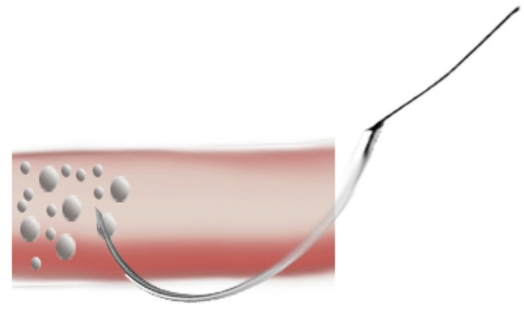


Figure 3. The first stitch grazing the annular calcium.

weaned from cardiopulmonary bypass (CPB) without any inotropic support. Post-CPB transesophageal echocardiography (TEE) showed no residual MR with minimal transvalvular pressure gradient (less than 2 mm Hg) across the repaired valve and good ventricular function. The patient had an uneventful postoperative course and was discharged. At six-year follow up, there was no residual MR and the LVIDD and LVIDS reduced to 40 and 26 mm, respectively (Table).

**Case 2:** A 56-year-old male presented with complaints of dyspnea on exertion (NYHA functional class 2). The patient did not have a comorbid illness, but had a family history of coronary artery disease. Physical evaluation revealed a pansystolic murmur at the apex. ECG showed a heart rate of 92 bpm in sinus rhythm with left axis deviation. TTE revealed a flail PML causing severe MR and a calcified posterior mitral annulus extending to the basal LV. The LVIDD and LVIDS measured 61 and 36 mm, respectively, and LV systolic function was preserved. The right ventricular systolic pressure (RVSP) was 40 mm Hg. Coronary angiogram (CAG) did not show any flow-limiting lesion but showed MAC (Figure 1). Surgical management was the choice, which was similar to our first patient.

After opening the LA and exposing the mitral valve, the anterior mitral leaflet (AML) and PML were found to be slightly thickened. The P2 segment of PML was flail and calcified with multiple ruptured chordae. MAC was present over the posterior annulus extending into the LV. The mitral annulus was dilated. Neochordae were placed onto the flail P2 segment, and MAC inclusive partial annuloplasty was performed to prevent further dilatation of the annulus. A saline test did not reveal any residual MR. After rewarming, weaning from cardiopulmonary bypass was done with inotropic support of Inj Dobutamine 5 mcg/Kg/min. TEE revealed trivial MR with a mean transvalvular pressure gradient of 3 mm Hg and good biventricular function. The patient developed atrial fibrillation in the postoperative period, which reverted with amiodarone and cardioversion. The patient’s recovery was otherwise smooth, and he was discharged on postoperative day (POD) 6. TTE at five-year follow up showed a reduction in LVIDD and LVIDS to 40 and 20 mm, respectively, and there was no MR.

## Comparison of preoperative and postoperative left ventricular internal diameter and NYHA functional class

Patient	Age at surgery	Sex	Preoperative LVIDD	Preoperative LVIDS	LVIDD at 5-year follow up	LVIDS at 5-year follow up	NYHA functional class preoperatively	NYHA status functional class postoperatively
Case 1	44	Female	66 mm	39 mm	40 mm	26 mm	3	1
Case 2	56	Male	61 mm	36 mm	40 mm	20 mm	2	1
Case 3	39	Male	58 mm	36 mm	53 mm	31 mm	3	1

Age in years; LVIDD, left ventricular internal diameter diastolic; LVIDS, left ventricular internal diameter systolic; NYHA, New York heart association

Case 3: A 39-year-old male patient was incidentally detected with valvular heart disease, during an evaluation for a lower respiratory tract infection, nine years ago. He gradually developed symptoms of dyspnea and palpitations (NYHA class 2). He also had occasional angina, which was limited to the precordial region. Clinical evaluation confirmed the presence of valvular heart disease. TTE revealed mitral valve prolapse with the P2 segment affected and causing severe MR. The LVIDD measured 58 mm, and LVIDS was 36 mm. The left ventricular systolic function was preserved. CAG revealed a ramus lesion causing 40% stenosis.

Intraoperatively, inspection of the mitral valve revealed thickened mitral leaflets with A3, P2 segments prolapse, and a cleft in the P3 segment. The posterior mitral annulus was calcified. The cleft in the P3 segment was repaired and the prolapsed P2 and A3 segments were shortened using neochordae. MAC inclusive partial annuloplasty was performed using a PTFE felt patch. The valve was assessed using saline and also with TEE after weaning from CPB. Both did not reveal any residual MR and showed good ventricular function without any regional wall motion abnormality. The patient had an uneventful course in the hospital. At five-year follow up, the LVIDD was 53 mm, and LVIDS was 31 mm. There was no MR.

Surgical technique: The mitral annular calcification was heavy and involved most of the posterior annulus just sparing the commissures in all three cases. Leaflet prolapse was dealt with by using neochordae, closing clefts, if any, and leaflet plication. Since the MAC ring was not complete and there was a chance of further dilatation of the annulus, a partial annuloplasty was done using a PTFE felt (cut as strip). The strip extended from the edge of MAC on each side to the trigone on each side (Figure 2). The first stitch was taken grazing the annular calcium (Figure 3). After the annuloplasty, there was a definite reduction in the anteroposterior diameter, and the coaptation distance visibly increased on water test.

## DISCUSSION

Mitral annular calcification presents a unique challenge to the surgeon and adds complexity to decision-making during surgery. There is no defined common management pathway that can be followed for cases with MAC. The present treatment followed for mitral valve pathologies with mitral

annular calcium is either decalcification with valve surgery or performing valve surgery without any decalcification. Both methods have their own pros and cons.

Carpentier et al described a technique to deal with extensive mitral annular calcification. It involves temporary detachment of leaflets and en bloc resection of the calcium deposit and annular reconstruction using a figure-of-eight 2-0 braided sutures placed in the atrial and ventricular edges, followed by using Carpentier techniques of valve repair. Sixty-seven patients benefitted from this technique, and they did not report atrio-ventricular groove dehiscence in any of the patients, however they reported one case of AV block and four cases of reoperation [Carpentier 1996]. There always is a chance of leaving the annulus thin and friable with this en bloc resection of calcium. Extensive decalcification can result in atrioventricular dehiscence, ventricular rupture, coronary injuries, and hemorrhagic complications.

The challenge with MAC is in mounting the annuloplasty ring. Leaflet-based repairs without a ring are simple, but results can vary [Bedeir 2018].

Nataf et al described a technique of intra-atrial insertion of mitral prosthesis in patients with extensive annular calcification and annulus dehiscence, due to mitral annular abscess. Their technique exposes the fragile left atrium to ventricular pressure and can cause hemorrhage and paravalvular leak [Nataf 1994]. This technique can be used when valve implantation at the annulus is made impossible for various reasons. Conservative techniques, which involve avoiding decalcification, can cause paravalvular leak even when an open atrial transcatheter valve is used [Russell 2019].

Morasaki et al described a case series of three patients with mitral regurgitation with a near-circumferential ring of MAC. They employed leaflet-based repair to treat the MR. They did not use an annuloplasty ring as MAC involved the entire annulus. There was no dilatation of the annulus for up to two years postoperatively [Morisaki 2014]. However, we describe a technique that uses an annuloplasty ring and is useful in cases where the calcification ring is not complete.

We report a novel technique of mitral annular calcification inclusive annuloplasty, which is simple, safe and can be easily practiced when the MAC is limited to the posterior annulus.

The relatively high number of complications in the extensive decalcification of MAC forced us to consider respecting the annular calcification and perform a partial annuloplasty, using a PTFE felt strip in these three cases. There

was trivial-to-no mitral regurgitation with this technique in the immediate postoperative and five-year follow-up period echocardiography.

This technique can benefit the major subset of pure mitral valve regurgitant lesions associated with MAC, which is limited to the posterior annulus.

## REFERENCES

- Bedeir K, Kaneko T, Aranki S. 2018. Current and evolving strategies in the management of severe mitral annular calcification. *J Thorac Cardiovasc Surg* 157:555-66.
- Carpentier AF, Pellerin M, Fuzellier JF, Relland JY. 1996. Extensive calcification of the mitral valve annulus: pathology and surgical management. *J Thorac Cardiovasc Surg* 111:718-30.
- Kaneko T, Hirji S, Percy E, Aranki S, McGurk S, Body S, et al. 2019. Characterizing risks associated with mitral annular calcification in mitral valve replacement. *Ann Thorac Surg* 108:1761-7.
- Morisaki A, Kato Y, Takahashi Y, Shibata T. 2014. Mitral valve repair without mitral annuloplasty with extensive mitral annular calcification. *Interact Cardiovasc Thorac Surg* 19(6):1080-1082.
- Nataf P, Pavie A, Jault F, Bors V, Cabrol C, Gandjbakhch I. 1994. Interatrial insertion of a mitral prosthesis in a destroyed or calcified mitral annulus. *Ann Thorac Surg* 58:163-7.
- Russell HM. 2019. Open atrial transcatheter mitral valve replacement in patients with mitral annular calcification. *J Thorac Cardiovasc Surg* 157:907-16.
- Smith CR, Stamou SC, Boeve TJ, Patzelt LH. 2012. Folding mitral valvuloplasty without posterior leaflet resection for calcified mitral annulus. *Interact Cardiovasc Thorac Surg* 14:143-5.