

Modified Septal Myectomy Using a Curved Knife for Left Ventricular Septal Hypertrophy

Shinya Takahashi, MD, PhD,¹ Taiichi Takasaki, MD, PhD,¹ Futoshi Tadehara, MD, PhD,² Takahiro Taguchi, MD,¹ Keiichi Katayama, MD, PhD,¹ Tatsuya Kurosaki, MD, PhD,¹ Katsuhiko Imai, MD, PhD,¹ Taijiro Sueda, MD, PhD¹

¹Department of Department of Cardiovascular Surgery, Hiroshima University, Hiroshima, Japan;

²Department of Cardiology, Mazda Hospital, Hiroshima, Japan

ABSTRACT

An 86-year-old woman presented with chest pain and discomfort. Echocardiography revealed severe aortic valve stenosis and asymmetric septal hypertrophy. Aortic valve replacement and myectomy were performed using a curved knife. The blade was U-shaped in cross-section, and was curved upward along the long axis. Hypertrophic septal myocardium was removed along the long axis of the left ventricle (LV), and a groove for blood flow was constructed. The patient was discharged uneventfully without recurrence of her chest discomfort. Our result suggested that a curved knife is a reasonable option for transaortic septal myectomy in patients with obstructive LV hypertrophy.

INTRODUCTION

Septal myectomy is a standard treatment of hypertrophic left ventricle (LV) outflow obstruction. When coronary bypass, valvular surgery, or aortic repair is also required, surgical myectomy for septal hypertrophy is often performed via a simple procedure using a straight scalpel. Here, we describe the successful treatment of aortic valve stenosis and asymmetric LV hypertrophy via aortic valve replacement and septal myectomy using a curved scalpel.

CASE REPORT

An 86-year-old woman presented with a 2-week history of chest pain, discomfort, and depression. A chest x-ray showed cardiomegaly and bilateral pleural effusions. Echocardiogram revealed severe aortic valve stenosis (aortic valve area = 0.60 cm²) with annular and cusp calcifications, marked hypertrophy of the basal septum, and LV outflow tract stenosis (Figure 1, A). Peak pressure gradients measured 40 mmHg at rest and 72 mmHg during valsalva, with a total gradient across the LV outflow tract of 143 mmHg. No systolic anterior motion of the mitral valve was observed. Both the aortic valve stenosis

and the asymmetric septal hypertrophy were thought to be causing the patient's clinical condition and a semi-emergent operation was planned.

The operation was performed through a median sternotomy while the patient was supported by total cardiopulmonary bypass with mild systemic hypothermia. A transverse aortotomy was performed and the aortic valve and annular calcifications were removed. The hypertrophied septum bulged into the anterior aspect of the LV outflow tract (Figure 2, A). A curved knife (ST Engineering, Hiroshima, Japan, Tokyo, Japan) was used to excise the hypertrophied ventricular septal muscle. The blade was U-shaped in cross-section and the tip of the blade was curved upward along the long axis (Figure 2, C). A parallel incision was made in the septum precisely beneath the annulus of the right coronary cusp and parallel to the long axis of the LV outflow tract (Figure 2, B). The blade was visible from the inside of the septum due to the curvature of the blade tip. A sponge stick was pressed against the RV free wall to depress the ventricular septum and allow a better view of its apical aspect. The myectomy was extended as far as possible and was terminated near the apex and papillary muscle (Figure 2, D). A ball-shaped sizer for aortic valve replacement was inserted into the LV without pressure, and the thickness of the LV was confirmed manually. A bioprosthetic aortic valve (Magna EASE, Edwards Lifesciences LLC, Irvine, CA) was implanted in the supra-annular position.

A postoperative echocardiogram showed resolution of the LV outflow obstruction with a trivial LV outflow tract gradient of 4.8 mmHg (Figure 1, B). Histological examination showed degenerative changes without evidence of hypertrophic obstructive cardiomyopathy. The patient had no recurrence of her chest pain and was discharged uneventfully.

DISCUSSION

Although surgical interventions for obstructive LV hypertrophy have been performed since the late 1950s, many early procedures, including the LV approach, the left atrial approach, or the use of a corkscrew, are no longer used [Dobell 1964; Kirklin 1961; Swan 1964]. Instead, a modified myectomy via an aortic approach is often used. Morrow et al reported that hypertrophic septal muscle could be excised as a strip made from two vertical incisions connected by a transverse incision using a conventional scalpel blade [Morrow 1975]. A No.11 scalpel, the most commonly used scalpel for this procedure, has a spinous and

Received September 17, 2014; received in revised form September 24, 2014; accepted October 3, 2014.

Correspondence: Shinya Takahashi, MD, PhD, Department of Cardiovascular Surgery, Hiroshima University, 1-2-3 Kasumi, Minamiku, Hiroshima, Japan, 734-8551; +81-82-257-5216; fax: +81-82-257-5219 (e-mail: shiny@nte.biglobe.ne.jp).

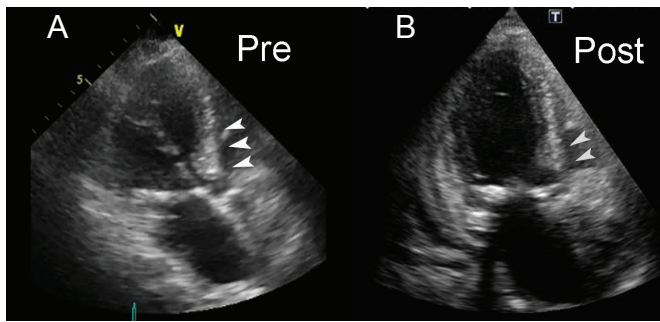


Figure 1. Preoperative and postoperative echocardiogram. Preoperative echocardiogram showing severe aortic valve stenosis and septal LV hypertrophy (A, white arrow). Postoperative echocardiogram demonstrating a reduction in hypertrophic myocardium and a widely patent LV outflow tract (B, gray arrow).

straight blade that is ideal for stab incisions, cutting straight lines, and altering the width of the resected muscle. When used during myectomy, a No.11 scalpel, via a protective retractor inside the LV cavity, can prevent accidental dissection of the anterior leaflet of the mitral valve. We chose to use a curved knife, however, because it has a longitudinal blade and can be easily used to make a precise incision toward the LV apex. The width of the blade used depends upon the size of the muscle to be resected. Hypertrophic septal myocardium can be removed along the long axis of the LV, and a groove for blood flow can be constructed. Moreover, due to the blade's curvature, it always emerges from the inner surface of ventricular myocardium.

Several techniques take advantage of other devices. Messemmer et al reported the successful use of trefoil retractors for extended septal myectomy [Messemmer 1994]. Usui et al achieved favorable results by inserting a needle stick into the ventricular septum to indicate the area of myectomy [Usui 2013]. Hence, multiple techniques can be used for safe and effective septal myectomy.

Precise guidelines are not available for the surgical treatment of asymmetric septal hypertrophy. It is clear, however, that performing only an aortic valve replacement may not resolve a patient's symptoms [Aurigemma 1992; Di Tommaso 2013]. The choice to limit surgical treatment to aortic valve replacement is usually made in order to avoid complications such as atrioventricular block and septal perforation. However, a previous study found that myectomy concurrent with aortic valve replacement is safe and improves LV mass regression and LV diastolic function [Di Tommaso 2013]. Hence, conventional septal myectomy, as well as alternative techniques, including the curved-blade method outlined here, may result in improved outcomes.

In conclusion, our results suggest that a curved knife is a reasonable option for transaortic septal myectomy in patients with obstructive LV hypertrophy. As this is the first reported case of its use in this manner, further investigation of the curved knife is needed.

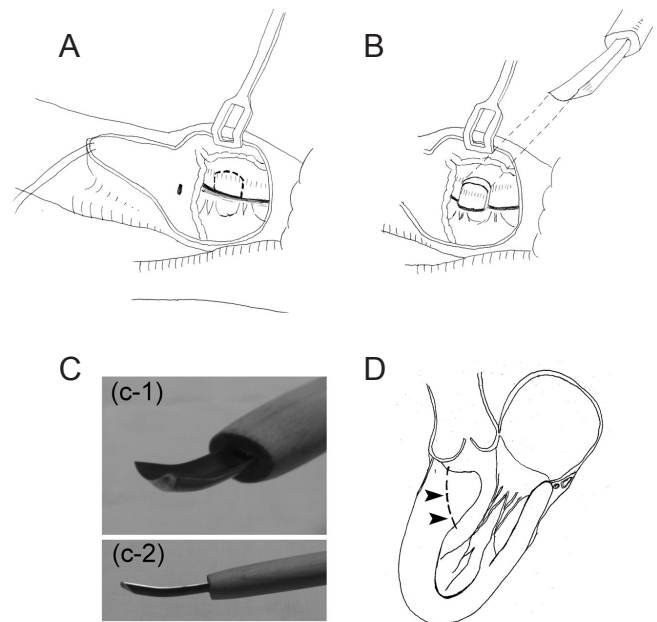


Figure 2. Operation schema. Hypertrophied septal myocardium bulging into the anterior aspect of the LV outflow tract (A) was excised by a curved knife (B). The knife was U-shaped in cross-section (C, upper panel) and the blade tip was curved slightly upward along the long axis (C, lower panel). The knife was used to excise LV muscle on the inside of the LV cavity. The cutting line of the LV muscle is shown (D, black arrow).

REFERENCES

- Aurigemma G, Battista S, Orsinelli D, et al. 1992. Abnormal left ventricular intracavitary flow acceleration in patients undergoing aortic valve replacement for aortic stenosis. A marker for high postoperative morbidity and mortality. *Circulation* 86:926-36.
- Di Tommaso L, Stassano P, Mannacio V, et al. 2013. Asymmetric septal hypertrophy in patients with severe aortic stenosis: the usefulness of associated septal myectomy. *J Thorac Cardiovasc Surg* 145:171-5.
- Dobell AR, Scott HJ. 1964. Hypertrophic subaortic stenosis: evolution of a surgical technique. *J Thorac Cardiovasc Surg* 47:26-39.
- Kirklin JW, Ellis FH Jr. 1961. Surgical relief of diffuse subvalvular aortic stenosis. *Circulation* 24:739-42.
- Messemmer BJ. 1994. Extended myectomy for hypertrophic obstructive cardiomyopathy. *Ann Thorac Surg* 58:575-7.
- Morrow AG, Reitz BA, Epstein SE, et al. 1975. Operative treatment in hypertrophic subaortic stenosis. Techniques, and the results of pre and postoperative assessments in 83 patients. *Circulation* 52:88-102.
- Swan H. 1964. Subaortic muscular stenosis: a new surgical technique for repair. *J Thorac Cardiovasc Surg* 47:681-4.
- Usui A, Araki Y, Oshima H, Ueda Y. 2013. A needle stick technique for septal myectomy for hypertrophic obstructive cardiomyopathy. *Ann Thorac Surg* 95:726-8.