

Vascular Complications of Lower Limb Ischemia in Patients with Femoral Venoarterial Extracorporeal Membrane Oxygenation

Xiaozu Liao,¹ Zhou Cheng,¹ Liqiang Wang,¹ Binfei Li,¹ Weizhao Huang,² Junlin Wen,¹ Haiming Jiang,² Zhanyuan Zhao,³ Yong Yuan⁴

¹Department of Anesthesiology, Zhongshan City People's Hospital, Zhongshan, China; ²Department of Cardiac Surgery, Zhongshan City People's Hospital, Zhongshan, China; ³Department of Intensive Care Unit, Zhongshan City People's Hospital, Zhongshan, China; ⁴Department of Cardiology, Zhongshan City People's Hospital, Zhongshan, China

ABSTRACT

Background: Lower limb ischemia in patients with extracorporeal membrane oxygenation (ECMO) via femoral artery catheterization negatively affects patient mortality and survivors' quality of life [Gulkarov 2020]. In this study, ECMO was established via femoral artery catheterization. This study aimed to identify the risk factors of lower limb ischemia to provide sufficient evidence for its prevention.

Methods: All patients with venoarterial (VA) ECMO via femoral artery catheterization in Zhongshan People's Hospital from January 2008 to November 2019 retrospectively were analyzed. Patients' general information and ECMO-related information were obtained, and the main outcome variables were survival and discharge and intubation-related adverse events (limb ischemia and incision bleeding). Logistic regression analysis was used to determine the independent risk factors of limb ischemia in patients with VA ECMO.

Results: A total of 179 (98 [54.7%] men and 81 [45.3%] women) eligible patients were included in this study. Moreover, a total of 90 patients (48.9%) had low cardiac output, 41 (22.3%) had acute myocardial infarction, and 33 (17.9%) had fulminant myocarditis. Eighty-six (48.04%) patients survived to hospital discharge, 36 (20.11%) had limb ischemia, and 42 (23.46%) had incision bleeding. Furthermore, the ECMO-assisted time was 114.23 ± 67.88 hours. There was no significant difference in age, sex, and Sequential Organ Failure Assessment score between the limb ischemia group and the non-limb ischemia group. Multivariate logistic regression analysis showed that peripheral artery disease (odds ratio, 27.12; 95% confidence interval, 5.614–130.96) was an independent risk factor of limb ischemia in patients with ECMO.

Conclusion: Limb ischemia is a common complication in patients with VA ECMO, and peripheral artery disease is an

independent risk factor of limb ischemia in patients with VA ECMO via femoral artery catheterization.

INTRODUCTION

Venoarterial extracorporeal membrane oxygenation (VA ECMO) is a form of temporary mechanical circulatory support for cardiorespiratory failure that has been widely used in patients with refractory cardiac shock, including post-operative low cardiac output syndrome, fulminant myocarditis, myocardial infarction, severe pulmonary infarction, cardiac arrest, and heart transplant transition [Unai 2019; Dohain 2019; Li 2017; Hu 2011; Karami 2019; Das 2018; Lupei 2019; Kawabori 2019; Poptsov 2019]. At present, VA ECMO mainly is established via central catheterization and peripheral catheterization. Central catheterization generally includes the catheterization of the right atrium of the heart and ascending aorta. Peripheral catheterization mainly includes the catheterization of the internal jugular vein and carotid artery in the neck and femoral vein and femoral artery in the lower extremity. In case of sudden cardiac arrest and sudden shock, it is more convenient and faster to establish ECMO via peripheral catheterization

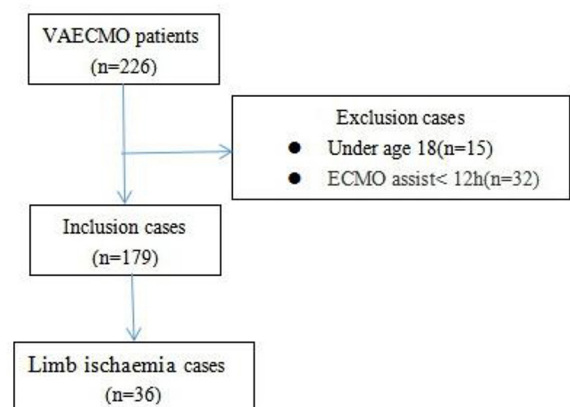


Figure 1. Schematic Illustration of the Study Cohort Selection

Received March 15, 2020; accepted April 13, 2020.

Correspondence: Xiaozu Liao, Department of Anesthesiology, Zhongshan City People's Hospital, Zhongshan City, Guangdong Province, China, 528403; (86)13450921219 (e-mail: liao.xiaozu@163.com).

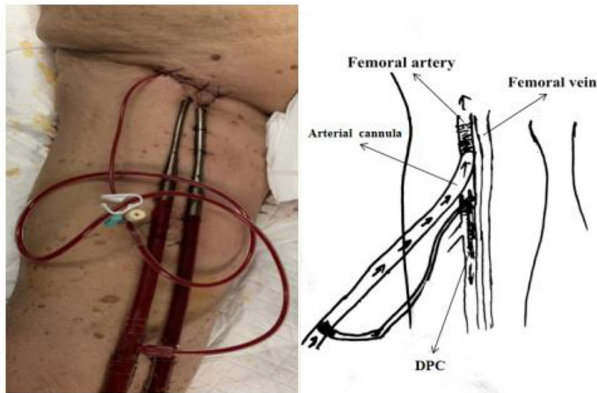


Figure 2. A Distal Perfusion Cannula was Inserted into the Superficial Femoral Artery for an Antegrade Flow to the Extremity

than via central catheterization, with the former being the most common choice in clinical practice [Jayaraman 2017]. In patients with VA ECMO via femoral artery catheterization, lower limb ischemia is a fatal complication, possibly decreasing the diameter of the vessel caused by hemodynamic instability and the size of the vessel in the indwelling artery intubation caused by the use of vasopressor to increase vascular tension [Augusto 2019; Kim 2019]. Recent studies have shown that limb ischemia negatively affects patient mortality (increased in-hospital and 30-day mortality) and survivors' quality of life [Kaushal 2019]. In this study, vascular complications of lower limb ischemia in patients with VA ECMO via femoral artery catheterization retrospectively were studied to analyze the risk factors of lower limb ischemia to provide sufficient evidence for the prevention of lower limb ischemia.

MATERIALS AND METHODS

Selection of Patients

This study was reviewed and approved by the Ethics Committee of Zhongshan People's Hospital, and a retrospective analysis was performed in all patients with VA ECMO via femoral vein and femoral artery catheterization in Zhongshan People's Hospital from January 2008 to November 2019. Included in this study were patients with VA ECMO via femoral vein and femoral artery catheterization. Excluded from this study included patients younger than 18 years of age and patients with ECMO for less than 12 hours.

Catheterization

All patients underwent surgical hemitomy to establish the vascular access for ECMO. A transverse incision was created in the groin to expose the femoral vein and femoral artery vessels, and the arterial and venous cannula and distal reperfusion cannula of the lower extremity were inserted using the Seldinger technique, and the skin was sutured. When the catheter was removed, the surgical incision was reopened,

Table 1. Clinical outcomes in patients with extracorporeal membrane oxygenation

Survived to hospital discharge	86 (48.04)
Limb ischemia	36 (20.11)
Incision bleeding	42 (23.46)
ECMO duration (hours)	114.23±67.88

the cannula was removed, and blood vessels were sutured. Thrombectomy or reconstructive surgery was performed when a clot or torn artery was noted. Arterial intubation (Medtronic, 10–15 cm, 15 Fr) was used to insert the common arteries, and venous intubation (Medtronic, 35–45 cm, 21 Fr) was used to insert the common veins. A distal perfusion cannula (Terumo, 8 Fr) was inserted into the distal limb of the artery and connected to the femoral artery cannula shunt junction to prevent ischemia. The infusion system consisted of Medtronic Bio-Pump centrifugal pump, Medtronic oxygenator, and Medtronic heparin-coated tube.

Extracorporeal membrane oxygenation management: ECMO initially maintained an ECMO flow rate of 2.2 L/min/body surface area (m²) and a mean arterial pressure greater than 65 mmHg. The activated clotting time lasted for 180–200 seconds.

Data Collection

Patients' general information (history of hypertension, diabetes, and peripheral artery disease), ECMO-related conditions, and intubation-related adverse events (limb ischemia and incision bleeding) were obtained. History of peripheral artery disease was defined as prior history of diagnosis or prior vascular reconstruction of the lower extremities. To assess the presence of lower limb ischemia, the lower limbs (pale, gangrene, lack of pulse, loss of Doppler signal, movement or sensory disturbance) were evaluated [McNally 2018]. The diagnosis of lower limb ischemia was established by a team of vascular specialists based on clinical evaluation.

Statistical Analysis

The Statistical Package for the Social Sciences version 20.0 software was used for data collation. Continuous variables were expressed as mean ± standard deviation for normally distributed data and median (interquartile range) for non-normally distributed data. Measurement data were recorded in the form of independent sample T-test for comparison of indicators between the 2 groups. The counting data were recorded in the form of N (%), and the chi-squared test was used for comparison (supplemented by accurate probability method to directly calculate the *P* value if necessary). Regarding the step-forward method, multivariate logistic regression analysis was performed on statistically significant variables in univariate analysis using the conditional regression method to determine the independent risk factors for limb ischemia in patients with ECMO. The test level was 0.05, and the difference was statistically significant if *P* < .05.

Table 2. Univariate analysis results of limb ischemia-related factors

	Total (N = 179)	Limb ischemia		χ^2/T	P
		Yes	No		
Age (years)		47.81 ± 19.65	46.43 ± 16.65	0.388	.700
Sex				0.410	.522
Male	98 (54.7)	18 (18.37)	80 (81.63)		
Female	81 (45.3)	18 (22.22)	63 (77.78)		
Hypertension				0.183	.669
Yes	40 (22.3)	9 (22.5)	31 (77.5)		
No	139 (77.7)	27 (19.42)	112 (80.58)		
Diabetes				0.044	.835
Yes	23 (12.8)	5 (21.74)	18 (78.26)		
No	156 (87.2)	31 (19.87)	125 (80.13)		
Peripheral artery disease				31.998	<.001
Yes	12 (6.7)	10 (83.33)	2 (16.67)		
No	167 (93.3)	26 (15.57)	141 (84.43)		
Classification of indications for ECMO				/	.115
Low cardiac output after open-heart surgery	90 (48.9)	14 (15.56)	76 (84.44)		
Acute pulmonary embolism	5 (2.7)	0 (0)	5 (100)		
Acute myocardial infarction	41 (22.3)	14 (34.15)	27 (65.85)		
Fulminant myocarditis	33 (17.9)	7 (21.21)	26 (78.79)		
Cardiomyopathy	10 (5.4)	1 (10)	9 (90)		
SOFA score	11.29 ± 3.75	12.03 ± 3.81	11.1 ± 3.73	1.322	.188
IE ($\mu\text{g}\cdot\text{kg}^{-1}\cdot\text{min}^{-1}$)	40.71 ± 27.66	48.75 ± 38.1	38.69 ± 24.11	1.510	.139
CPR before ECMO				0.756	.385
Yes	54 (30.2)	13 (24.07)	41 (75.93)		
No	125 (69.8)	23 (18.4)	102 (81.6)		
ECMO duration (hours)	114.23 ± 67.88	120.19 ± 69.47	112.73 ± 67.64	0.579	.565

IE = dopamine ($\mu\text{g}\cdot\text{kg}^{-1}\cdot\text{min}^{-1}$) + dobutamine ($\mu\text{g}\cdot\text{kg}^{-1}\cdot\text{min}^{-1} + 100$) × adrenalin ($\mu\text{g}\cdot\text{kg}^{-1}\cdot\text{min}^{-1} + 100$) × noradrenalin ($\mu\text{g}\cdot\text{kg}^{-1}\cdot\text{min}^{-1} + 15$) × milrinone ($\mu\text{g}\cdot\text{kg}^{-1}\cdot\text{min}^{-1}$), SOFA, Sequential Organ Failure Assessment score

RESULTS

A total of 179 (98 [54.7%] men and 81 [45.3%] women) eligible patients were included in this study. A total of 90 (48.9%) patients had low cardiac output, 41 (22.3%) acute myocardial infarction, and 33 (17.9%) fulminant myocarditis. A total of 40 (22.3%) had hypertension, 23 (12.8%) diabetes, and 12 (6.7%) peripheral artery disease. Eighty-six (48.04%) patients survived to hospital discharge, 36 (20.11%) had limb ischemia, and 42 (23.46%) had incision bleeding. Furthermore, the ECMO-assisted time was 114.23 ± 67.88 hours, as shown in Table 1 and Table 2.

There was no significant difference in age, sex, and Sequential Organ Failure Assessment (SOFA) score between the limb ischemia group and non-limb ischemia group, as shown in Table 2.

Multivariate logistic regression analysis showed that peripheral artery disease was an independent risk factor of limb ischemia in patients with VA ECMO. The risk of limb ischemia in the group with peripheral artery disease was 27.12 times higher than that in the group without peripheral artery disease, as shown in Table 3.

DISCUSSION

In this study, a total of 179 patients were included. Thirty-six patients (20.11%), who received VA ECMO developed limb ischemia. The incidence of limb ischemia in this study was lower than the 33% incidence based on Yen CC et al's study [Yen 2018]. This may be related to the placement of the terminal reperfusion catheters and the use of relatively

Table 3. Results of multivariate logistic regression analysis of limb ischemia-related factors

	B	S.E.	Wals	Sig.	OR	95% of OR value	CI
	Upper limit		Lower limit				
Peripheral artery disease	3.300	0.803	16.870	<0.001	27.115	5.614	130.956
Constant	-4.910	1.564	9.856	0.002	0.007		

small-diameter intubations in all patients in this study. According to the previous studies, in peripheral VA ECMO, the clinical effect of the small cannula strategy is similar to that of large cannula strategy, but the degree of lower limb ischemia is lower in small cannula strategy than in large cannula strategy [Kim 2019]. The large-diameter cannula blocks blood flow, reduces distal limb perfusion, and is at risk of thrombosis. Prophylactic distal perfusion cannula can reduce the incidence of limb ischemia [Ranney 2018; Lamb 2017].

This study showed that there were no statistically significant differences in age, sex, and SOFA score between the limb ischemia group and the non-limb ischemia group. Yau P et al suggested that younger patients and patients with a history of diabetes may have an increased risk of such complications [Yau 2019]. The possible reasons include the following: first, the collateral circulation of young patients still is immature, and second, the diameter of the arteries in young patients was relatively thin and the cannula relatively thick, blocking the blood flow. Diabetes is a proinflammatory state, and microvascular lesions observed in diabetes easily lead to distal limb ischemia, specifically in lesions with low blood flow. Moreover, microvascular and macrovascular changes may result in poor perfusion [Madonna 2011]. The results of this study were inconsistent with the results of the previous studies due to the following reasons: (1) the patients' age in this study was significantly lower than the patients' age reported in the literature, (2) patients with diabetes progressing to severe vascular lesions have not yet been studied, and (3) the preventive placement of the distal perfusion cannula and the selection of small-diameter ECMO cannula in all patients in this study might have affected the result.

This study showed that peripheral artery disease was the independent risk factor of limb ischemia in patients with VA ECMO, a result consistent with the results of Yau P and Bisdas T et al.'s studies [Yau 2019; Bisdas 2011]. Peripheral artery disease is an atherosclerosis-related disease in which the buildup of plaque occurs in the arteries, causing arterial stenosis and occlusion. Atherosclerotic vessels are fragile, and the placement of the ECMO cannula may possibly result in local plaque detachment and embolization, significantly reducing blood flow [Zimpfer 2006; Tanaka 2016]. Therefore, the blockage of blood flow in the ECMO cannulas and the effect of atherosclerosis on vascular stenosis lead to decreased blood supply in the lower limbs, leading to limb ischemia.

This study has the following limitations: (1) This is a single-center retrospective study, and (2) The sample size is

small, and the included variables are not comprehensive and sufficient. Hence, a follow-up polycentric study with a large sample size is required in the future.

CONCLUSION

In conclusion, limb ischemia is a common complication in patients with VA ECMO, and peripheral artery disease is an independent risk factor of limb ischemia in patients with VA ECMO via femoral artery catheterization.

REFERENCES

- Augusto R, Passos S M, Campos J, et al. 2019. Arterial vascular complications in peripheral venoarterial extracorporeal membrane oxygenation support[J]. *Rev Port Cir Cardiorac Vasc* 26(1):45-50.
- Bisdas T, Beutel G, Warnecke G, et al. 2011. Vascular complications in patients undergoing femoral cannulation for extracorporeal membrane oxygenation support[J]. *Ann Thorac Surg* 92(2):626-631.
- Das G J, Saavedra R, Guliani S, et al. 2018. Decompressive laparotomy for a patient on VA-ECMO for massive pulmonary embolism that suffered traumatic liver laceration after mechanical CPR[J]. *J Surg Case Rep* (10):y292.
- Dohain A M, Abdelmohsen G, Elassal A A, et al. 2019. Factors affecting the outcome of extracorporeal membrane oxygenation following paediatric cardiac surgery [J]. *Cardiol Young* 1-9.
- Gulkarov I, Bobka T, Elmously A, et al. 2020. The effect of acute limb ischemia on mortality in patients undergoing femoral venoarterial extracorporeal membrane oxygenation [J]. *Ann Vasc Surg* 62:318-325.
- Hu W, Mao S, Hu W, et al. 2011. ECMO support in a child with acute fulminant myocarditis[J]. *Indian J Pediatr* 78(5):609-612.
- Jayaraman A L, Cormican D, Shah P, et al. 2017. Cannulation strategies in adult veno-arterial and veno-venous extracorporeal membrane oxygenation: Techniques, limitations, and special considerations[J]. *Ann Card Anaesth* 20(Supplement):S11-S18.
- Karami M, den Uil C A, Ouweeneel D M, et al. 2019. Mechanical circulatory support in cardiogenic shock from acute myocardial infarction: Impella CP/5.0 versus ECMO[J]. *Eur Heart J Acute Cardiovasc Care* 1420982051.
- Kaushal M, Schwartz J, Gupta N, et al. 2019. Patient demographics and extracorporeal membranous oxygenation (ECMO)-related complications associated with survival to discharge or 30-day survival in adult patients receiving venoarterial (VA) and venovenous (VV) ECMO in a quaternary care urban center[J]. *J Cardiothorac Vasc Anesth* 33(4):910-917.
- Kawabori M, Mastroianni M A, Zhan Y, et al. 2019. A case series: the

outcomes, support duration, and graft function recovery after VA-ECMO use in primary graft dysfunction after heart transplantation[J]. *J Artif Organs*.

Kim J, Cho Y H, Sung K, et al. 2019. Impact of cannula size on clinical outcomes in peripheral venoarterial extracorporeal membrane oxygenation[J]. *ASAIO J* 65(6):573-579.

Lamb K M, DiMuzio P J, Johnson A, et al. 2017. Arterial protocol including prophylactic distal perfusion catheter decreases limb ischemia complications in patients undergoing extracorporeal membrane oxygenation[J]. *J Vasc Surg* 65(4):1074-1079.

Li Y T, Yang L F, Chen Z G, et al. 2017. ECMO as an effective rescue therapeutic for fulminant myocarditis complicated with refractory cardiac arrest[J]. *Ther Clin Risk Manag* 13:1507-1511.

Lupei M I, Kloesel B, Trillos L, et al. 2019. Survival of intraoperative massive pulmonary embolism using alteplase and VA-ECMO[J]. *J Clin Anesth* 57:112.

Madonna R, De Caterina R. 2011. Cellular and molecular mechanisms of vascular injury in diabetes--part I: pathways of vascular disease in diabetes[J]. *Vascul Pharmacol* 54(3-6):68-74.

McNally M M, Univers J. 2018. Acute limb ischemia[J]. *Surg Clin North Am* 98(5):1081-1096.

Poptsov V, Spirina E, Dogonasheva A, et al. 2019. Five years' experience with a peripheral veno-arterial ECMO for mechanical bridge to heart transplantation[J]. *J Thorac Dis* 11(Suppl 6):S889-S901.

Ranney D N, Benrashid E, Meza J M, et al. 2018. Vascular complications and use of a distal perfusion cannula in femorally cannulated patients on extracorporeal membrane oxygenation[J]. *ASAIO J* 64(3):328-333.

Tanaka D, Hirose H, Cavarocchi N, et al. 2016. The impact of vascular complications on survival of patients on venoarterial extracorporeal membrane oxygenation[J]. *Ann Thorac Surg* 101(5):1729-1734.

Unai S, Khullar V, Elgharably H, et al. 2019. ECMO as a bridge to reoperative cardiac surgery in a patient with cardiogenic shock and severe aortic insufficiency due to an acute aortic valve homograft failure[J]. *Heart Surg Forum* 22(4):E281-E282.

Yau P, Xia Y, Shariff S, et al. 2019. Factors associated with ipsilateral limb ischemia in patients undergoing femoral cannulation extracorporeal membrane oxygenation[J]. *Ann Vasc Surg* 54:60-65.

Yen C C, Kao C H, Tsai C S, et al. 2018. Identifying the risk factor and prevention of limb ischemia in extracorporeal membrane oxygenation with femoral artery cannulation[J]. *Heart Surg Forum* 21(1):E18-E22.

Zimpfer D, Heinisch B, Czerny M, et al. 2006. Late vascular complications after extracorporeal membrane oxygenation support[J]. *Ann Thorac Surg* 81(3):892-895.