

# Tetralogy of Fallot with Double Aortic Arch in an 8-Month-Old Girl: A Rare Association

Huang Feng, Xiaohui Bian, Yuru Lan, Yunfei Ling, Yongjun Qian

Department of Cardiovascular Surgery, West China Hospital, Sichuan University, Chengdu, Sichuan, China

## ABSTRACT

Double aortic arch (DAA) is an extremely rare congenital anomaly that can be divided into right dominant, left dominant, and balanced DAA according to the relative size of the two arches. The incidence of balanced DAA is only 5% among double arch anomalies. DAA is symptomatic only when it produces symptoms secondary to compression of the trachea or esophagus. DAA is rarely associated with other congenital heart diseases. In this report, we present a rare case of asymptomatic DAA combined with Tetralogy of Fallot (TOF) in an 8-month-old girl.

## INTRODUCTION

A vascular ring anomaly of the aortic arch is a rare congenital anomaly that represents approximately 1% of congenital cardiac diseases [Harper 2011]. Double aortic arch (DAA) is the most common type of vascular ring [Van Son 1993] and forms a complete vascular ring encircling the trachea and esophagus. According to the relative size of the two arches, DAA can be divided into three types: right dominant DAA, which comprises 75% of DAA cases; left dominant DAA, which comprises 20% of cases; and balanced DAA, which is seen in only 5% of cases [Liang 2014]. DAA is usually found as an independent anomaly, and only 7-17% of DAA cases coexist with other congenital cardiac anomalies, i.e., ventricular septal defects, atrial septal defects, transposition of the great arteries, patent ductus arteriosus, and Tetralogy of Fallot (TOF) [Alsenaidi 2016; Backer 2005].

In DAA patients, the respiratory and gastrointestinal clinical symptoms are caused by vascular compressions of the trachea and esophagus. DAA patients can present with symptoms such as dyspnea, stridor, feeding difficulty, and dysphagia from a young age [Woods 2001]; however, recognizing asymptomatic DAA is quite difficult. There are still few relevant reports and no consensus on asymptomatic DAA patients. This report describes a case of balanced DAA with TOF presenting without symptoms in an 8-month-old girl.

Received February 27, 2020; accepted June 12, 2020.

Correspondence: Yongjun Qian, No. 37 GuoXue Xiang, Chengdu, Sichuan, 610041, People's Republic of China; +86-28-85422897; fax: +86-28-85422897 (e-mail: [qianyongjun@scu.edu.cn](mailto:qianyongjun@scu.edu.cn)).

## CASE REPORT

An 8-month-old girl was referred to us from a regional hospital due to cyanosis and a heart murmur. At the age of 3 months, she received transthoracic echocardiography (TTE) because of a heart murmur and was diagnosed with TOF and a right aortic arch. The patient was asymptomatic so did not undergo the surgery. Two weeks before admission, she presented with a cough but was soon cured with antibiotics. Her parents denied any history of dyspnea, stridor, or dysphagia. She was referred to our hospital for further evaluation and surgical repair. On physical examination, she showed a normal growth level, at 68 cm, 8 kg, a heart rate of 136 bpm, and respiratory rate of 30 per minute. Lip cyanosis with oxygen saturation of 73% and a grade 3/6 systolic murmur were noted.

On further investigation, TTE showed the usual features of TOF consisting of a 10-mm ventricular septal defect (VSD), infundibular pulmonary artery stenosis with a gradient of 70 mmHg, and 50% overriding of the aorta. Color Doppler images revealed a shunt flow mainly from the right ventricle to the left. Although the patient did not have any symptoms of trachea and esophagus compression, a complete vascular ring formed by DAA was incidentally observed in TTE. The left common carotid artery and the left subclavian artery arose individually from a 7-mm diameter left aortic arch, whereas the right common carotid artery and the right subclavian artery arose individually from a 7-mm diameter right aortic arch. Computed tomography (CT) confirmed the diagnosis of TOF and balanced DAA (Figure 1) and showed left pulmonary 7.8 mm, right pulmonary 7.5 mm, main pulmonary 7.1 mm, McGoon ratio 2.54. The vascular ring surrounded the trachea and esophagus, but there was no obvious compression of the esophagus and trachea (Figure 2).

In view of the clinical features and investigations, we decided to perform a one-stage operation, including TOF repair and left aortic arch dissection. Following midline sternotomy, a cardiopulmonary bypass was established using aortic and bicaval cannulation. The left arch was divided distally to the left subclavian artery, and both stumps were sutured in two layers with 5/0 polypropylene sutures. Clamps were carefully released to ensure no hemorrhaging. After aortic cross-clamping and cold blood cardioplegia, we performed TOF repair, consisting of VSD closure, transannular enlargement of the right ventricular outflow tract, and infundibular muscle resection. Postoperative TEE showed no residual shunting

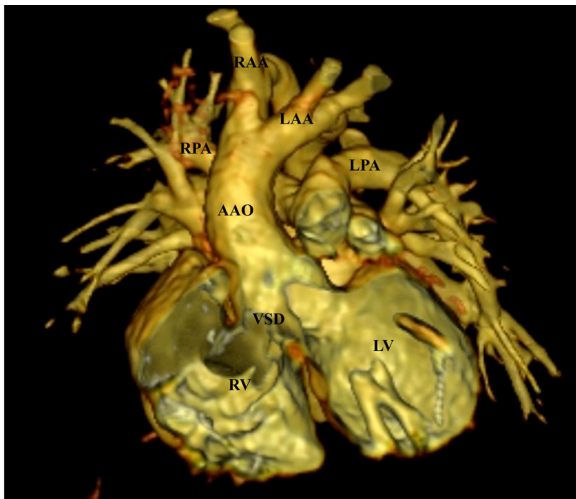


Figure 1. Computerized tomogram (CT) thorax revealed VSD, overriding of the aorta, and balanced DAA. AAO: ascending aorta; VSD: ventricular septal defect; LV: left ventricle; RV: right ventricle; LPA: Left pulmonary artery; RPA: Right pulmonary artery; RAA: Right aortic arch; LAA: Left aortic arch.

and mild tricuspid regurgitation. The patient was discharged the day after operation with no complications.

## DISCUSSION

In DAA patients, each arch gives rise to the common carotid and subclavian arteries, which then join to form the descending aorta, completely surrounding the trachea and/or esophagus. Compression of the trachea and/or esophagus may produce respiratory symptoms and gastrointestinal symptoms in 91% and 40% of DAA patients, respectively [Backer 2005]. In a retrospective study including 148 patients with isolated complete vascular rings, Binsalimah et al (2020) reported respiratory symptoms consisting of stridor in 34%, persistent cough in 34%, wheezing in 22%, exercise intolerance in 8%, and cyanosis in 3% of DAA patients. Less frequently, DAA can present without symptoms, as described in this case. TOF is the most common cyanosis congenital heart disease and presents with exertional dyspnea, cyanosis, and recurrent pulmonary infection. When DAA coexists with TOF, the respiratory symptoms of DAA may be disguised by TOF, and DAA with or without mild stridor or dyspnea may be overlooked preoperatively [Li 2013]. In our case, we incidentally detected asymptomatic DAA when evaluating the associated TOF; therefore, it is important to recognize asymptomatic DAA before operating.

In terms of DAA diagnosis, echocardiography is usually used to initiate the diagnostic process. However, echocardiography has several obvious disadvantages: (1) the imaging quality of the aortic arch may be affected by the

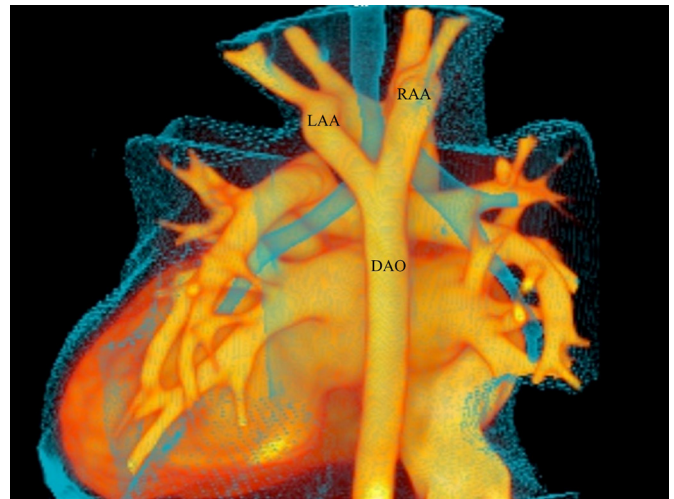


Figure 2. Computerized tomogram (CT) thorax showed the balanced aortic arch without narrowing of the trachea. DAO: descending aorta; RAA: right aortic arch; LAA: left aortic arch.

sternum, ribs, and pulmonary air; (2) an atretic aortic arch and arterial ligaments cannot be accurately diagnosed by echocardiography; and (3) echocardiography cannot evaluate the acute degree of vascular compression of the trachea and/or esophagus [Chen 2014]. Harper et al reported a case of DAA that was missed by echocardiography and then detected incidentally by CT [Harper 2011]. In our case, the patient was diagnosed as having a right aortic arch on preliminary echocardiography, but the diagnosis was corrected to DAA at the second echocardiography. Once the left or right aortic arches are detected by ultrasound, DAA should be highly suspected and further investigated [Yang 2019]. CT angiography and magnetic resonance imaging can safely and accurately visualize abnormal vascular branches, compression structures, and associated cardiac anatomy [Madry 2019].

Asymptomatic DAA with TOF is an extremely rare congenital cardiac disease, of which only a handful of cases have been reported in the literature [Li 2013; Kasaliwal 2014; Haranal 2020]. Symptoms of tracheal and esophageal compression are the standard indication for surgical repair, however, there is still no consensus on the management of asymptomatic DAA cases. A case reported by Loomba [2016] suggests that clinical observation and regular follow-up of asymptomatic or mild symptomatic vascular rings are safe strategies. But in a retrospective observational study of congenital vascular rings, some asymptomatic nonoperative patients eventually developed symptoms [Lodeweges 2019]. Thus, in our case, we relieved the vascular ring to prevent further development of respiratory and gastrointestinal complications.

In summary, an 8-month-old girl with TOF was incidentally found to have balanced DAA by echocardiography. She did not show any symptoms of tracheal or esophageal compression. A one-stage operation, consisting of TOF repair and left aortic arch dissection, was performed successfully.

## REFERENCES

- Alsenaidi K, Gurofsky R, Karamlou T, Williams WG, McCrindle BW. 2016. Management and outcomes of double aortic arch in 81 patients. *Pediatrics* 118:e1336-41.
- Backer CL, Mavroudis C, Rigsby CK, Holinger LD. 2005. Trends in vascular ring surgery. *J Thorac Cardiovasc Surg* 129:1339-47.
- Binsalamah ZM, Ibarra C, John R, et al. 2020. Contemporary midterm outcomes in pediatric patients undergoing vascular ring repair. *Ann Thorac Surg* 109:566-72.
- Chen X, Qu Y, Peng ZY, Lu J, Ma X, Hu W. 2014. Clinical value of multi-slice spiral computed tomography angiography and three-dimensional reconstruction in the diagnosis of double aortic arch. *Experimental and therapeutic medicine* 8:623-7.
- Haranal M, Abdul Latiff HB, Sivalingam S. 2020. Asymptomatic balanced double aortic arch associated with tetralogy of fallot. *World J Ped Congenital Heart Surg* 11:130-2.
- Harper AR, Dai M, Prabhatha RM. 2011. Tetralogy of Fallot with double aortic arch. *Cardiol in the Young* 21:695-6.
- Kasaliwal R, Sarathi V, Pandit R, et al. 2014. Pheochromocytoma and tetralogy of Fallot: a rare but potentially dangerous combination. *Endocr Pract* 20:e80-5.
- Li ZQ, Liu AJ, Li G, Liu Y, Zhu YB, Liu YL. 2013. Two cases of a rare association: double aortic arch with tetralogy of Fallot. *J Cardiothor Surg* 8:39.
- Liang Y, Zhou Q, Chen Z. 2014. Double aortic arch with ascending aortic aneurysm and aortic valve regurgitation. *Ann Thorac Surg* 97:e43-5.
- Lodeweges JE, Dikkers FG, Mulder BJM, et al. 2019. The natural and unnatural history of congenital aortic arch abnormalities evaluated in an adult survival cohort. *Canadian J Cardiol* 35:438-45.
- Loomba RS. 2016. Natural history of asymptomatic and unrepaired vascular rings: is watchful waiting a viable option? A new case and review of previously reported cases. *Children* 3:44.
- Madry W, Karolczak MA, Myszkowski M, Zacharska-Kokot E. 2019. Non-invasive diagnosis of aortic arch anomalies in children - 15 years of own experience. *J Ultrasonography* 19:5-8.
- Van Son JAM, Julsrud PR, Hagler DJ, et al. 1993. Surgical Treatment of Vascular Rings: The Mayo Clinic Experience. *Mayo Clinic Proceedings* 68:1056-63.
- Woods RK, Sharp RJ, Holcomb GW 3rd, et al. 2001. Vascular anomalies and tracheoesophageal compression: a single institution's 25-year experience. *Ann Thorac Surg* 72:434-8; discussion 438-9.
- Yang Y, Jin X, Pan Z, Li Y, Wu C. 2019. Diagnosis and surgical repair of congenital double aortic arch in infants. *J Cardiothorac Surg* 14:160.