

Total Arch Replacement with Concomitant Retrograde Stent Graft Deployment via Ministernotomy in Acute Aortic Dissection

Tien Quyet Tran, An Thai Nguyen

Cardiac surgery Department, Cho Ray Hospital, Ho Chi Minh City, Viet Nam

ABSTRACT

Background: Acute aortic dissection is one of the most fatal conditions, with high surgical risks and severe postoperative complications. Treatment modalities vary from center to center, and a total arch replacement sometimes is not sufficient to provide a good result. Frozen elephant trunk (FET) offers a good option for a more complete repair. Because of its complexity and expense, however, this excellent technique is not always available. In this article, we present our hybrid technique including total arch replacement and retrograde thoracic endovascular aortic repair (TEVAR) for acute aortic dissection via a ministernotomy.

Objective and methods: Our study aimed to estimate the safety, early results, and some midterm outcomes of total arch replacement in combination with retrograde TEVAR for acute aortic dissection from August 2013 to May 2017. We analyzed the intraoperative variables (duration of cross-clamp, circulatory arrest, ventilation, and intensive care unit stay), 30-day mortality, and early complications as well as the midterm results of these patients.

Results: From August 2013 to May 2017, 22 patients (17 male) diagnosed with acute aortic dissection were treated with total arch replacement and concomitant retrograde endovascular repair via an upper ministernotomy. Mean age (\pm SD) was 60.8 ± 10.7 years. Thirty-day mortality was 4.5%: 1 patient died of acute renal failure. One patient had a postoperative stroke. The average number of stents used intraoperatively was 1.83. Midterm mortality was 1 patient (4.5%). Complete thrombosis of the false lumen in the thoracic aorta was achieved in 18 patients (90%).

Conclusions: Retrograde TEVAR in combination with total arch replacement via an upper ministernotomy might be safe and effective in treating acute type A aortic dissection, with fairly low mortality and perioperative complications, and a very good rate of total false lumen thrombosis in midterm follow up.

INTRODUCTION

Acute aortic dissection is the most frequent and fatal condition of the acute aortic syndrome, with an incidence of ≥ 30

patients per million people per year [Criado 2011]. Anatomically, it is described as types A and B according to the Stanford Classification [Daily 1970]. Regarding the natural history of this disease without treatment, Hirst [1958] reported that mortality of untreated acute type A dissection in the first 24 h was 21%; at 48 h, 38%; and at 7 days, 62%. Acute dissection is considered when the symptoms have started ≤ 14 days previously. From 2 weeks to 3 months, the disease is classified as subacute; for >3 months, it is categorized as chronic dissection.

Because of the high natural mortality and severe complications, such as cardiac tamponade, acute aortic regurgitation, stroke, and myocardial infarction, acute type A dissection is a surgical emergency. Surgical mortality at experienced aortic centers varies from 7% to 36% [Black 2018]. The standard treatment of acute type A dissection is ascending aorta (or hemiarch) replacement and total arch replacement, depending on the position of the primary entry tear (tear-oriented strategy) [Yamamoto 2019].

Recently, the frozen elephant trunk technique has been applied to reinforce the distal anastomosis and enhance false lumen (FL) thrombosis. With this novel technique, the FL thrombosis rate is significantly higher compared with conventional elephant trunk and hemiarch or total arch replacement [Uchida 2009; Di Bartolomeo 2017]. However, frozen elephant trunk prostheses are not always available, particularly in Third World countries. Hence, finding another option to solve this problem is important to provide better care for our patients. Descending aorta stent grafting, antegrade fashion in an open

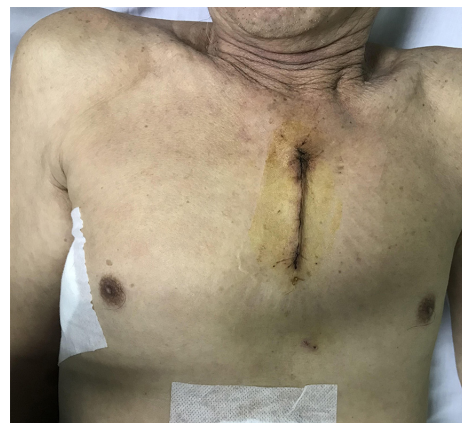

Figure 1. Skin incision.

Received December 7, 2019; received in revised form February 7, 2020; accepted February 7, 2020.

Correspondence: Tien Quyet Tran, 201B Nguyen Chi Thanh, ward 12, District 5, Ho Chi Minh City, Viet Nam (e-mail: tienchoray@yahoo.com).

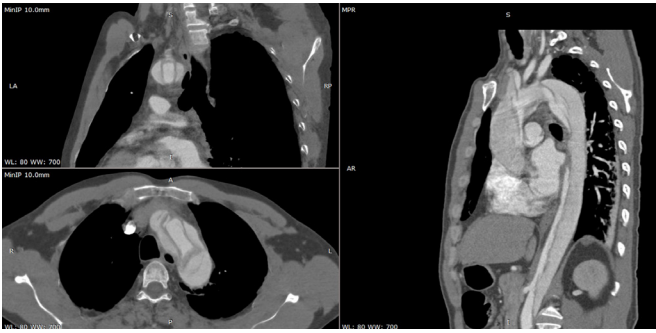


Figure 2. Preoperative CT scan showing acute type A dissection.

anastomosis, or retrograde deployment using the C-arm system, has been proven to be efficient and feasible and to provide a very good outcome [Hofferberth 2013; Vallabhajosyula 2014].

In this study, we assessed the short-term results and some midterm outcomes of total arch replacement in combination with retrograde descending aorta stent grafting via an upper ministernotomy in acute type A aortic dissection.

METHODS

Between August 2013 and May 2017, 22 patients with acute type A dissection underwent total arch replacement and retrograde thoracic endovascular aortic repair (TEVAR) via an upper ministernotomy in Cho Ray Hospital, Ho Chi Minh City, Viet Nam. Patients with suspected concomitant coronary artery disease, mitral valve disease, or other cardiac malformation that required operation did not receive the ministernotomy and thus were excluded. Our primary outcome was 30-day mortality and postoperative complications.

Perioperative information was collected and analyzed prospectively. Contrast-enhanced computed tomography (CT) scans were performed before discharge, at 1 and 6 months, and every 6 months thereafter to assess the rate of FL thrombosis.

Surgical Technique

The patient was transferred immediately to the operating theater when type A dissection was confirmed. After general anesthesia, transesophageal echocardiography (TEE) was carried out to evaluate the aortic valve and aortic root. If there were no other cardiac conditions that required repair (eg, severe mitral regurgitation), an upper ministernotomy was indicated. The patient was placed in a supine position with a cushion between 2 scapulae to facilitate the exposure of the the aortic root, ascending aorta, and arch.

An L-shaped upper ministernotomy was performed in the usual manner (Figure 1). The fatty tissue of the thymus was completely removed to provide good exposure of the arch branches. The innominate vein was exposed and retracted using fabric tape. The brachiocephalic trunk, the left common carotid artery, and the left subclavian artery were successively

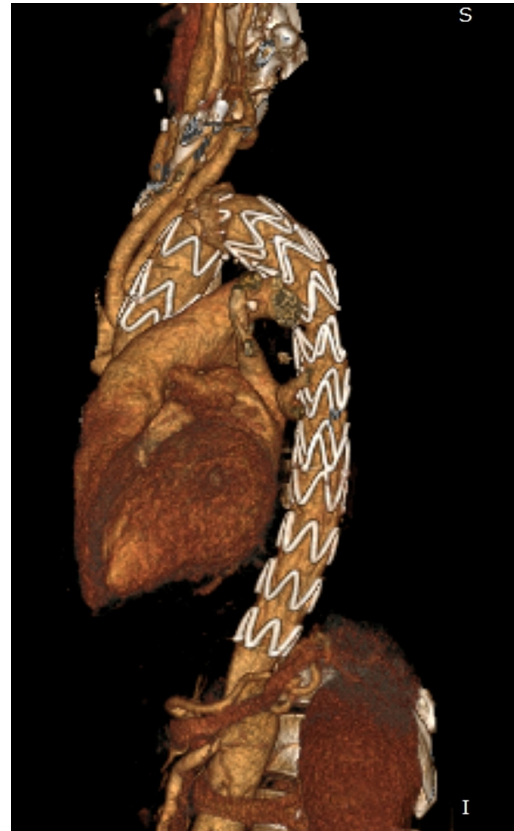

Figure 3. Follow-up CT scan 1 year after surgery.

exposed and controlled with rubber tape. For a quick establishment of cardiopulmonary bypass in these patients, the femoral artery and vein were used. A 2-stage venous cannula was routinely used, and a negative pressure of -40 mmHg was applied to provide a good venous return and a well-exposed surgical field. Left ventricular venting was accomplished via the superior right pulmonary vein. Core temperature was reduced to 24°C .

During the cooling phase, the ascending aorta was dissected toward the aortic root. When the heart started fibrillating, aortic cross-clamp was applied, and cold blood cardioplegia was given directly through the coronary ostia. At this phase, aortic root reconstruction (Bentall or Tirone David procedure) was conducted; if these procedures were not necessary, the proximal aorta was reinforced with inside and outside Teflon strips using intermittent 4/0 polypropylene suture to prepare for a solid proximal anastomosis.

In the meantime, a 3-branched graft was manually made using an abdominal Y prosthesis (Vascutek, Terumo Medical Corp., Somerset, NJ) by cutting an iliac branch and reimplanting it to 1 branch of the graft. This handmade prosthesis served as the arch replacement graft and would be anastomosed later to the main graft at the level of the ascending aorta, proximal to the aortic root.

Once core temperature reached 24°C , hypothermic circulatory arrest was performed, and the brachiocephalic

Table 1. Demographic Characteristics (N = 22)

Variable	Value
Age (y)	60.8 ± 10.7
Male:Female	17:5
Diabetes mellitus	8 (36.4)
Hypertension	21 (95.5)
Renal failure	9 (40.9)
Myocardial infarction	1 (4.5)
Preoperative stroke	1 (4.5)
Marfan syndrome	3 (13.6)
Severe aortic valve regurgitation	1 (4.5)

Data are mean ± SD or n (%) unless noted otherwise.

trunk, left common carotid artery, and left subclavian artery were separated completely from the arch. Direct antegrade cerebral perfusion was applied and monitored by the INVOS system (Medtronic, Minneapolis, MN), as well as bilateral radial artery pressure. The distal aorta was reinforced with a double-layer Teflon strip, and anastomosis with a Dacron graft was performed using polypropylene 3/0. The patient was rewarmed, and the proximal anastomosis was carried out with polypropylene 3/0. The heart was de-aired, and the cross-clamp was removed. The handmade 3-branched graft was then sutured to the Dacron graft near the aortic root to provide a good landing zone for the stent graft. The arch branches were reconstructed by suturing to the 3-branched graft with Prolene 5.0. Cardiopulmonary bypass was weaned, and protamine was given. Drainage and sternum closure were performed in the usual manner.

Stent Graft Deployment

The endovascular phase was started after skin closure, using an intraoperative C-arm system. The bigger common femoral artery was exposed, and a 260-cm hydrophilic guide-wire (Terumo Medical Corp., Tokyo, Japan) was used to access the true lumen under guidance of fluoroscopy and TEE. A Lunderquist Extra Stiff wire (Cook Medical, Bloomington, IN) was then exchanged, and a thoracic stent graft (Zenith TX2 Dissection Endograft, Cook Medical; Valiant Captivia Closed Web, Medtronic) was then advanced over the guide-wire and deployed with a minimum 2.0-cm landing zone on the aortic graft. We did not oversize the stent graft in the distal landing zone, to avoid creating secondary entry tears. Additional stent graft deployment was carried out to the level of the celiac trunk.

Follow-Up Imaging

Contrast-enhanced CT was performed before discharge, 6 months after the procedure, and annually afterward (Figure 2) or when the patient developed symptoms related to the aorta (chest pain, dyspnea on exertion, syncope, etc).

RESULTS

Demographic Characteristics

From August 2013 to May 2017, 22 patients diagnosed with acute aortic dissection were treated with aortic arch replacement in combination with retrograde endovascular treatment. Patient demographic data are summarized in Table 1.

Intraoperative Variables and Early Postoperative Outcome

Intraoperative variables and early postoperative outcome are described in Table 2. All stent graft deployments were technically successful; 1 Tirone David as adjunctive procedure was also performed. One patient died in the intensive care unit (ICU) from permanent stroke, causing prolonged ventilation and severe sepsis that did not respond to antibiotic treatment. 1 patient needed sternotomy conversion owing to uncontrolled bleeding.

Midterm Outcome

Mean follow-up time (± SD) was 35.6 ± 22.1 months. Midterm mortality was 1 patient (4.5%): the patient died at home without any significant suggestive symptoms. Follow-up contrast-enhanced CT was performed on 20 patients, and complete thrombosis of the false lumen in the thoracic aorta was achieved in 18 patients (81%). Two patients had partial patent false lumen due to distal secondary entry tears; however, they patients refused further intervention, and therefore optimal medical treatment was chosen. No type I endoleak, stroke, or organ malperfusion syndromes were recorded during follow-up.

DISCUSSION

Acute type A dissection is a severe condition with high natural mortality. According to The International Registry of Acute Aortic Dissection (IRAD), 90% of type A dissections managed surgically [Pape 2015]. Despite improvements in treatment modalities, this disease is still challenging, with fairly high surgical mortality and postoperative complications [Black 2018]. Because of the emergency state of the patient and the high surgical risks, the standard surgical approach for type A dissection is usually limited to a simple ascending aortic replacement, with resection of the primary entry tear to prevent coronary occlusion, aortic rupture, and subsequent cardiac tamponade [Di Bartolomeo 2016]. This type of approach might bring a relatively good short-term result. However, the dissection in the arch and the remaining aorta are left untouched, thus creating the risk of subsequent false lumen aneurysm possibly leading to rupture, true lumen compression, and malperfusion syndrome.

Fattori et al assessed the evolution of the residual false lumen after surgical repair of type A dissection. Only 22.5% of patients were found to have complete thrombosis of the false lumen; partial thrombosis was visualized in 41.3% and 36.2% stayed completely patent. The growth rate was significantly faster in the patent FL group (0.56 ± 0.57 versus 0.11 ±

Table 2. Intraoperative Variables and Postoperative Outcome (N = 22)

Variable	Value
Intraoperative variables	
Cardiopulmonary bypass time (min)	206 ± 76
Cross-clamp time (min)	108 ± 42
Deep hypothermic circulatory arrest (min)	31.2 ± 9
Mechanical ventilation time (hours)	49 ± 11
ICU time (d)	4.7 ± 4
Postoperative hospital stay (d)	12 ± 5
Average number of stents deployed	1.83
Postoperative outcomes	
Mortality	1 (4.5)
Myocardial infarction	0 (0)
Stroke	1 (4.5)
Sternotomy conversion	1 (4.5)
Reoperation for bleeding	3 (13.6)
Renal failure requiring dialysis	1 (4.5)
Pneumonia and prolonged ventilation	7 (31.8)

Data are mean ± SD or n (%) unless noted otherwise.

0.17 cm, $P < .05$). In chronic type B dissection, the descending aorta expanded more commonly and more rapidly than other parts, with independent predictors for late aneurysm forming including enlarged aortic diameter, high blood pressure, and a patent false lumen [Zierer 2007].

Recently, to solve the problematic patent false lumen, several hybrid techniques have been advocated, including antegrade stent graft deployment, retrograde stent graft deployment, and particularly the frozen elephant trunk procedure. Since its first description by Kato et al. [1996], short- and long-term hybrid techniques have been widely published, with similar short-term outcomes and a better aortic remodeling process [Yamamoto 2019; Vallabhajosyula 2014; Shrestha 2017].

Anterograde stent graft deployment and frozen elephant trunk are identical technically. Both techniques share the principle of deploying a stent graft into the true lumen during deep hypothermic circulatory arrest. In acute dissection, the graft should not be oversized, to avoid creating a new entry site at the tip of the device [Shrestha 2017]. Although this method was initially used for acute type A dissection with malperfusion syndrome, it is being widely performed depending on the surgeon's experience and preferences [Vallabhajosyula 2014]. One big advantage of antegrade stent deployment and frozen elephant trunk methods is the proximalization of the distal anastomosis, which might facilitate exposure and hemostasis, particularly when total arch replacement is performed and the distal anastomosis locates on the proximal part of the descending aorta. Second, with a stent graft inside the true lumen, the distal part of the aorta becomes well reinforced

and allows creation of a solid anastomosis in the fragile tissue. Third, with the reestablishment of the true lumen, the proximal part of the false lumen is significantly decompressed, decreasing the risk of false lumen bleeding and tearing after reinitiating antegrade cardiopulmonary bypass flow. With the frozen elephant trunk technique, Shrestha [2017] suggested using a 100-mm graft, believing this length to be enough to stabilize the dissected aorta and avoid spinal cord ischemia.

Nevertheless, this approach has some disadvantages. Deploying the stent graft through an open anastomosis might not be easy, particularly controlling the distal part. The stent might be deployed into the false lumen through a reentry that could not be seen through the anastomosis. Furthermore, in developing countries, frozen elephant trunks are very expensive, and the expenses are not covered by social insurance. For these reasons, this technique is still somewhat unavailable in many regions.

Our study investigates the feasibility of a more complete endovascular treatment of the dissected descending aorta in combination with a ministernotomy. By the retrograde stent graft deployment technique, we still keep the advantage of proximalization of the distal anastomosis, regardless of the primary entry tear position. The anastomosis is performed before the origin of the left common carotid artery, making hemostasis easier. By using the C-arm system and TEE and guiding the device on a stiff guidewire, we can make sure the stent graft is correctly delivered to the replaced ascending aorta in the true lumen and in a safe manner. Another advantage of the retrograde approach is the complete deployment to the celiac trunk. By this technique, our data show a very good rate of total thrombosis of the false lumen in the descending aorta. This is one reason we prefer retrograde to anterograde deployment. In this small series, no patient had spinal cord ischemia. Hofferberth [2013] also showed a very good result, with no spinal cord ischemia in the hybrid group (retrograde endovascular repair) compared with the conventional group.

The benefits of the minimal approach via an upper ministernotomy include less operative pain, reduced blood loss and transfusion requirements, fewer infections and mediastinitis, and reduced length of ICU stay and hospital stay (LOS) [Perrotta 2009; Bonacchi 2002]. In our series, only 1 case needed conversion to full sternotomy (4.5%). With the advantage of the distal anastomosis proximalization, this approach offers a very good surgical view: we did not encounter any difficulty in constructing the anastomosis at the level of the left carotid artery or exposure of the left subclavian artery.

In conclusion, retrograde TEVAR in combination with total arch replacement via an upper ministernotomy might be safe and effective in treating acute type A aortic dissection, with fairly low mortality and perioperative complications and a very good rate of total false lumen thrombosis in midterm follow-up.

REFERENCES

Black JH III, Manning WJ. Management of acute aortic dissection. UpToDate, Collins KA, ed. UpToDate, Waltham, MA: UpToDate Inc.

<https://www.uptodate.com/contents/management-of-acute-aortic-dissection> (Accessed on January 11, 2018).

Bonacchi M, Prifti E, Giunti G, Frati G, Sani G. Does ministernotomy improve postoperative outcome in aortic valve operation? A prospective randomized study. *Ann Thorac Surg* 2002;73:460-465; discussion 465-466.

Criado FJ. Aortic dissection: A 250-year perspective. *Tex Heart Inst J* 2011;38:694-700.

Daily PO, Trueblood HW, Stinson EB, Wuerflein RD, Shumway NE. Management of acute aortic dissections. *Ann Thorac Surg* 1970;10:237-247.

Di Bartolomeo R, Leone A, Di Marco L, Paciniet D. When and how to replace the aortic arch for type A dissection. *Ann Cardiothorac Surg* 2016;5:383-388.

Di Bartolomeo R, Murana G, Di Marco L, et al., Frozen versus conventional elephant trunk technique: application in clinical practice. *Eur J Cardiothorac Surg* 2017;51(suppl 1):i20-i28.

Fattori, R., Bacchi-Reggiani L, Bertaccini P, et al. Evolution of aortic dissection after surgical repair. *Am J Cardiol* 2000;86:868-872.

Hirst AE Jr, Johns VJ Jr, Kime SW Jr. Dissecting aneurysm of the aorta: A review of 505 cases. *Medicine (Baltimore)* 1958;37:217-279.

Hofferberth SC, Newcomb AE, Yii MY, Yap KK, Boston RC, Nixon IK, Mossop PJ. Hybrid proximal surgery plus adjunctive retrograde endovascular repair in acute DeBakey type I dissection: Superior outcomes to conventional surgical repair. *J Thorac Cardiovasc Surg* 2013;145:349-354; discussion 354-355.

Kato M, Ohnishi K, Kaneko M, et al. New graft-implanting method for thoracic aortic aneurysm or dissection with a stented graft. *Circulation* 1996;94(9 suppl):II188-II193.

Pape LA, Awais M, Woznicki EM, et al. Presentation, diagnosis, and outcomes of acute aortic dissection: 17-Year trends from the International Registry of Acute Aortic Dissection. *J Am Coll Cardiol* 2015;66:350-358.

Perrotta S, Lentini S. Ministernotomy approach for surgery of the aortic root and ascending aorta. *Interact Cardiovasc Thorac Surg* 2009;9:849-858.

Shrestha M, Martens A, Kaufeld T, et al. Single-centre experience with the frozen elephant trunk technique in 251 patients over 15 years. *Eur J Cardiothorac Surg* 2017;52:858-866.

Uchida N, Shibamura H, Katayama A, Shimada N, Sutoh M, Ishihara H. Operative strategy for acute type a aortic dissection: Ascending aortic or hemiarch versus total arch replacement with frozen elephant trunk. *Ann Thorac Surg* 2009;87:773-777.

Vallabhajosyula P, Szeto WY, Pulsipher A, et al., Antegrade thoracic stent grafting during repair of acute DeBakey type I dissection promotes distal aortic remodeling and reduces late open distal reoperation rate. *J Thorac Cardiovasc Surg* 2014;147:942-948.

Yamamoto H, Kadohama T, Yamaura G, et al. Total arch repair with frozen elephant trunk using the "zone 0 arch repair" strategy for type A acute aortic dissection. *J Thorac Cardiovasc Surg* 2019:S0022-5223(19)30360-5.

Zierer A, Voeller RK, Hill KE, Kouchoukos NT, Damiano RJ Jr, Moon MR. Aortic enlargement and late reoperation after repair of acute type A aortic dissection. *Ann Thorac Surg* 2007;84:479-486; discussion 486-487.