

Successful Treatment of Right Ventricular Thrombus with Heparin and Sodium Warfarin Therapy: A Case Report

Azman Ates, MD,¹ Serdar Sevimli, MD,² Bilgehan Erkut, MD¹

Departments of ¹Cardiovascular Surgery and ²Cardiology, Faculty of Medicine, Ataturk University, Erzurum, Turkey

ABSTRACT

A 75-year-old woman came to our emergency clinic complaining of abdominal pain. Acute cholecystitis was diagnosed, and parenteral antibiotic therapy was initiated. Because of palpitation, she had a consultation with the cardiology clinic. Echocardiography showed a 2.7 × 2.2 cm mobile thrombus attached to the apex of the right ventricle. Since no thromboembolic complications were present, we decided to begin administering heparin and oral anticoagulant. After the administration of unfractionated heparin for 48 hours, the patient was shifted to low-molecular weight heparin because it is easier to use and requires no follow-up. The patient received low-molecular weight heparin in addition to sodium warfarin for 5 days. Administration of heparin was then stopped and treatment was continued with sodium warfarin. In the series of weekly echocardiography evaluations, a gradual reduction was noted in the apical mass, which was initially considered to be a thrombus, and 3 weeks later evaluation revealed that the thrombus in the right ventricle had disappeared completely. No thromboembolic complications were observed during the follow-up period.

INTRODUCTION

Right ventricular thrombus is a very rare condition, but it has clinical importance because it can result in pulmonary embolism [Torbicki 2003]. Although there are many reports in the literature about the treatment of right ventricular thrombi in the presence of pulmonary embolism, we could find only a few published reports on the treatment of isolated right ventricular thrombus [Chartier 1999; Yeh 2000]. The recommended treatment of right ventricular thrombus is to use more radical treatment modalities, such as surgery and thrombolytic therapy, because right ventricular thrombus is

generally complicated by pulmonary embolism. There were also a few case reports on thrombus disappearing after treatment with sodium warfarin and heparin [Calvo 1990]. In our report, we sought to present a case of isolated right ventricular thrombus successfully treated in a short time with heparin and sodium warfarin therapy and to attract attention to the clinical importance of this condition.

CASE REPORT

A 75-year-old woman applied to our emergency clinic complaining of abdominal pain. During her physical examination, her blood pressure was 130/70 mmHg and heart rate was rhythmic and 80 beats/min. There was tenderness at palpation in the upper right abdominal quadrant. Electrocardiography revealed normal sinus rhythm. The cardiothoracic ratio was within normal limits at telecardiography.

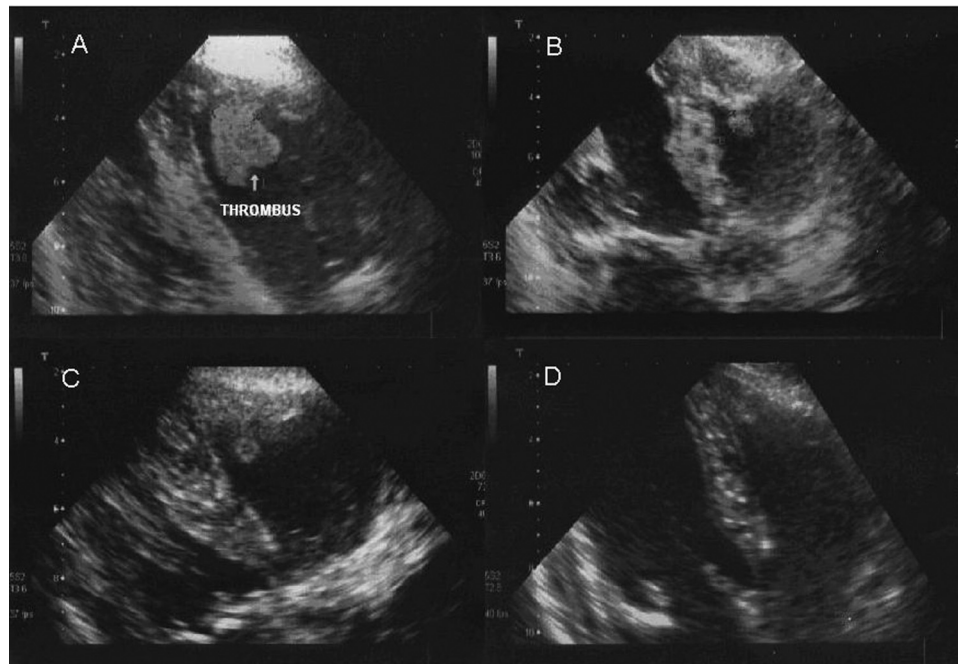
She was given a diagnosis of acute cholecystitis and was hospitalized in the General Surgery Department; parenteral antibiotic therapy was initiated. Symptoms of the patient improved; however, upon the emergence of palpitation 48 hours later, consultation was required from the cardiology clinic.

Echocardiography was performed and revealed an image consistent with a 2.7 × 2.2 cm mobile thrombus attached to the apex of the right ventricle with a broad base (Figure, A). Functions of the right and left ventricles were normal. There were no findings consistent with pulmonary embolism. Venous Doppler ultrasonography of the lower extremity and perfusion-ventilation scanning of the lungs were normal. Hematological values of the patient were within normal ranges: hemoglobin, 14 g/dL; white blood cell count, 9000/mm³; platelet counts, 300,000/mm³; erythrocyte sedimentation rate, 20 mm/h. Kidney and liver functions were normal. C-reactive protein level was within normal ranges. Tests for antinuclear antibodies and anti-DNA were negative. Tests of pathergy and HLA-B5 performed to determine Behcet's disease were found to be negative. Levels of protein C and S were within normal ranges.

Since no thromboembolic complications were present, we decided to begin administering heparin and oral anticoagulant. Unfractionated heparin was initiated at doses recommended for the treatment of pulmonary embolism; ie, 5000 IU intravenous bolus followed by 1000 IU/h infusion [Task Force of

Received September 14, 2006; received in revised form October 16, 2006; accepted October 17, 2006.

Correspondence: Azman Ates, MD, Ataturk Üniversitesi Lojmanlari, 25/7, 25240 Erzurum, Türkiye; 9-0442-231-3203; fax: 9-0442-316-6340 (e-mail: azmanates@yahoo.com).



A, The thrombus in the right ventricle apex at the beginning. B, The thrombus decreased at the end of the first week. C, The thrombus clearly reduced at the end of the second week. D, The thrombus completely resolved at the end of the third week.

Pulmonary Embolism 2000]. The heparin infusion dose was adjusted so that the level of activated partial thromboplastin time would be 1.5 to 2 times higher than normal. After the administration of unfractionated heparin for 48 hours, the patient was shifted to low-molecular weight heparin because it is easier to use and requires no follow-up. Sodium warfarin therapy was started at 5 mg/day synchronously with heparin to maintain an international normalized ratio (INR) between 2 and 3. The patient received low-molecular weight heparin in addition to sodium warfarin for 5 days.

The administration of heparin was then stopped and treatment was continued with sodium warfarin to maintain an INR between 2 and 3. In the series of weekly echocardiography evaluations, a gradual reduction was noted in the apical mass, which was initially considered to be a thrombus (Figure, B and C). Echocardiography evaluation, which was performed 3 weeks later, revealed that the thrombus in the right ventricle had disappeared completely (Figure, D). No thromboembolic complications were observed during the follow-up period.

DISCUSSION

A thrombus in the right side of the heart and particularly of the right ventricle is a very rare condition. The diagnosis generally depends on echocardiography evaluation that is performed in patients who are suspected to have pulmonary embolism [Torbicki 2003]. The number of diseases that have the potential of causing thrombus formation in the right ventricle is considerably high. Procedures and events that lead to trauma of the right side of the heart, such as implantation of

lead pacemakers, insertion of central catheters via the cava vein for parenteral nutrition, dysplasia of the right ventricle that leads to arrhythmia, metastases of malign diseases to the endocardium of the right ventricle, and thorax traumas, may impair structural characteristics of right ventricular endocardium, slow down blood flow, and cause thrombus formation [Doireau 1993]. Moreover, certain diseases, such as familial heparin II cofactor defect, heparin-induced thrombocytopenia, antiphospholipid antibody syndromes, and factor V Leiden mutation may lead to hypercoagulability states and aid the development of right ventricular thrombi [Schneider 2003]. The reason for the development of right ventricular thrombus in Behcet's disease is endocardial injury due to vasculitis [Baykan 2001].

Two-dimensional transthoracic echocardiography evaluation is the basis of diagnosis in right ventricular thrombus. The structure, dimensions, shape, movements, and relations of the thrombus to the ventricle are clearly seen with echocardiography. Moreover, the changes that will develop in the thrombus in response to treatment may also be evaluated with echocardiography examinations. Cardiac tomography, perfusion-ventilation scanning of the lungs, and pulmonary angiography may be performed when a pulmonary embolism is suspected [Task Force on Pulmonary Embolism 2000]. Venous Doppler ultrasonographic evaluation of lower extremities should be performed in patients with right ventricular thrombus to eliminate thrombi that originate from deep veins.

Laboratory evaluations directed at determining conditions that constitute the basis for the formation of right ventricular thrombus in these patients include basal function tests of the liver and kidneys, white blood cell count, erythrocyte

sedimentation rate, platelet count, heparin cofactor II antigen levels, C-reactive protein, anticardiolipin antibodies, antinuclear antibodies, anti-DNA, prothrombin time, clotting time, bleeding time and factor levels (if necessary), and protein C and S levels. It is important to evaluate patients in terms of Behcet's disease that is characterized with oral and genital ulcers. Serial follow-up of patients with Behcet's disease in terms of cardiac involvement has been recommended in the light of reports in the literature [Baykan 2001].

Since right ventricular thrombi are generally complicated with pulmonary embolism, the treatment modality should be determined according to concurrence of pulmonary embolism. Although thrombolysis or surgery is the choice of treatment when a massive or sub-massive pulmonary emboli is concurrent [Chartier 1999; Task Force on Pulmonary Embolism 2000], therapeutic preference in cases of small pulmonary emboli or uncomplicated and isolated right ventricular thrombi that are incidentally determined at echocardiography is not clear.

Yeh and colleagues [2000] reported a case in which they successfully treated a patient who had an isolated right ventricular thrombus using recombinant tissue plasminogen activator. In this case, thrombus was treated without causing any embolic complications. There are no literature findings about surgical removal of right ventricular thrombi in the absence of pulmonary embolism. Surgery was recommended for most cases that were complicated with massive pulmonary embolism that resulted in hemodynamic impairment or in which thrombolysis was contraindicated or impossible to perform [Chartier 1999].

Less radical treatment options, such as heparin or oral anticoagulants, and close monitoring may be more convenient initially for patients with isolated right ventricular thrombus. If there is not any response to this form of treatment, the complexity of the thrombus should be considered and thrombolysis or surgery should be attempted. Once again, the dimensions and mobility of the thrombi might influence the treatment choice. Since large and freely moving thrombi are more prone to complications, thrombolysis or surgery is appropriate in these cases.

There is no information in the literature about heparin treatment in right ventricular thrombi if a pulmonary embolism is not present. However, heparin administration at the same dose that is administered in patients with pulmonary embolism may be convenient [Task Force on Pulmonary Embolism 2000]. We used this dose level in our case. Secondary prevention with oral anticoagulants should be assessed

on an individual basis, and the level of INR should be maintained between 2 and 3. There is no information on the duration of anticoagulant therapy that will be administered after curing patients with right ventricular thrombus. The decision should depend on individual characteristics such as clinical presentation, recurrence probability, concurrent medical conditions, and possible risks of a new thrombus formation.

In conclusion, patients with right ventricular thrombi that are not complicated with pulmonary embolism may benefit from initial treatment with heparin and oral anticoagulants, especially when thrombolysis or surgery is risky or inconvenient. In this case report, only 1 patient is presented. We do not suggest heparin and sodium warfarin treatment as the first choice of treatment of right ventricular thrombi in all cases. It should not be forgotten that an embolization may threaten the life of the patient during medical treatment. Different types of treatment for right ventricular thrombi might be needed according to the situation of the patient and the thrombi.

REFERENCES

- Baykan M, Celik S, Erdol C, et al. 2001. Behcet's disease with a large intracardiac thrombus: a case report. *Heart* 85:e7.
- Calvo JR, Duran RM, Vazquez de Prada JA. 1990. Resolution of relapsing thrombus by heparin therapy in right ventricular dysplasia. *Int J Cardiol* 26: 238-9.
- Chartier L, Bera J, Delomez M, et al. 1999. Free-floating thrombi in the right heart: diagnosis, management, and prognostic indexes in 38 consecutive patients. *Circulation* 99:2779-83.
- Doireau V, Daoud P, Pasche J, Le Bidois J. 1993. Right intraventricular thrombus. Rare complication of caval catheterization. *Arch Fr Pediatr* 50:887-9.
- Schneider C, Bahlmann E, Heuser C, et al. 2003. Images in cardiovascular medicine. Unusual biventricular thrombus formation in acute myeloid leukemia and factor V leiden mutation. *Circulation* 107:e114-6.
- Task Force on Pulmonary Embolism, European Society of Cardiology. 2000. Guidelines on diagnosis and management of acute pulmonary embolism. *Eur Heart J* 21:1301-36.
- Torbicki A, Galie N, Covezzoli A, Rossi E, Rosa MD, Goldhaber SZ. 2003. Right heart thrombi in pulmonary embolism—results from the International Cooperative Pulmonary Embolism Registry. *J Am Coll Cardiol* 41:2245-51.
- Yeh KH, Hung KC, Lin FC, Yeh SJ, Wu D. 2000. Successful lysis of right and left heart thrombus by tissue plasminogen activator. *Catheter Cardiovasc Interv* 49:91-6.