

# Surgical Treatment of Coronary Pseudoaneurysm: A Case Report and Literature Review

Haiyan Xiang, Rifeng Gao, Juesheng Yan, Juxiang Li, Jin Li, Fei Lu, Yanhua Tang

Department of Cardiovascular Surgery, The Second Affiliated Hospital of Nanchang University, Nanchang University, Nanchang, Jiangxi Province, China

## ABSTRACT

A coronary pseudoaneurysm is a rare complication of chest trauma. In this report, we describe the case of a 65-year-old man with a mediastinal lesion. On admission, he complained of chest tightness and dry cough, and a pseudoaneurysm was confirmed in the left anterior descending branch of the coronary artery on chest computerized tomography, angiography, and coronary angiography. The patient had experienced chest trauma 5 years previously. With the help of extracorporeal bypass surgery, the pseudoaneurysm was resected under direct observation. The patient recovered well after surgery. Traumatic coronary artery pseudoaneurysms usually are asymptomatic and often misdiagnosed. Preoperative coronary angiography is a crucial diagnostic used for deciding appropriate surgical management.

## INTRODUCTION

Giant coronary artery pseudoaneurysm is a rare condition generally caused by infection, inflammation, and connective tissue disorders [Yoshioka 2011]. The next most common etiological factor is a complication from newly-developed interventions, such as catheter-based techniques, that can lead to coronary artery rupture and perforation. However, this illness rarely is reported secondary to chest trauma and rib fracture [Sasaguri 2011]. Additionally, it can lead to myocardial ischemia or acute pericardial tamponade in cases of rupture and hemorrhage [Iemura 1996], and timely resection is an effective preventive strategy. In this study, we report on a patient with a left coronary artery pseudoaneurysm after a rib fracture resulting from chest trauma that mainly manifested as delayed chest tightness.

## CASE REPORT

A 65-year-old male patient was admitted with a 4-day history of bilateral lower-limb pain, difficulties with movement,

*Received July 3, 2019; received in revised form November 11, 2019; accepted December 4, 2019.*

*Correspondence: Yanhua Tang, Department of Cardiovascular Surgery, The Second Affiliated Hospital of Nanchang University, Jiangxi Province, China (e-mail: tyb6565@163.com).*

a dry cough, and throat pain persisting for half a day. Four days previously, he felt pain and had difficulty with movement in both lower extremities, especially in the joints, without an obvious cause. This was accompanied by chest tightness, chest pain, dry cough, and fever ( $<38.0^{\circ}\text{C}$ ) but without any morning stiffness, blepharoptosis, or limb weakness. He had a history of closed chest trauma 5 years previously. Chest computerized tomography (CT) displayed segmental consolidation in the lower lobes of both lungs, bilateral pleural effusion, fractures of the right fourth and fifth anterior ribs, and an occupying lesion in the anterior mediastinum. Chest enhancement CT also displayed an occupying lesion in the anterior mediastinum (Figure 1). This lesion was thought to be either a pseudoaneurysm complicated by a thrombus or a dermoid cyst. CT three-dimensional (3D) imaging revealed a  $6.6 \times 8.1$  cm dermoid cyst between the aorta and pulmonary artery. Coronary angiography confirmed the lesion was within the anterior mediastinum, (Figure 2) and suggested a high probability of a malformation in the cone of the left anterior descending branch of the coronary artery. Coronary angiography also showed that the lump in the upper mediastinum was accompanied by an abnormal distribution of the diagonal branch of the left descending branch of the coronary artery.

A median incision was made in the sternum. After the chest was opened, a  $7.0 \times 8.5$  cm parenchymal lump with no fluctuation was seen positioned between the outflow tract

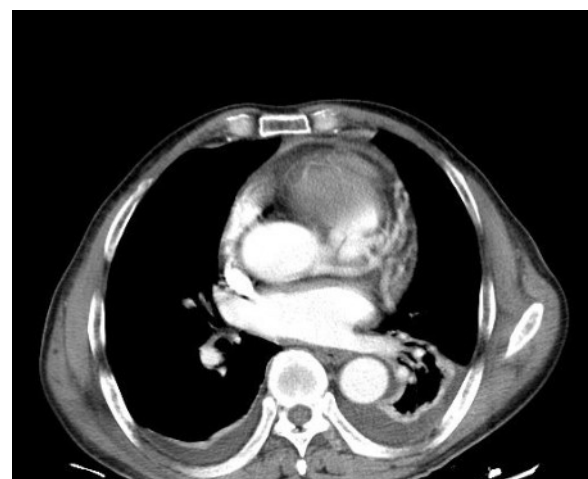

Figure 1. Chest enhancement CT also displayed an occupying lesion in the anterior mediastinum.

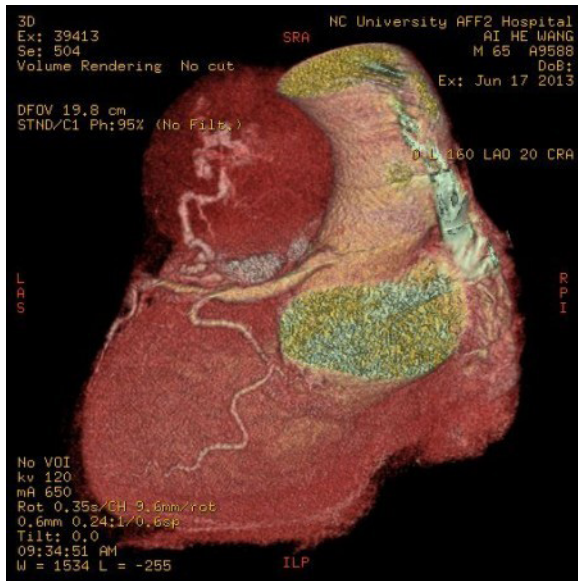


Figure 2. Coronary angiography confirmed that the occupying lesion was within the anterior mediastinum.

of the right ventricle and the main pulmonary artery, which was causing substantial compression. When the envelope was separated, active bleeding occurred. Therefore, the lump was suspected to be a coronary artery pseudoaneurysm with an arterial blood supply. During extracorporeal bypass, the lump was cut open and considerable organizing tissues (consisting of an old blood clot) were exposed. (Figure 3) After these tissues were removed, a blood vessel branching from the left coronary artery cone was observed in the outer membrane of the lump. The lump was excised, and bleeding was stopped (Figure 4).

After surgery, cefotaxime was prophylactically administered to prevent infection and proton pump inhibitors were given to inhibit gastric acid and protect the gastric mucosa. Water and electrolytes also were adjusted accordingly.

## RESULTS

Post-surgery, the patient was sent to the cardiac intensive care unit. Four hours later, the tracheal cannula was removed, and one day after that, the patient was transferred to the general ward. The incision healed well. On the postoperative eighth day, the sutures were removed, and the patient was discharged.

Pathological examination of the diseased tissues obtained during surgery showed the lump consisted of fibrofatty tissues with some hyaline cartilage degeneration, several proliferating vessels, dilation, congestion, and blood, scattered acute and chronic inflammatory cell infiltration, and an arterial thrombus with some organization. No elastic tissues or smooth muscle cells were seen in the endomembrane (Figures 5-7). These pathological manifestations occurred as a result of the pseudoaneurysm.

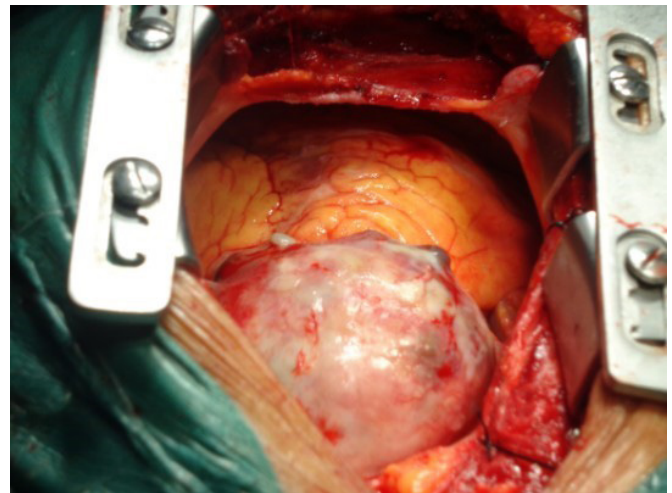


Figure 3. 7.0 × 8.5 cm parenchymal lump with no fluctuation was seen that was positioned between the outflow tract of the right ventricle and the main pulmonary artery and created substantial compression.

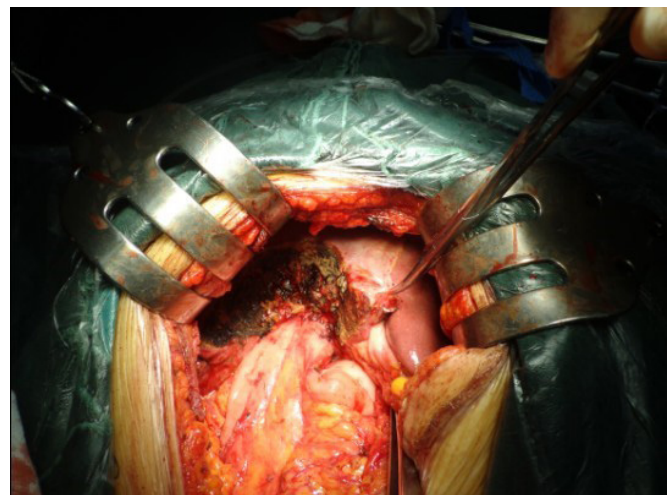


Figure 4. These tissues were removed and a blood vessel branching from the left coronary artery cone was observed in the outer membrane of the lump. Finally, the lump was excised, and bleeding was stopped.

## DISCUSSION

Coronary artery pseudoaneurysms are rather uncommon and generally occur secondary to atherosclerosis, Kawasaki disease, Marfan syndrome, and infection; only 4-5% of cases result from traumatic coronary artery rupture and perforation [Iga 1996]. The disease course varies depending on the location of the pseudoaneurysm [Rao 2008]. Trunk pseudoaneurysms can cause typical myocardial ischemia and, in the case of rupture and bleeding, an acute massive hemorrhage and even pericardial tamponade. However, in small branch lesions of the coronary artery, symptoms are late and atypical; as it enlarges, the peripheral organs become compressed. Therefore, this condition should be identified as early as possible.

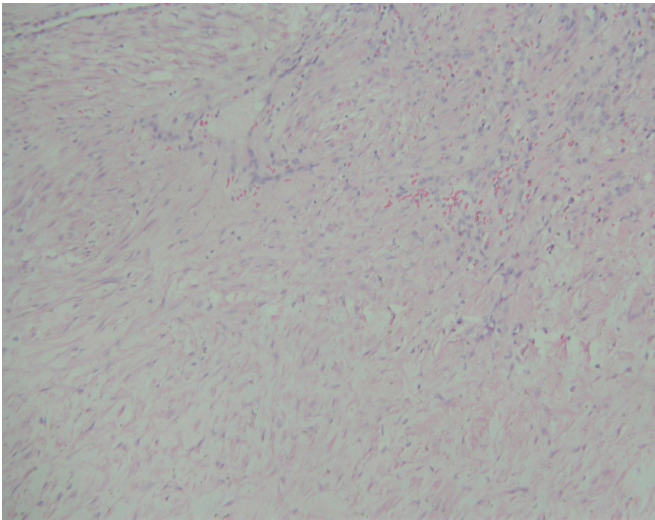


Figure 5. Hyaline degeneration or edema accompanied by mucinous degeneration in partial vessel and break of the vessel wall.

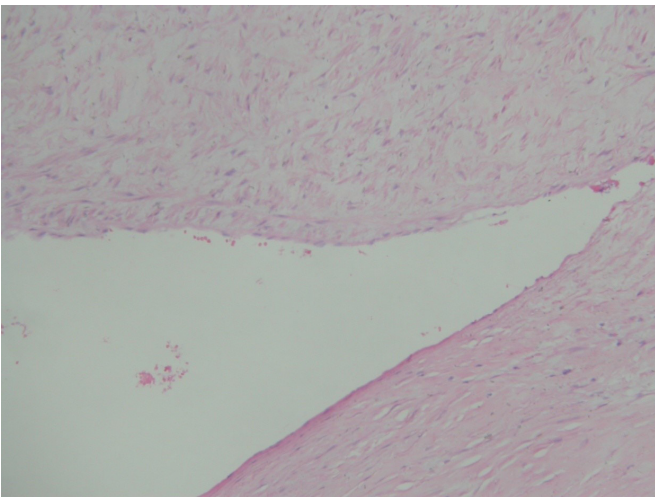


Figure 6. Lymphocyte infiltration in portions of the vessels.

The symptoms of pseudoaneurysm should be recognized. Coronary artery pseudoaneurysm should be highly suspected if a patient complains of myocardial ischemia or acute pericardial tamponade-related symptoms, such as chest tightness and pain, cardiopalmus, hypotension, and fever. However, symptoms are different depending on the cause and course of the disease. Some patients may have no symptoms. The patient in our study presented with atypical fever, chest tightness, pain, and a dry cough, resulting from compression of the peripheral tissues by the enlarging pseudoaneurysm. A patient's medical history also is crucial. Most patients who develop a traumatic coronary artery pseudoaneurysm have a history of trauma or interventional operations. Fukutomi has described the case of a woman who developed a 1-cm pseudoaneurysm 2 weeks after the discovery of a 1.5-mm saccular dilatation of the severely stenosed (99%) left anterior descending coronary

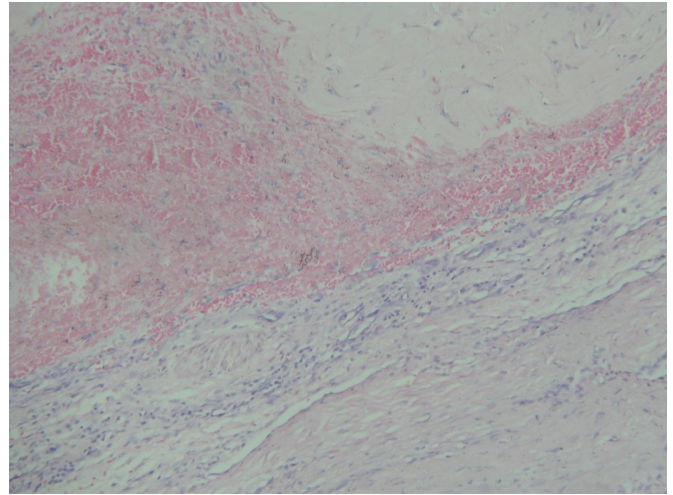


Figure 7. Hyaline degeneration of tissues near the outer membrane of the blood vessels as well as lymphocyte infiltration and hemorrhage of the outer membrane.

artery [Sasaguri 2011]. Therefore, the interventional history in the coronary arteries should not be ignored. Both penetrating and nonpenetrating chest traumas can induce a coronary artery pseudoaneurysm [RuDusky 2007; Hobelmann 2006]. The pseudoaneurysm in our case patient could have resulted from a heart contusion and lacerations from a rib fracture.

In addition to the disease history and clinical manifestations, auxiliary examinations such as chest CT, CT coronary angiography, intravascular ultrasound, and coronary angiography also aid in the diagnosis. Daisuke reported the case of a patient who underwent a scheduled surgery for a chest fracture caused by a fall [Hobelmann 2006]. The patient never complained of any discomfort. One year later, however, a giant lump was found on the surface of the right side of the heart by chest radiography that was identified on chest CT as a 7-cm right coronary artery pseudoaneurysm. In subsequent follow up, the chest CT did not show that it had enlarged, whereas the enhancement CT did. Thus, both chest CT and enhancement CT can provide strong evidence of coronary artery pseudoaneurysm, but neither can reconstruct or visualize the flow of the coronary artery.

Coronary angiography can identify not only the location and size, but also the blood supply of the coronary artery and stenosis of the distal portion of the artery involved. For the present study, coronary angiography showed that the proximal right coronary artery completely was occluded, the lateral branches communicated with the pseudoaneurysm, and the distal portion was supplied by the lateral branches of the left coronary artery. Chest CT and chest CT angiography were used to visualize the mediastinal lesion but failed to identify its origin or nature. Coronary angiography showed that its blood-supplying vessels were derived from the diagonal branch of the anterior descending branch of the left coronary artery and showed no stenosis in the trunk of the coronary artery. Therefore, the use of coronary angiography is recommended as soon as a coronary artery

pseudoaneurysm is suspected, according to the disease history and examination results.

Coronary artery pseudoaneurysms are uncommon in clinical practice and treatment modalities vary. Bare metal stents mainly target mild pseudoaneurysms that develop due to a small crack in the coronary artery [Copeland 2012; Shimony 2011; Lansky 2006]. Kawazoe has reported the case of an old woman who had received a coronary atherectomy for acute angina [Ly 2005]. At 3 months postoperation, chest pain reappeared and both coronary angiography and intravascular ultrasound displayed coronary artery pseudoaneurysms. To prevent further pseudoaneurysm enlargement and rupture, a bare metal stent was implanted, after which the chest pain disappeared. However, covered stents are only slightly effective for this type of pseudoaneurysm [Romaguera 2011; Kawazoe 2013; Alston 2013]. Surgery is necessary for injuries in the trunk of the coronary artery and in cases of induced myocardial ischemia or symptoms of compression.

Sasaguri has reported a case of a pseudoaneurysm in the distal descending branch of the left coronary artery 2 weeks after a percutaneous transluminal coronary intervention [Sasaguri 2011]. In those 2 weeks, it had enlarged to 1 cm. A left internal mammary artery bypass was conducted without extracorporeal circulation. After the surgery, the patient returned to a normal physical working capacity.

Hagau has described the case of a patient with a paclitaxel-eluting stent used to treat coronary disease in the left main trunk [Hagau 2013]. Six months later, a large coronary pseudoaneurysm appeared and then broke into the pulmonary artery. Thoracic left coronary artery trunk bypass was performed, and the pulmonary artery fistula was sutured. If the pseudoaneurysm had been small and had not induced a myocardial blood supply disorder or symptoms of local compression, nonsurgical treatment could have been considered [Hagau 2013].

Miwa reported the case of a patient who suffered fractures of the third to fifth left anterior ribs in a car accident [Miwa 2012]. The patient's vital signs remained stable and no heart dysfunction or arrhythmia was found. One month later, left ventricular catheterization displayed a pseudoaneurysm of the left anterior descending artery and intravascular ultrasound showed that the pseudoaneurysm significantly had shrunk. One year later, coronary angiography revealed that the pseudoaneurysm had disappeared.

In the present case, the patient had a long history of chest injury. At the time of diagnosis, the pseudoaneurysm had enlarged and induced significant symptoms of compression and therefore was removed. On exploratory thoracotomy, a 7.0 × 8.5 cm parenchymal lump with no fluctuations was seen that covered and compressed the outflow tract of the right ventricle and the main pulmonary artery. When the envelope was separated, active bleeding occurred. Therefore, the lump was suspected to be a coronary artery pseudoaneurysm with arterial blood supply. Accordingly, the lump was resected, and supplying blood vessels were closed under extracorporeal circulation. This type of surgery can be used to remove a pseudoaneurysm, resolve compression symptoms, and reconstruct myocardial blood supply and is believed to be the

most effective modality for the treatment of coronary artery pseudoaneurysm.

In the event of early diagnosis and treatment, coronary artery pseudoaneurysm is associated with a favorable prognosis. Yoshioka et al reported the case of a patient who, one year after a fall to the chest, was found to have a 7-cm right coronary artery pseudoaneurysm on chest CT [Yoshioka 2011]. On coronary angiography, the right coronary artery completely was occluded, and small branches of the right coronary artery were communicating with the pseudoaneurysm. Cardiac color ultrasound revealed inferior myocardial hypokinesis, for which a right coronary artery bypass and pseudoaneurysm removal were conducted. Post-surgical coronary angiography showed significantly increased movement of the inferior myocardium. The patient in the current study had no fever and his compression symptoms disappeared after surgery. Repeated chest enhancement CT showed no significant abnormalities in the superior mediastinum and electrocardiography showed no signs of myocardial ischemia. The mid-term outcome was satisfactory, and the long-term outcome is undetermined.

The mechanism of traumatic coronary artery pseudoaneurysm remains unclear. In the present case, closed chest trauma caused contusion and laceration of the coronary artery, resulting in chronic bleeding and exudation of the injured blood vessels. Thereafter, a pseudoaneurysm gradually formed. Such cases generally have a long disease history and atypical clinical symptoms. Timely diagnosis and proper treatment can prevent severe complications. The present report suggests that surgery is an effective modality for coronary artery pseudoaneurysms.

## ACKNOWLEDGEMENT

This research was funded by the Jiangxi Provincial Natural Science Foundation Project (20171BBG70067, 20181074, 2016YNQN12036). This work was supported by National Natural Science Foundation of China (#81160019 #81360031). The authors declare that there is no conflict of interest.

## REFERENCES

- Alston EA, Brott BC, Misra VK, Athanasuleas CL, Anderson PG, Litovsky SH. 2013. Histologic analysis of a covered stent implanted for pseudoaneurysm in a coronary artery. *Cardiovasc Pathol* 22(3):e19-21.
- Aqel RA, Zoghbi GJ, Iskandrian A. 2004. Spontaneous coronary artery dissection, aneurysms, and pseudoaneurysms: a review. *Echocardiography* 2:75-82.
- Copeland K, Hopkins J, Weintraub W, Rahman W. 2012. Long-term follow-up of polytetrafluoroethylene-covered stents implanted during percutaneous coronary intervention for management of acute coronary perforation. *Catheter Cardiovasc Interv* 80:53-7.
- Hagau AM, Dudea SM, Hagau R, Hagau N. 2013. Large coronary pseudoaneurysm with pulmonary artery fistula, six months after left main trunk stenting with paclitaxel-eluting stent. *Med Ultrason* 15(1):59-62.

- Hobelmann A, Pham JC, Hsu EB. 2006. Case of the month: right coronary artery dissection following sports related blunt trauma. *Emerg Med J* 23:580-1.
- Iemura J, Oku H, Shirotani H. 1996. Right coronary artery pseudoaneurysm after blunt injury to the chest. *Heart* 76-86.
- Iga K, Fuikawa T, Ueda Y, et al. 1996. Massive hemopericardium as a first manifestation of coronary aneurysm: successful surgical management. *Am Heart J* 131:618-620
- Kawazoe H, Ikeda S, Uga S, Yamane KI, Ohshima K, Hamada M. 2013. Spontaneous disappearance of coronary pseudoaneurysm due to coronary artery perforation following percutaneous coronary intervention. *Cardiovasc Interv Ther* 28(4):408-414.
- Lansky AJ, Yang Y, Khan Y, et al. 2006. Treatment of coronary artery perforations complicating percutaneous coronary intervention with a polytetrafluoroethylene covered stent graft. *Am J Cardiol* 98:370-374.
- Ly H, Awaida J-P, Lesperance J, Bilodeau L. 2005. Angiographic and clinical outcomes of polytetrafluoroethylene-covered stent use in significant coronary perforations. *Am J Cardiol* 95:244-6.
- Miwa K, Matsubara T, Yasuda T, et al. 2012. Spontaneous healing of posttraumatic focal coronary aneurysm: a case report. *Heart Lung* 41(6):613-6.
- Rao RK, Yadav SR, Roy VN. 2008. Coronary pseudoaneurysm: an uncommon cause of P.U.O. after a common procedure: an interesting case report. *Int J Cardiol* 127(1): e18-21.
- Romaguera R, Waksman R. 2011. Covered stents for coronary perforations: is there enough evidence? *Catheter Cardiovasc Interv* 78:246-253.
- RuDusky BM. 2007. Classification of myocardial contusion and blunt cardiac trauma. *Angiology* 58:610-613.
- Sasaguri S, Nishimori H, Wariishi, S. 2011. A surgical case report of off-pump onlay patch grafting for pseudoaneurysm with diffusely calcified coronary artery. *Ann Thorac Cardiovasc Surg* 17:94-96.
- Shimony A, Joseph L, Mottillo S, Eisenberg MJ. 2011. Coronary artery perforation during percutaneous coronary intervention: a systematic review and meta-analysis. *Can J Cardiol* 27:843-50.
- Yoshioka D, Izutani H, Ryugo M, Kawachi K, Sawa Y. 2011. Asymptomatic giant traumatic right coronary artery pseudoaneurysm caused by sternal fracture. *Ann Thorac Surg* 92:33-35.