

Xiphoid Lower-Sternotomy Approach for Multivessel Revascularization of the Left Internal Mammary Artery to the Left Anterior Descending Artery and Right Internal Mammary Artery Inflow to the Other Vessels

Federico Benetti,¹ Sotirios Prapas,² Ernesto Angeletti,¹ Jose Luis Ameriso,¹ Eduardo Cicalle,¹ Tomislav Klokocovnik,³ Ivan Knezevic,³ Borut Gersak³

¹Benetti Foundation, Rosario, Argentina; ²Henry Dunant Hospital, Athens, Greece; ³Department of Cardiovascular Surgery, University Medical Center Ljubljana, Ljubljana, Slovenia

ABSTRACT

Background: We describe the technical details and the preliminary results of a new surgical approach for multivessel disease that involves using a lower T sternotomy, grafting of the left internal mammary artery (LIMA) to the left anterior descending coronary artery (LAD) and use of the right internal mammary artery (RIMA) as inflow to the other vessels.

Operative Technique: The sternotomy was made from the xiphoid up to the fourth intercostal space and then was continued transversally (T incision). The LIMA was harvested for a length of approximately 8 cm, with preservation of the distal part. The vein was simultaneously taken from the leg. The RIMA was dissected for a length of approximately 5 cm, and the distal part was occluded. Then, 3 mg/kg heparin was given. The anastomosis between the vein and the RIMA was performed. The distal venous anastomoses were done either singly or sequentially. The anterior or posterior route was chosen according to the patient's anatomy. The LIMA was then anastomosed to the LAD. One drain was placed. The sternum was closed with 4 wires, 2 for the T incision and 2 for the sternum.

Results: Between September and December 2008, 9 patients underwent their operations with this technique. The mean age was 60 years (range, 55-68 years). The mean number of grafts was 2.8. The mean hospital stay was 5.2 days. Operative mortality was 0%. All patients were reevaluated with 16-slice multislice computed tomography, and all grafts were patent. At the 3-month follow-up, all patients were alive and free of symptoms.

Conclusion: This minimally invasive technique is a useful alternative for complete revascularization. The sternal mammary supply and the upper part of the sternum are preserved.

INTRODUCTION

Benetti [1985] and Buffolo et al [1985] repopularized beating-heart coronary revascularization (off-pump

coronary artery bypass [OPCAB]) by expanding the technique, addressing lesions of the circumflex system, and applying it to different clinical scenarios. Later on,

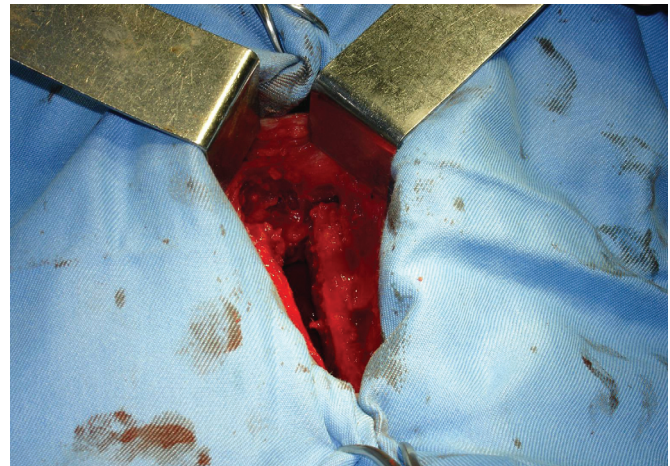


Figure 1. The sternotomy was made from the xiphoid up to the fourth intercostal space and was then continued transversally (T incision).

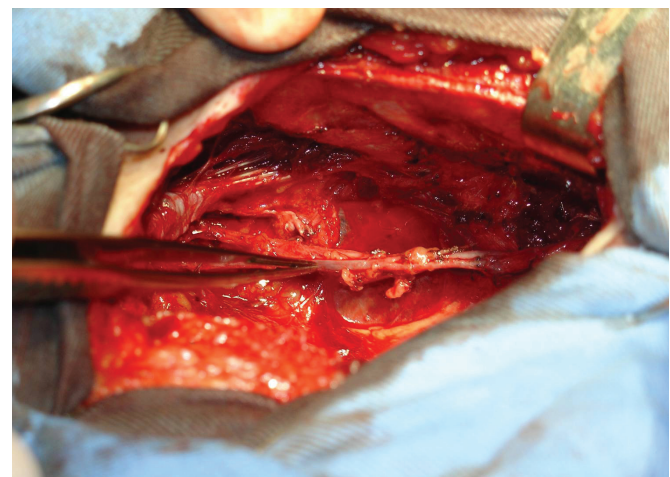


Figure 2. The left internal mammary artery was harvested for a length of approximately 8 cm, preserving the distal part.

Presented at the Postdoctoral Joint Symposium on Cardiovascular Diseases, Ljubljana, Slovenia, May 25, 2009.

Correspondence: Federico Benetti, Benetti Foundation, Alem 1846, Rosario, Argentina zip 2000; 011543414855827 (e-mail: federicobenetti@botmail.com).

Patient Bypass Procedures*

Patient No.	Age, y	Sex	Vessel Bypasses	Hospital Stay, d
1	60	F	LIMA to LAD – Vein from RIMA to RCA – Cx (posterior) ×3	6
2	55	M	LIMA to LAD – Vein from RIMA to RCA (posterior) D (anterior) ×3	4
3	66	M	LIMA to LAD – Vein from RIMA to Cx (posterior) ×2	5
4	60	M	LIMA to LAD – Vein from RIMA to Cx ×2, –D (posterior) (anterior) ×4	8
5	61	M	LIMA to LAD – Vein from RIMA to RCA-Cx (posterior) ×3	5
6	56	M	LIMA to LAD – Vein from RIMA to RCA (posterior) ×2	2
7	68	M	LIMA to LAD – Vein from RIMA to RCA ×2 (posterior) ×3	7
8	56	M	LIMA to LAD – Vein from RIMA to RCA (posterior) × 2	4
9	62	M	LIMA to LAD – Vein from RIMA to RCA-Cx (posterior) ×3	6

*LIMA indicates left internal mammary artery; LAD, left anterior descending coronary artery; RIMA, right internal mammary artery; RCA, right coronary artery; Cx, circumflex artery; posterior, posterior surface of the heart; anterior, anterior surface of the heart; D, diagonal artery.

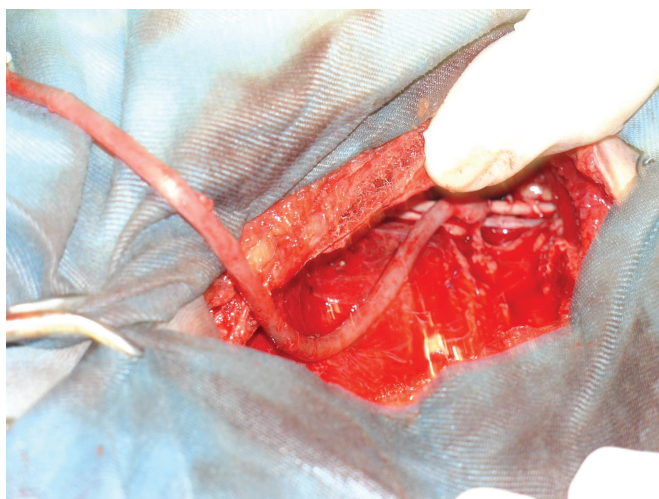


Figure 3. The anastomosis between the vein and the right internal mammary artery was performed.

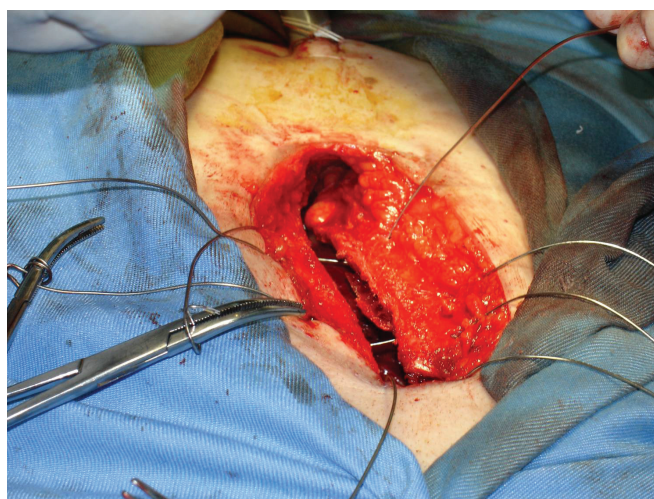


Figure 4. The sternum was closed with 4 wires: 2 for the T and 2 for the sternum.

several surgical-access approaches other than full sternotomy were used, including left anterolateral, posterolateral, and anterolateral thoracotomies, and partial sternotomy. Thoracoscopy was used for the first time to dissect the left internal mammary artery (LIMA) without opening the pleural cavity. In 1994, the LIMA was anastomosed to the left anterior descending coronary artery (LAD) through a small left anterior thoracotomy [Benetti 1994; Benetti 1995], marking the beginning of the era of minimal-access cardiac surgery, and the acronym MIDCAB (for minimally invasive direct coronary artery bypass) was coined.

A prospective multicenter study evaluating MIDCAB versus conventional bypass grafting [Mehran 2000] demonstrated equivalent LIMA-to-LAD patency rates for the 2 approaches. Today, surgery on the beating heart as OPCAB or MIDCAB is routine in many hospitals around the world, confirming the benefits of these techniques [Subramanian

1995; Jansen 1998; Trehan 2001; Angelini 2002; Magee 2002; Al-Ruzzeh 2003; Puskas 2003; Puskas 2004; Parolari 2005; Sharoni 2006; Lattouf 2007; Puskas 2007; STS 2007].

In 1997, we performed the first ambulatory coronary surgery. The approach was based on access via the xiphoid or lower sternotomy. Use of 3-dimensional visualization facilitated harvesting of the LIMA and its anastomosis to the LAD [Benetti 1999]. The main advantages of this approach include reduced postoperative pain and preservation of intact pleural cavities, thus increasing the possibility of early discharge [Benetti 1999] with good long-term results [Benetti 2008].

The aim of this report is to describe the technical details and the preliminary results of this operation in complete multivessel revascularization by using the LIMA to revascularize the LAD and using the right internal mammary artery (RIMA) as inflow to other vessels.

MATERIALS AND METHODS

Operative Technique

The sternotomy was made from the xiphoid up to the fourth intercostal space and was then continued transversally (T incision) (Figure 1). The LIMA was harvested for a length of approximately 8 cm with preservation of the distal part (Figure 2). The vein was simultaneously taken from the leg. The RIMA was dissected for a length of approximately 5 cm, and the distal part was occluded. Then, 3 mg/kg heparin was given. The anastomosis between the vein and the RIMA was performed (Figure 3). The distal venous anastomoses were done either singly or sequentially. The anterior or posterior route was chosen according to the patient's anatomy. The LIMA was then anastomosed to the LAD.

One drain was placed. The sternum was closed with 4 wires: 2 for the T incision and 2 for the sternum (Figure 4).

RESULTS

Between September 2008 and December 2008, 9 patients underwent their operations with this technique. The mean age was 60 years (range, 55-68 years). The mean number of grafts was 2.8. The mean hospital stay was 5.2 days. Operative mortality was 0% (Table). All patients were evaluated with 16-slice computed tomography scanning, and all grafts were patent. After 3 months of follow-up, all patients are alive and free of symptoms.

DISCUSSION

Coronary surgery without cardiopulmonary bypass has been performed via different approaches [Benetti 1985, 1994, 1995; Magee 2002; STS 2007]. However, the MIDCAB approach created 2 obstacles to early discharge: significant postoperative pain and opening of the left pleura. The MIDCAB approach often mandates the use of intravenous narcotics and often requires chest tube placement, serial radiographs, and removal of the chest tube with concerns about pneumothorax and pleural effusion. Having these drawbacks in mind, we refocused our approach to the xiphoid lower sternotomy. This strategy avoids pleural entry and is associated with much less and more treatable postoperative pain. These characteristics allow coronary bypass grafting to be performed with a very early discharge and excellent long-term results [Benetti 2008]. On the basis of these experiences, we designed a new technique that uses the RIMA as the inflow for complete revascularization.

The limitations of this technique with the current instrumentation and devices involve patients with a large thorax and a very horizontal heart. On the other hand, this technique is a useful alternative to conventional coronary surgery for a large number of patients. The advantages are easy to reproduce with the actual instrumentation in most cases: The sternal mammary supply is preserved, and the upper part of the sternum is preserved for possible future reentry.

Our preliminary experience yielded satisfactory results and quick recoveries. A larger number of patients and

dedicated instruments are needed to make this technique easy and reproducible.

REFERENCES

- Al-Ruzzeh S, Nakamura K, Athanasiou T, et al. 2003. Does off-pump coronary artery bypass (OPCAB) surgery improve the outcome in high-risk patients? A comparative study of 1398 high-risk patients. *Eur J Cardiothorac Surg* 23:50-5.
- Angelini CD, Taylor FC, Reeves BC, Ascione R. 2002. Early and mid-term outcome after off-pump and on-pump surgery in Beating Heart Against Cardioplegic Arrest Studies (BHACAS 1 and 2): a pooled analysis of two randomised trials. *Lancet* 359:1194-2000.
- Benetti FJ. 1985. Direct coronary surgery with saphenous vein bypass without either cardiopulmonary bypass or cardiac arrest. *J Cardiovasc Surg* 26:217-22.
- Benetti FJ. 1999. Minimally invasive coronary surgery (the xiphoid approach). *Eur J Cardiothorac Surg* 16(suppl 2):S10-1.
- Benetti FJ, Ballester C. 1995. Use of thoracoscopy and minimally thoracotomy, in mammary-coronary bypass to left anterior descending artery, without extracorporeal circulation: experience in 2 cases. *J Cardiovasc Surg (Torino)* 36:159-61.
- Benetti FJ, Ballester C, Barnia A. 1994. Uso de la toroscopia en cirugía coronaria para disección de la arteria mamaria interna. *Prensa Med Argent* 81:877-9.
- Benetti FJ, Rizzardi JL, Concetti C, et al. 2008. Xiphoid approach long term results [abstract]. Paper presented at: 18th World Congress – World Society of Cardio-Thoracic Surgeons; April 30 to May 3, 2008; Kos Island, Greece. *Heart Surg Forum* 11(suppl 1):175. Abstract OP-821.
- Buffolo E, Andrade JC, Succi J, Leao LE, Gallucci C. 1985. Direct myocardial revascularization without cardiopulmonary bypass. *Thorac Cardiovasc Surg* 33:26-9.
- Jansen EW, Borst C, Lahpor JR, et al. 1998. Coronary artery bypass grafting without cardiopulmonary bypass using the Octopus method: results in the first one hundred patients. *J Thorac Cardiovasc Surg* 116:60-7.
- Lattouf OM, Puskas JD, Thourani VH, Noora J, Kilgo PD, Guyton RA. 2007. Does the number of grafts influence surgeon choice and patient benefit of off-pump over conventional on-pump coronary artery revascularization in multivessel coronary artery disease? *Ann Thorac Surg* 84:1485-95.
- Magee MJ, Jablonski KA, Stamou SC, et al. 2002. Elimination of cardiopulmonary bypass improves early survival for multivessel coronary artery bypass patients. *Ann Thorac Surg* 73:1196-203.
- Mehran R. Long-term patency of LIMA-LAD beating heart anastomosis (POEM) trial. 2000. Paper presented at: The 6th Annual Cardiothoracic Techniques & Technologies meeting 2000; January 27-29, 2000; Bal Harbour, Fla.
- Parolari A, Alamanni F, Polvani G, et al. 2005. Meta-analysis of randomized trials comparing off-pump with on-pump coronary artery bypass graft patency. *Ann Thorac Surg* 80:2121-5.
- Puskas JD, Edwards FH, Pappas PA, et al. 2007. Off-pump techniques benefit men and women and narrow the disparity in mortality after coronary bypass grafting. *Ann Thorac Surg* 84:1447-54.
- Puskas JD, Williams WH, Duke PG, et al. 2003. Off-pump coronary artery bypass grafting provides complete revascularization with reduced myocardial injury, transfusion requirements, and length of stay: a

prospective randomized comparison of two hundred unselected patients undergoing off-pump versus conventional coronary artery bypass grafting. *J Thorac Cardiovasc Surg* 125:797-808.

Puskas JD, Williams WH, Mahoney EM, et al. 2004. Off-pump vs conventional coronary artery bypass grafting: early and 1-year graft patency, cost, and quality-of-life outcomes: a randomized trial. *JAMA* 291:1841-9.

Sharoni E, Song HK, Peterson RJ, Guyton RA, Puskas JD. 2006. Off pump coronary artery bypass surgery for significant left ventricular dysfunction: safety, feasibility, and trends in methodology over time—an early experience. *Heart* 92:499-502.

[STS] Society of Thoracic Surgeons. 2007. Spring 2007 Report. Adult Cardiac Database Executive Summary. Available at: http://www.sts.org/documents/pdf/Report_Overview_-_General.pdf. Accessed October 14, 2009.

Subramanian VA, Benetti FJ, Calafiore AM. 1995. Minimally invasive bypass surgery: a multi-center report of preliminary clinical experience [abstract]. *Circulation* 92(suppl):645.

Trehan N, Mishra M, Sharma OP, Mishra A, Kasliwal RR. 2001. Further reduction in stroke after off-pump coronary artery bypass grafting: a 10-year experience. *Ann Thorac Surg* 72(suppl):S1026-32.