

Establishing the Case for Minimally Invasive, Robotic-Assisted CABG in the Treatment of Multivessel Coronary Artery Disease

Brandon Jones, Pranjali Desai, Robert Poston, MD

Division of Cardiac Surgery, Boston University School of Medicine, Boston, MA, USA

ABSTRACT

The purpose of this review is to outline the most common objections about robotic coronary artery bypass graft (CABG), often expressed by cardiac surgeons, cardiologists, and administrators who have little direct knowledge of the procedure. The summarized objections include the high intraoperative costs of robotic versus traditional CABG, a prolonged and difficult learning curve for members of the surgical team, and concerns about compromising graft patency with this technique. Arguments for continued procedure development in robotically assisted CABG are provided.

INTRODUCTION

To the uninitiated, the traditional method of performing coronary artery bypass grafting (CABG) can seem excessively traumatic and complicated. It involves a bone saw for a full median sternotomy, cardiopulmonary bypass to support the circulation, and the induction of cardiac arrest. Although cardiac surgeons have become comfortable with the established routines and excellent track record of this well-established procedure, patients universally have experienced fears about undergoing such a significant and traumatic operation. The availability of less invasive, percutaneous treatments for coronary artery disease has dramatically influenced patient referrals. Off-pump coronary artery bypass (OPCAB) techniques that circumvent the need for cardiopulmonary bypass were initially greeted with enthusiasm. Later, lackluster data on the results of OPCAB led to this procedure falling out of favor among most surgeons, for whom the improvements in results compared with those for on-pump CABG were judged to be insufficient to justify the added technical complexity of OPCAB. Recently, however, the Da Vinci robot has opened the door for a procedure that is both off-pump and sternal sparing. Robotic instruments provide thorascopic access to the mediastinum for bilateral internal mammary artery (BIMA) harvest, pericardiotomy, and identification of the coronary

targets, all without the usual risk of poor sternal healing associated with BIMA harvest following a sternotomy. The distal anastomoses are created via an incision limited to a small, intercostal thoracotomy performed using port-access stabilization or endoscopic instruments alone [Bonatti 2006; Poston 2008]. Finally, a surgical suite equipped with fluoroscopy facilitates intraoperative coronary angiography and stenting. The combination of IMA grafting with stenting provides for complete revascularization and the potential to reduce the risk of reintervention associated with stenting alone.

Although this approach has demonstrated great appeal to patients and their providers, minimally invasive CABG remains highly controversial among practicing cardiac surgeons. The purpose of this report is to discuss how our team responds to the most commonly stated objections to the robotic-assisted technique, and the potential that this technique has for changing the standard of care for CABG.

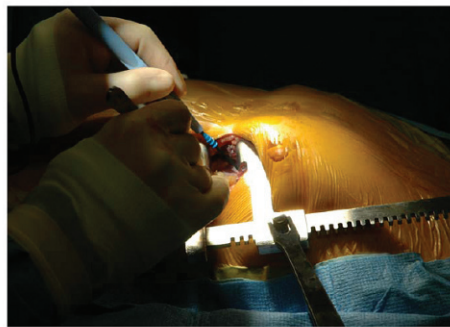THE IMPACT OF ROBOTIC CABG ON COSTS

The first and most obvious disadvantage of pursuing a robotic CABG program is the high cost of acquisition of the necessary technology and the high per procedure cost due to limited-use instruments. Additional concerns have persisted about increased operating-room times (and therefore costs), particularly during the long and somewhat difficult learning curve for not only surgeons but also anesthesiologists and nurses [Oehlinger 2007]. These increased costs can be especially challenging to justify in an era of declining reimbursements for CABG and may affect the level of support by the hospital administration.

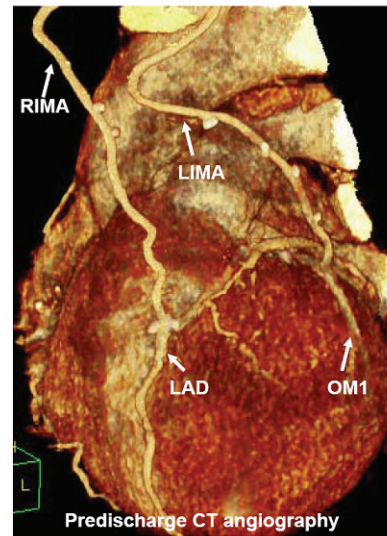
It has been established that minimizing the length of hospital stay or frequency of postoperative complications are among the highest-impact methods for reducing hospital costs [Brown 2008]. OPCAB has been shown to reduce costs relative to on-pump CABG, but the combined impact of minimally invasive and off-pump techniques on costs remains uncertain. To analyze the influence of the surgical approach on total hospital costs, we prospectively analyzed 2 cohorts undergoing off-pump coronary revascularization by use of either a minithoracotomy or sternotomy. All procedures were performed by the same surgeon, and the patient groups were matched for the number of coronary arteries revascularized and risk factors known to influence perioperative outcome [Poston 2008]. Patients in the minithoracotomy group had shorter intubation times (4.8 ± 6.4 versus 12.2 ± 6.2 hours,

Presented at the 4th Integrated Coronary Revascularization (ICR) Workshop for Interventional Cardiologists and Cardiac Surgeons, Innsbruck, Austria, December 4-6, 2008.

Correspondence: Robert Poston, MD, Boston University School of Medicine, 88 East Newton Street, Suite B-402, Boston, MA 02118; 1-617-638-7350; fax: 1-617-638-7228 (e-mail: Robert.Poston@bmc.org).



Distal anastomoses via small thoracotomy



PredischARGE CT angiography

After bilateral internal mammary artery conduits are harvested via the left sided ports, the camera port incision is extended into a 2-inch minithoracotomy to facilitate an off-pump coronary anastomoses performed using a standard hand-sewn technique (left). On postoperative day 3 (prior to discharge), patients who undergo minimally invasive coronary artery bypass grafting are routinely screened for graft patency using computed tomographic (CT) angiography (right). RIMA indicates right internal mammary artery, LIMA, left IMA; LAD, left anterior descending; OM, obtuse marginal.

$P < .001$), intensive-care unit stay (21.9 ± 9.3 versus 50.6 ± 27.3 hours, $P < .001$), total hospital stay (3.8 ± 1.5 versus 6.4 ± 2.2 days, $P < .001$), and lower blood transfusion requirements (0.2 ± 0.4 versus 1.4 ± 1.4 units, $P < .001$). Despite increased intraoperative costs for supplies, longer operating room times, and additional radiology services, the total hospital costs per patient were equivalent between groups. Of note, this analysis did not include the initial acquisition cost of the robot.

We found that the advantages of the robotic technology had the greatest impact on postoperative cost for patients with characteristics that placed them at high risk for long hospital stays (eg, elderly, ejection fraction 20%, poorly controlled diabetes, chronic obstructive pulmonary disease treated with home O_2). However, recruitment of lower-risk patients who are expected to have shorter stays reduces overall hospital costs. At Lennox Hill Hospital in Manhattan, patients undergoing robot-assisted multivessel revascularization have demonstrated an average length of stay of 20 hours [Subramanian 2005]. Although short lengths of stay are also possible in low-risk patients undergoing sternotomy, it is the reputation of Lennox Hill Hospital in minimally invasive CABG that has consistently attracted these types of low-risk patients. In our cohort, minimally invasive CABG was associated with a significantly shorter time to return to work versus sternotomy (44.2 ± 33.1 versus 93.0 ± 42.5 days; $P = .016$). These findings are particularly relevant to low-risk patients, a subgroup who are especially concerned with the adverse affects of a prolonged recovery on early quality of life.

Further cost advantages can be gained by reducing the incidence and types of common postoperative complications. Sternal infection/mediastinitis is a dreaded complication associated with additional hospital costs estimated to range from \$20K to \$50K per patient [Hollenbeak 2000]. Recent changes

in health care financing designate mediastinitis as a “never event” that is not reimbursable by Medicare [CMS 2008]. Without the sternotomy, an obvious benefit of minimally invasive CABG is that it eliminates sternal infection regardless of the preoperative risk profile. The robotic approach also has a potential impact on bleeding and reoperation for bleeding, a benefit that may gain importance as more potent antithrombotic therapies are adopted by our cardiology colleagues. All of these factors continue to be studied in efforts to fully understand the financial impact of minimally invasive surgery on providers, hospitals, and payers.

EFFECT OF MINIMALLY INVASIVE TECHNIQUES ON OUTCOME

The creation of a microvascular anastomosis on a beating heart via a small incision can be challenging to even the most skilled surgeon. The prolonged learning curve for most surgeons to attain the necessary skills remains a roadblock for the wider adoption of this procedure [Oehlinger 2007]. In addition to longer operating room times and more intraoperative costs, there is a risk that inadvertent errors in technique will adversely influence short- and/or long-term outcomes, particularly during the initiation phase of a robotic CABG program. We investigated the influence of this issue by comparing graft patency and early outcomes in patients undergoing robot-assisted versus traditional CABG who were matched by use of propensity scoring. In our analysis, the mini-CABG group showed 1 cardiac-related death, 1 stroke, 1 IMA graft stenosis, and 1 stent thrombosis during the first postoperative year, outcomes that are consistent with other groups [Subramanian 2005; Srivastava 2006]. In comparison, the OPCAB group showed 4 cardiac deaths and 2 strokes. Because more

saphenous vein grafts were used in the sternotomy group, there were 20 cases of early graft failure documented on follow-up computed-tomographic (CT) angiography during this first postoperative year. As a result, the incidence of major adverse cardiac and cerebrovascular events was 26% in the OPCAB group compared with 4% after mini-CABG (hazard ratio, 3.9; 95% confidence interval, 1.4-7.6; $P = .008$).

It is widely accepted that the choice of conduits plays a key role in long-term graft patency and patient survival after CABG. Although the use of both IMAs is the most effective approach, concerns about sternal dehiscence and infection have limited the use of this strategy to less than 5% of full-sternotomy CABG procedures performed in the United States. Instead, complete revascularization often depends heavily on the use of multiple saphenous vein segments. Unfortunately, procedures involving the use of this conduit are plagued by early thrombogenicity and a later tendency for development of accelerated atherosclerosis that limits the long-term success [Poston 2004; Poston 2006]. The robot provides a unique opportunity to harvest BIMAs without a sternotomy, thereby avoiding the risk of wound infection. Thus, more routine use of BIMA conduits with less dependence on saphenous vein grafts is an advantage that may improve the long-term results of patients treated with a robotic CABG strategy [Poston 2008].

Controversy remains surrounding the role of beating-heart techniques on the quality of graft anastomoses. However, the clinical importance of this issue is minimized by a variety of available methods that can be used to monitor for anastomotic defects intraoperatively, including transit time flow meters and on-table angiography. Postoperatively, graft patency can be verified using noninvasive CT angiography, which provides further feedback about the quality of the anastomoses (Figure). Ongoing analyses of graft patency using CT angiography will help address the question of the long-term quality of grafts performed using this technique.

THE FUTURE OF CORONARY REVASCLARIZATION

There is a growing mandate to organize cardiovascular care around the needs of patients, and to give patients choices about their own health care [STS 1998]. Robotic-assisted CABG, ultimately progressing toward a totally endoscopic procedure, is an innovative example of patient-centered care that helps to address patient concerns about early postoperative quality of life and length of recovery time following traditional CABG. Unlike percutaneous coronary intervention, a surgical intervention is still required. However, the additional up-front risks and morbidity of surgery versus percutaneous coronary intervention are balanced against the long-term benefits of single or dual IMA grafting over multiple coronary stents. A focus on less invasive revascularization makes robotic CABG complementary to percutaneous coronary intervention as a means of addressing a broader population of

patients with complex multivessel disease. Our own preliminary experience has demonstrated that a combined “hybrid” approach yields excellent perioperative outcomes, with patency of target vessels at 1 year follow-up that compares favorably with patients undergoing traditional CABG via a sternotomy [Kon 2008]. The hybrid procedure also illustrates the type of collaboration that patients, their providers, and payers have been searching for from the US healthcare system.

REFERENCES

- Bonatti J, Schachner T, Bonaros N, et al. 2008. How to improve performance of robotic totally endoscopic coronary artery bypass grafting. *Am J Surg* 195:711-6.
- Brown P, Kugelmass A, Cohen D, et al. 2008. The frequency and cost of complications associated with coronary artery bypass grafting surgery: results from the United States Medicare program. *Ann Thorac Surg* 85:1980-6.
- Centers for Medicare and Medicaid Services (CMS) [Internet]. 2008. CMS improves patient safety for Medicare and Medicaid by addressing never events. Available from: http://www.cms.hhs.gov/apps/media/fact_sheets.asp, follow “August 04, 2008” hyperlink.
- Hollenbeak CS, Murphy DM, Koenig S, et al. 2000. The clinical and economic impact of deep chest surgical site infections following coronary artery bypass graft surgery. *Chest* 118:397-402.
- Kon Z, Reicher B, Brown E, et al. 2008. Simultaneous hybrid coronary revascularization reduces postoperative morbidity compared to procedures utilizing only coronary artery bypass grafting. *J Thorac Cardiovasc Surg* 135:367-75.
- Oehlinger A, Bonaros N, Schachner T, et al. 2007. Robotic endoscopic left internal mammary artery harvesting: what have we learned after 100 cases? *Ann Thorac Surg* 83:1030-4.
- Poston RS, Prastein D, Gu J, et al. 2004. Virchow’s triad, but not use of an aortic connector device, predicts vein graft thrombosis after off-pump bypass. *Heart Surg Forum* 7:E428-33.
- Poston RS, White C, Gu J, et al. 2006. Endothelial injury and acquired aspirin resistance promote regional thrombin formation and early vein graft failure after coronary artery bypass. *J Thorac Cardiovasc Surg* 131:122-30.
- Poston RS, Tran R, Collins M, et al. 2008. Comparison of economic and patient outcomes with minimally invasive vs. traditional off-pump CABG techniques. *Ann Surg* 248:638-46.
- Subramanian VA, Patel NU, Patel NC. 2005. Robotic assisted multivessel minimally invasive direct coronary artery bypass with port-access stabilization and cardiac positioning: paving the way for outpatient coronary surgery? *Ann Thorac Surg* 79:1590-6.
- Srivastava S, Gadasalli S, Agusala M, et al. 2006. Use of bilateral internal thoracic arteries in CABG through lateral thoracotomy with robotic assistance in 150 patients. *Ann Thorac Surg* 81:800-6.
- Society of Thoracic Surgeons (STS) [Internet]. 1998. Accountable health care: letting patients lead the way: transforming Medicare for the 21st century. Available from: www.sts.org/doc/2809, Accessed March 21, 2009.