

## An Unusual Association: Right Atrial Myxoma and Severe Left Ventricular Dysfunction. Case Report and Review of the Literature

Lucian Florin Dorobantu, MD, PhD,<sup>1</sup> Ovidiu Chioncel, MD, PhD,<sup>2</sup> Alexandra Pasare, MD,<sup>1</sup>  
Dorin Lucian Usurelu, MD,<sup>1</sup> Ioan Serban Bubenek-Turconi, MD, PhD,<sup>3</sup> Vlad Anton Iliescu, MD, PhD<sup>1</sup>

Departments of <sup>1</sup>Cardiovascular Surgery, <sup>2</sup>Cardiology, and <sup>3</sup>Intensive Care Unit, "C.C. Iliescu" Emergency Institute for Cardiovascular Diseases, Bucharest, Romania

### ABSTRACT

Myxomas comprise 50% of all benign cardiac tumors in adults, with the right atrium as their second most frequent site of origin. Surgical resection is the only effective therapeutic option for patients with these tumors. The association between right atrial myxomas and severe left ventricular systolic dysfunction is extremely rare and makes treatment even more challenging. This was the case for our patient, a 47-year-old male with a right atrial mass and a severely impaired left ventricular function, with a 20% ejection fraction. Global enlargement of the heart was also noted, with moderate right ventricular dysfunction. The tumor was successfully excised using the on-pump beating heart technique, with an immediate postoperative improvement of the left ventricular ejection fraction to 35%. The technique proved useful, with no increased risk to the patient.

### CASE REPORT

A 47-year-old male, with a two-year history of progressive dyspnea was admitted to our clinic. At clinical examination the patient was febrile, and in obvious respiratory distress. Electrocardiography revealed sinus tachycardia, with a ventricular frequency of 106/min.

With transthoracic echocardiogram, Figure 1 a right atrial mass measuring 7.4/4 cm was identified, which prolapsed into the right ventricle and the inferior vena cava (IVC) during diastole. All heart chambers were enlarged, with mild mitral regurgitation, moderate tricuspid regurgitation, a left ventricular (LV) end-systolic diameter of 60 mm, and a 20% ejection fraction (EF). Given the circumstances, transesophageal echocardiogram was performed and revealed a large implantation base of the mass at the level of the inferior atrial septum, confirming at the same time the severe LV dysfunction, with regional wall motion abnormalities. Coronary angiography was normal.

On-pump beating heart surgery was performed through standard median sternotomy. To avoid mass fragmentation, the superior vena cava was first cannulated and snared,

the extracorporeal circulation started, and the right atrium opened. The tumor originated in the fossa ovalis, extended into the IVC, and visibly protruded through the coronary sinus ostium and through the tricuspid valve. After the portion of the mass extending into the IVC was resected, the IVC was cannulated and snared Figure 2. The rest of the tumor was then resected. The small remaining septal defect was repaired with two patch sutures, the right atrium closed, and the patient weaned from cardiopulmonary bypass (CPB). The histopathologic analysis confirmed the diagnosis. The patient's postoperative course was favorable. He was discharged seven days later, with an improved LV EF of 35%.

### DISCUSSION

With an estimated incidence between 8 and 150 cases per million, myxomas are the most common type of primary cardiac tumor [Patil 2011]. Although they can occur in nearly all age groups, myxomas tend to present between the third and sixth decade of life, commonly in women [Patil 2011; Lepillier 2010]. The symptoms confuse in late stages with those of heart failure [Irani 2008; Vizzardi 2010]. Syncope and sudden cardiac death are possible, making the diagnosis elusive [Romeo 2012].

Understandably, right heart failure is common in cases of right-sided tumors due to tricuspid obstruction, pulmonary embolism, or a combination of these two mechanisms

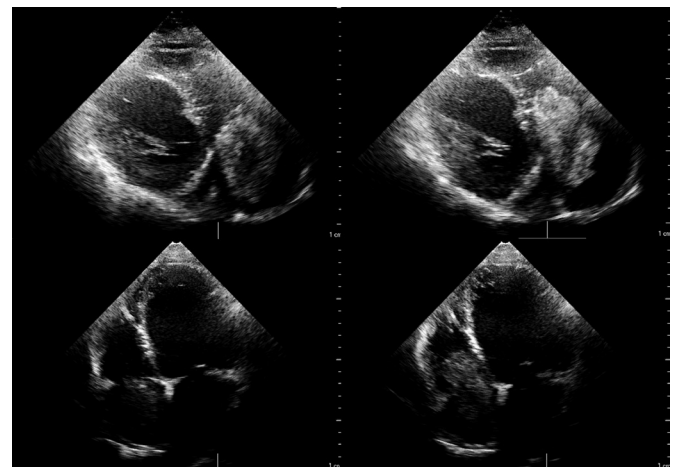


Figure 1. Transthoracic echocardiographic visualization of the tumor.

Received September 19, 2014; accepted November 16, 2014.

Correspondence: Lucian Florin Dorobantu, Department of Cardiovascular Surgery, "C.C. Iliescu" Emergency Institute for Cardiovascular Diseases, Sos. Fundeni 258, sect. 2, cod 022328, Bucharest, Romania; +04 0723302306; fax: +04 0213206573 (e-mail: [ludorobantu@gmail.com](mailto:ludorobantu@gmail.com)).

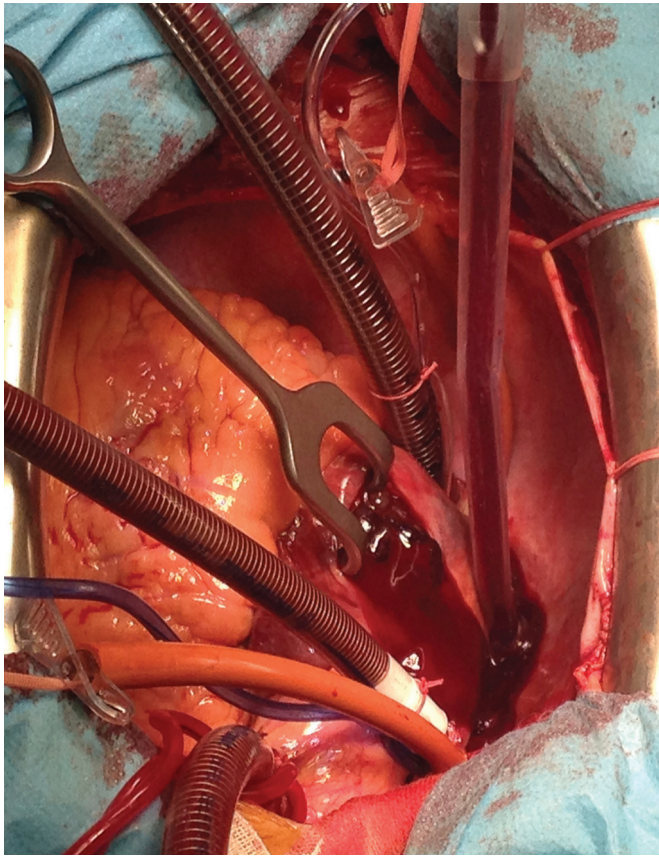


Figure 2. Intraoperative aspect of the tumor after the IVC cannulation.

[Yang 2011], while coronary embolism with concomitant atherosclerosis and myocardial infarction represents the identified mechanism for the development of left heart failure in left-sided myxomas [Boutayeb 2013]. On the other hand, the association between LV systolic dysfunction and right atrial myxomas is at least unusual, complicating the diagnosis and the surgical management of patients in these cases.

Assuming the existence of a cause-effect relationship between the two, the tumoral cardio-depressant effect suggested by Chockalingam et al could have been taken into consideration [Chockalingam 2006]. In this case, though, the abnormal left ventricular kinetics suggested an ischemic cause subsequently ruled out by coronary angiography. To our knowledge, only three similar cases have been reported so far, with two possible explanations: diastolic coronary sinus occlusion or crossed embolism through a permeable foramen ovale, favored by tricuspid valve obstruction, with secondary atrial pressure increase [Boutayeb 2013]. This atrial shunt inversion was also considered by Guhathakurta and Riordan; in 2000 they reported the case of a patient with similar features [Guhathakurta 2000], and in 2007 Kapusta described another case of right atrial myxoma with LV dysfunction, with normal kinetics, venous return and normal aspect on coronarography, with complete recovery of the LV function eight months after excision [Kapusta 2007]. In the absence of a confirmed atrial septal defect, we strongly support the

coronary sinus occlusion theory, considering not only the visible protrusion of the tumor through the sinus ostium, but also the immediate postoperative course of the patient.

The first successful surgical excision of a myxoma was accomplished in 1955 [Guhathakurta 2000]. Currently, complete resection represents the definitive treatment for cardiac myxomas, covering approximately 0.3% of all operations performed with CPB [Al-Sarraf 2010]. Although cardioplegic arrest with aortic clamping represents the standard procedure for myocardial protection [Murayama 2001], continuous perfusion without cross-clamping, on a beating or fibrillating heart, is also an option [Al-Sarraf 2010]. Recently, video-assisted minimally invasive surgery, as well as robotic surgery, has been used on a small series of patients with good results [Al-Sarraf 2010; Tomar 2002]. With less than ten cases of atrial myxoma excision on a beating heart being reported until 2013 [Al-Sarraf 2010; Tomar 2002; Mo 2011], the technique is currently considered feasible in patients with extensive aortic calcifications or with low EF [Al-Sarraf 2010; Loulmet 2008]. In this case, on-pump beating heart surgery seemed to be the treatment of choice. During the main operative time, the manipulation of the tumor on a beating heart may cause its fragmentation with secondary pulmonary embolism, while the excision of the implantation base as well as the surrounding septum without aortic clamping involves the additional risk of gaseous embolism [Boutayeb 2013]. To ensure exposure and complete excision of some deep-seated tumors, the temporary removal of the IVC cannula and a systemic temperature decrease to 25°C might be necessary [Darwazah 2011]. We chose to cannulate the IVC under direct vision, after the portion of the mass extending at this level was resected.

### Conclusion

The association between right atrial myxoma and severe systolic LV dysfunction is extremely rare; to our knowledge this case is the fourth reported in the literature. Although the mechanism responsible for the development of the latter is not completely elucidated, the coronary sinus occlusion theory seems to be the most probable explanation. Despite the associated risks, the on-pump beating heart technique can be a useful option for patients with right atrial myxoma and severe systolic LV dysfunction.

### REFERENCES

- Al-Sarraf N, Al-Shammari F, Arafa O, Al-Fadhli J. 2010. Excision of a left atrial myxoma in the presence of a calcified ascending aorta: a surgical challenge. *Gen Thorac Cardiovasc Surg* 58:101-4.
- Boutayeb A, Marmade L, Bensouda A, Moughil S. 2013. Right atrial myxoma and severe left ventricular dysfunction: which explanations? Which management? *Heart Lung Circ* 22:309-11.
- Chockalingam A, Jaganathan V, Gnanavelu G, Dorairajan S, Chockalingam V. 2006. Severe left ventricular dysfunction in left atrial myxoma-report of 2 cases. *Angiology* 57:119-22.
- Darwazah AK, Eida M, Batrawy M. 2011. Myxoma at junction of inferior vena cava and right atrium: surgical excision. *Tex Heart Inst J* 38:591-3.

- Guhathakurta S, Riordan JP. 2000. Surgical treatment of right atrial myxoma. *Tex Heart Inst J* 27:61-3.
- Irani AD, Estrera AL, Buja LM, Safi HJ. 2008. Batrial myxoma: a case report and review of the literature. *J Card Surg* 23:385-90.
- Kapusta A, Lipiec P, Chrzanowski L, Fory J, Kasprzak JD. 2007. Untypical cause of heart failure--right atrial myxoma. *Pol Arch Med Wewn* 117:470-2.
- Lepillier A, Chaib A, Bougouin W, et al. 2010. Case report and review of a voluminous right atrial myxoma revealed by heart failure. *Ann Cardiol Angeiol (Paris)*. 59:37-9.
- Loulmet DF, Patel NC, Jennings JM, Subramanian VA. 2008. Less invasive intracardiac surgery performed without aortic clamping. *Ann Thorac Surg* 85:1551-5.
- Mo A, Lin H. 2011. On-pump beating heart surgery. *Heart Lung Circ* 20:295-304.
- Murayama H, Tamaki S, Kato N, et al. 2001. Right atrial myxoma associated with atrial septal defect: a case report and review of the literature. *Ann Thorac Cardiovasc Surg* 7:166-9.
- Patil NP, Dutta N, Satyarthi S, Geelani MA, Kumar Satsangi D, Banerjee AJ. 2011. Cardiac myxomas: experience over one decade. *Card Surg* 26:355-9.
- Romeo R, Maugeri C, Ragusa A, Romeo A, Maugeri D, Sorace R. 2012. Massive right atrial myxoma: an unusual presentation in an elderly patient. *Arch Gerontol Geriatr* 55:143-4.
- Tomar AS, Banerjee A, Hazari K, et al. 2002. Anaesthetic considerations for noncoronary surgery on a perfused beating heart under cardiopulmonary bypass. *Ann Card Anaesth* 5:59-62.
- Vizzardi E, D'Aloia A, Chiari E, et al. 2010. Tricuspid valve myxoma in a patient with congestive heart failure. *Cases J* 3:21.
- Yang TY, Tsai JP, Chang CH, Kuo JY, Hung CL. 2011. Giant right atrial myxoma with pulmonary trunk dislodgement causing intermittent tricuspid obliteration and clinical manifestations of right heart failure. *Echocardiography* 28:E183-6.