

Aortic Valve Myxoma in a Young Man: A Case Report and Review of Literature

ZhENCHUN Ji, Longgang Wang, Jiacheng Sun, Wenxue Ye, Yunsheng Yu, Haoyue Huang, Yanqiu Hu, Ziying Yang, Zhenya Shen

Department of Cardiovascular Surgery of the First Affiliated Hospital and Institute for Cardiovascular Science, Soochow University, Suzhou, China

ABSTRACT

Myxoma is the most commonly found cardiac primary tumor. The left atrium is the most common localization of myxoma, followed by the right atrium. However, it is rare in the left and right ventricles. Myxoma originating from cardiac valves is extremely rare. This article presents a case of a 17-year-old male who was admitted due to heart murmur for one year. Transthoracic echocardiography indicated a 1.9 cm round solid mass in the left ventricular outflow tract. Excision surgery and aortic valve replacement were performed in this patient. Histopathology revealed the mass as a myxoma. The aortic valve remains a very rare myxoma localization position. Echocardiography can provide a precise method for myxoma diagnosis. Early excision associated with valve replacement can provide good curative effects.

INTRODUCTION

Primary tumors of the heart have an incidence between 0.0017% and 0.19% in unselected patients at autopsy, with 75% as benign tumors and myxoma comprising 50% of these benign tumors [Reynen 1995; Peters 2006; McAllister 1999]. Most myxomas are located in the left atrium, whereas right atrium localization, and left and right ventricular localization are relatively rare among myxomas [Eslami-Varzaneh 2003]. Here we report a case of an aortic valve myxoma and present a comprehensive review of literature.

CASE REPORT

A 17-year-old male was admitted to our hospital due to a one-year history of heart murmur. The patient denied any chest pain, palpitation, orthopnea, or paroxysmal nocturnal dyspnea. He denied any family history of cardiac tumor. Physical examination showed blood pressure of 117/79 mmHg, temperature of 37.7°, and heart rate of 86 beats/min. On auscultation of the heart, a 2/6 level of systolic blowing murmur

could be heard on the tricuspid region, the 4th left intercostal space. Transthoracic echocardiography (TTE) indicated a 1.9 cm round solid mass attached to the left ventricular surface of the right coronary leaflet in the left ventricular outflow tract, moving with the valve, with hypoechogenic tissue inside the mass (Figure 1). TTE also revealed the maximum aortic velocity (Vmax) was 1.8m/s, and ejection fraction (EF) was 0.52. Electrocardiographic showed inverted T wave in leads II, III and aVF, indicating myocardial ischemia. The results of routine blood laboratory investigations were unremarkable.

The diagnosis of the aortic valve mass was considered as an inflammatory mass, a mural thrombus, a myxoma, or a fibroelastoma. On the basis of its potential embolic risk either of mass itself or of its possible associated thrombus, surgical excision associated with aortic valve replacement was performed five days after the transthoracic echocardiography. Intraoperative inspection identified a round tumor attached to the center of the left ventricular side of the right coronary leaflet. The soft fish-like tumor was about 2 cm in diameter, and its base was about 1 cm. The attachment to the aortic valve was tight, thus the aortic valve together with this tumor was

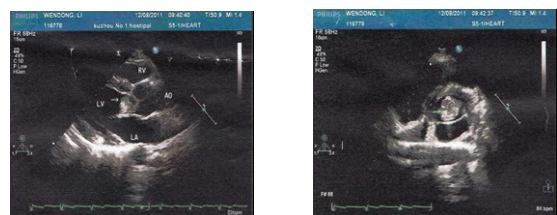


Figure 1. Transthoracic echocardiography revealed a 1.9 cm round solid mass attached to the left ventricular surface of the right coronary leaflet in the left ventricular outflow tract, moving with the valve, with hypoechogenic tissue inside the mass.

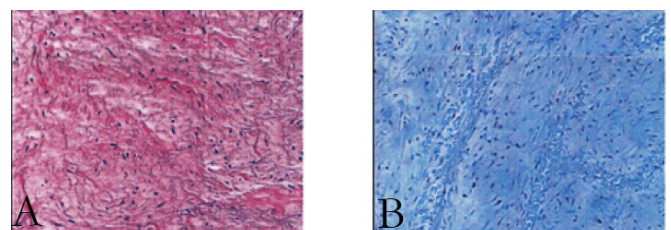


Figure 2. Histopathological examination. The myxoma cells with a stellate appearance or irregular shape scatter in the mucous stroma. Deep-dyed big nucleolus and mitoses could be observed. (A) H-E, ×100. (B) SMA, ×100.

Received January 24, 2017; received in revised form March 31, 2017; accepted April 2, 2017.

ZhENCHUN Ji, Longgang Wang, and Jiacheng Sun contributed equally to this work.

Correspondence: Dr. Zhenya Shen, Department of Cardiovascular Surgery, The First Affiliated Hospital of Soochow University, No. 899 Pinghai Road, Suzhou 215006, Jiangsu Province, China; +86-0512-67972066 (e-mail: zhenyashen@sina.com).

Clinical Presentations of the Reported Cases and the Current Case

Reference	Age	Sex	Clinical Finding	Echocardiography	Size	Complication	Surgery	Location	Comorbidity	Follow-up
Javed et al	81	M	Leg pain	TEE	1.8 × 1.2 cm	AMI	CABG and resection	LCC	HTN, AA	NR in 2y
Kennedy et al	23	M	Leg pain	TTE	1.5 cm	PVD	AVR	RCC and LCC	None	NA
Dyk et al	15	M	Chest pain	TTE & TEE	4 × 1 cm	STEMI	Resection	NCC	None	NA
Prifti et al	13	M	Dyspnea and angina	TTE & TEE	60 × 22 mm	None	AVR	RCC and LCC	None	NR in 3y
Ramsheyi et al	34	M	Facial hemiparesis	TTE & TEE	1 cm	Stroke	AVR	RCC	None	NR in 1y
Fernandez et al	28	M	Hemiparesis	TTE	1.5 × 0.7 cm	Stroke	AVR	RCC and LCC	Epilepsy	NA
Okamoto et al	61	F	Endocarditis	TTE	1 × 1 cm	None	Resection	LCC	HTN, DM	NA
Koyalakonda et al	60	F	Paroxysmal A-fib	TTE & TEE	1 × 1 cm	Stroke	Resection	RCC	A-fib, HTN	NA
Kim et al	72	M	Shortness of breath	TTE	1.5 × 0.8 cm	None	AVR	NCC	HTN, A-fib	NR in 7m
Watarida et al	58	M	Asymptomatic	TTE	1.1 × 1 cm	None	AVR	RCC	HTN	NR in 3y
Current study	17	M	Heart murmur	TTE	2 cm	None	AVR	NCC	None	NR in 5y

TTE indicates transthoracic echocardiography; TEE, transesophageal echocardiography; AVR, aortic valve replacement; MVR, mitral valve replacement; CABG, coronary artery bypass grafting; MVA, mitral valve annuloplasty; DM, diabetes mellitus; HTN, hypertension; LCC, left coronary cusp; NCC, non-coronary cusp; RCC, right coronary cusp; PVD, peripheral vascular disease; AMI, acute myocardial infarction; STEMI, ST segment elevation myocardial infarction; TIA, transient ischemic attack; NR, non-tumor recurrence; NA, not available.

excised and replaced with a SJM MAV #25 mechanical valve prosthesis.

Intraoperative frozen-section examination revealed nodular hyperplasia of fusiform cells, and the pathological type as fibroelastoma. Postoperative histopathological examination (Figure 2) confirmed the tumor as myxoma and mucous degeneration of the aortic valve. The surgical specimen was fixed in 10% neutral buffered formalin. Routine 5 μ m-thick sections were prepared from paraffin-embedded tissue and stained with hematoxylin-eosin or marked by smooth muscle actin (SMA) antibody.

The postoperative course was uneventful. The patient was sent home on postoperative day 10. The patient has been followed up for 5 years, and no recurrence of tumor has been identified.

DISCUSSION

Myxomas account for 50% of cardiac benign tumors [McAllister 1999]. Most myxomas are sporadic, with 94% being solitary [Carney 1985]. Myxomas can originate from any cardiac chambers or cardiac structure, with 75% located in the left atrium [Waller 1995], 10%-20% in the right atrium, 6%-8% in the left ventricle, and 6%-8% in the right ventricle [Eslami-Varzaneh 2003]. A recent literature review based on 73 cases indicated most left ventricle myxomas were single case and originated from the interatrial septum [Abad 2014]. Myxomas of the cardiac valves are very rare, especially those of the aortic valve [Wold 1980]. To our knowledge, only

10 cases of aortic valve myxomas have been reported (Table).

Our patient had a one-year history of heart murmur. However, the reported cases demonstrated a variety of clinical presentations, whose diversity indicated the potential difficulty in clinical diagnosis. On physical examination, two patients had leg pain [Javed 2014; Kennedy 1995], one patient had chest pain [Dyk 2009], one patient had dyspnea and angina [Prifti 2015], two patients had hemiparesis [Ramsheyi 1998; Fernandez 2012], one patient had endocarditis [Okamoto 2006], one patient had paroxysmal atrial fibrillation [Koyalakonda 2011], and one patient had shortness of breath [Kim 2012]. These nonspecific symptoms could easily lead to a missed diagnosis.

According to these 10 cases, 9 were discovered by transthoracic echocardiography (TTE), of which 5 were diagnosed with further examination using transesophageal echocardiography (TEE). Although histopathology remains the gold standard method of diagnosis [Fernandez 2012], TTE provides a simple and economic method for diagnosis, and TEE a more precise method. In a reported case [Javed 2014], CT scan revealed the abnormality of aortic valve.

Despite the nonspecific symptoms and occasional asymptomatic cases, aortic valve myxomas have an undeniable potential embolic risk. Therefore, surgical resection should be indicated as soon as the diagnosis is confirmed. The surgical excision area should include both the tumor and its basilar part. Valve replacement should be performed if the implantation site of the myxoma is on the valve or near the valve [Kennedy 1995; Watarida 1997]. Previous reports have discussed recurrence of cardiac myxoma, though with a low rate,

and follow-up by transthoracic echocardiography for patients who have undergone myxoma resection is highly recommended [Fernandez 2012].

Conclusion

In conclusion, myxoma originating from the aortic valve is a rare but dangerous primary cardiac tumor. TTE and TEE provide a relatively precise method for diagnosis. Early and total resection associated with valve replacement or coronary artery bypass grafting has good curative effects. Echocardiographic examination follow-up is highly recommended.

REFERENCES

- Abad C, Novoa J, Delgado A, Alonso A. 2014. Myxoma of the left ventricle. *Texas Heart Institute J* 41:395-400.
- Carney JA. 1985. Differences between nonfamilial and familial cardiac myxoma. *Am J Surgical Path* 9:53-5.
- Dyk W, Konka M. 2009. Images in cardiothoracic surgery. Unusual complication of aortic valve grape-like myxoma. *Annals Thoracic Surg* 88:1022.
- Eslami-Varzaneh F, Brun EA, Sears-Rogan P. 2003. An unusual case of multiple papillary fibroelastoma, review of literature. *Cardiovasc Path* 12:170-3.
- Fernandez AL, Vega M, El-Diasty MM, Suarez JM. 2012. Myxoma of the aortic valve. *Interactive cardiovascular and thoracic surgery* 15:560-2.
- Javed A, Zalawadiya S, Kovach J, Afonso L. 2014. Aortic valve myxoma at the extreme age: a review of literature. *BMJ case reports*. Epub 2014/03/20.
- Kennedy P, Parry AJ, Parums D, Pillai R. 1995. Myxoma of the aortic valve. *Annals Thorac Surg* 59:1221-3.
- Kim HY, Kwon SU, Jang WI, et al. 2012. A rare case of aortic valve myxoma: easy to confuse with papillary fibroelastoma. *Korean Circulation J* 42:281-3.
- Koyalakonda SP, Mediratta NK, Ball J, Royle M. 2011. A rare case of aortic valve myxoma: an unusual cause of embolic stroke. *Cardiology* 118:101-3.
- McAllister HA, Jr, Hall RJ, Cooley DA. 1999. Tumors of the heart and pericardium. *Current Problems in Cardiol* 24:57-116.
- Okamoto T, Doi H, Kazui T, et al. 2006. Aortic valve myxoma mimicking vegetation: report of a case. *Surgery today*. 36:927-9.
- Peters PJ, Reinhardt S. 2006. The echocardiographic evaluation of intracardiac masses: a review. *J Am Society Echocardiograph* 19:230-40.
- Prifti E, Ademaj F, Kajo E, Baboci A. 2015. A giant myxoma originating from the aortic valve causing severe left ventricular tract obstruction: a case report and literature review. *World journal of surgical oncology*. 13:151.
- Ramsheyi A, Deleuze P, D'Attelis N, Bical O, Lefort JF. 1998. Aortic valve myxoma. *J Cardiac Surg* 13:491-3.
- Reynen K. 1995. Cardiac myxomas. *New England J Med* 333:1610-7.
- Waller BF, Grider L, Rohr TM, McLaughlin T, Taliercio CP, Fetters J. 1995. Intracardiac thrombi: frequency, location, etiology, and complications: a morphologic review--Part I. *Clinical Cardiol* 18:477-9.
- Watarida S, Katsuyama K, Yasuda R, et al. 1997. Myxoma of the aortic valve. *Annals Thoracic Surg* 63:234-6.
- Wold LE, Lie JT. 1980. Cardiac myxomas: a clinicopathologic profile. *Am J Pathology* 101:219-40.