

Off-Pump Excision of Left Atrial Appendage Aneurysm: A Case Report

A. K. Baburaj, MD,¹ T Rameshwara, MCh,¹ Kannan A. Vellachamy, MD,²
Murali P. Vettath, MCh¹

¹Department of Cardiothoracic & Vascular Surgery and ²Department of Cardiothoracic & Vascular Anaesthesia, Malabar Institute of Medical Sciences Ltd., Kozhikode, India

ABSTRACT

Isolated congenital intrapericardial aneurysm of the left atrium (LA) or the left atrial appendage (LAA) is a rare anomaly [Zhao 1999]. The patient usually presents with features of systemic embolization, serious arrhythmia, and severe congestive cardiac failure as a complication, which can be fatal. Once the condition is diagnosed, surgery is indicated [Zhao 1999]. We report a case of congenital left atrial appendage aneurysm in a woman who underwent excision of the same.

CASE REPORT

A 28-year-old woman presented with complaints of palpitation. Her cardiovascular examination was within normal limits. Chest x-ray revealed cardiomegaly with clear lung fields (Figure 1). The echocardiogram showed a cystic lesion (10 × 8 cm) on the left atrial region pushing the LV to the right. The cyst was intrapericardial with no communication to any cardiac chambers. MRI confirmed the size and extent of the lesion lying outside the left border of the heart (Figure 1). Hence the possibility of a pericardial cyst was entertained.

The chest was entered through a left anterolateral thoracotomy. The pericardium was stretched and bulging. There was a large cystic mass of 14 × 10 × 8 cm arising from the left atrial region (Figure 2).

Needle aspiration revealed frank blood and the cyst emptied and refilled gradually. The neck of the cyst was identified to be from the left atrial appendage and it was clamped with a Satinsky clamp and excised. The appendage stump was closed with two rows of running 4/0 polypropylene sutures (Figure 2).

She was hemodynamically stable during and after the procedure. The histopathological examination confirmed the diagnosis of left atrial appendage aneurysm. Her postopera-

tive period was uneventful and she was discharged with no symptoms one week after surgery. On follow-up she continued to be healthy and asymptomatic.

CONCLUSION

Cases of left atrial appendage aneurysm have been reported by Zhao and co-authors [1999], by Parmley [1962], and by Williams [1963]. In 2001, Solomon Victor and co-authors reported on a 43-year-old woman who underwent excision of an aneurysm of the left atrial appendage, which had been causing cerebrovascular episodes [Solomon 2001].

In 1999, Zhao and co-authors reported a 27-year-old man with an aneurysm of the left atrial appendage, which was excised without cardiopulmonary bypass. They preferred a lateral thoracotomy to median sternotomy [Zhao 1999].

Left atrial aneurysms can be classified as either congenital or acquired. Congenital aneurysms are further divided into intrapericardial or extrapericardial. The extrapericardial type is associated with a pericardial defect through which the left atrial appendage or left atrial wall herniated, leading to aneurysmal dilatation of the same. In the intrapericardial type there is no pericardial defect, and it is thought to be due to a developmental weakness in the left atrial wall [Zhao 1999].

The symptoms of left atrial aneurysm include supraventricular arrhythmias, heart failure, embolization, and chest pain. Atrial fibrillation, atrial flutter, and paroxysmal atrial tachycardia are the most common [Coselli 1985]. Arrhythmias can be produced by increased atrial irritability due to dilatation with ectopic focus formation [Coselli 1985; Grinfield 1985; Stone 1990], or may be due to tension on the conduction system from the enlarged atrial muscle mass, a circus movement phenomenon, or a congenital defect in the conduction tissues. Congestive heart failure is the cause of presentation for some patients, but it is a less common symptom [Grinfield 1985; Stone 1990].

The diagnosis of these aneurysms can be difficult. Physical examination is noncontributory. Most results of the cardiac investigations are completely normal. An ECG can display arrhythmia in some patients. Chest x-rays always show cardiac enlargement with a prominent convexity at the upper left cardiac border in the position of left atrial appendage. An echocardiogram may show a left para cardiac chamber with a connection between the aneurysm and the left atrium. Color

Received September 23, 2005; accepted September 26, 2005.

Address correspondence and reprint requests to: Dr. Murali P. Vettath, MCh, Department of Cardiothoracic & Vascular Surgery, Malabar Institute of Medical Sciences Ltd, Minibypass Road, Govindapuram PO, Kozhikode-673016, Kerala, India; 91-495-2744000; fax: 91-495-2741329 (e-mail: mvettathcts@botmail.com).

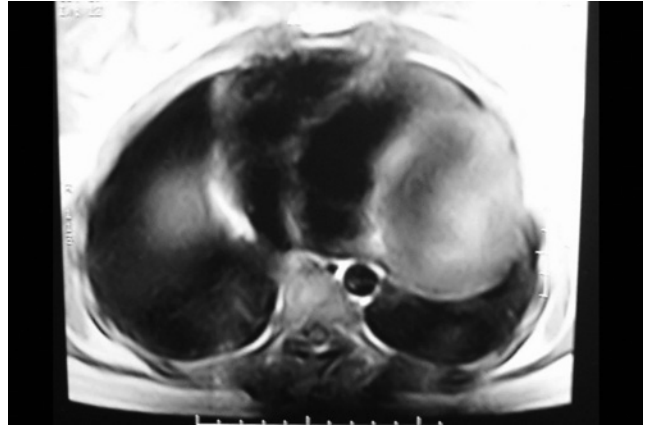
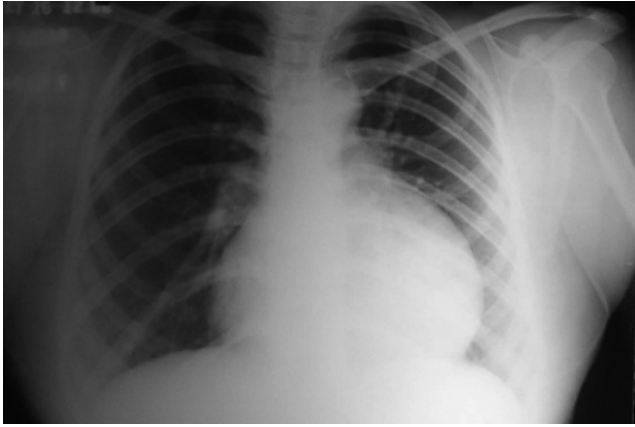


Figure 1. Preoperative chest x-ray (left) and MRI (right).

Doppler studies can confirm an exchange of blood between the two chambers.

After the diagnosis has been made, surgery is indicated even for asymptomatic patients because of the risk of life threatening complications including embolization, arrhythmias, and severe congestive heart failure [Gullestad 1991].

In this case, we were able to perform the excision of the left atrial appendage aneurysm without cardiopulmonary bypass because there was no significant communication

between the cyst and the left atrial appendage. Though we had a pump standby, once we decompressed the cyst, we could resect it out in toto without any difficulty.

REFERENCES

Coselli JS, Beall AC Jr, Ziaddi GM. 1985. Congenital intrapericardial aneurysmal dilatation of the left atrial appendage. *Ann Thorac Surg* 39:466-7

Grinfield R, Trainini JC, Roncoroni A, Fabrykant F, Cacheda H, Tripodi G. 1985. Congenital aneurysm of the left atrium. *Ann Thorac Surg* 39:469-71.

Gullestad L, Flogstad T, Nordstrand K, et al. 1991. Intrapericardial left atrial aneurysm diagnosed by transesophageal echocardiography and nuclear magnetic resonance imaging. *Eur Heart J* 12:277-9.

Parnley LF Jr. 1962. Congenital atriomegaly. *Circulation* 25:553-8

Solomon Victor, Vijaya M Nayak. 2001. Aneurysm of the left atrial appendage. *Tex Heart Inst J* 28(2):111-8.

Stone KS, Brown JW, Canal D, Caldwell R, Hurwitz R, King H. 1990. Congenital aneurysm of the left atrial wall in infancy. *Ann Thorac Surg* 49:476-8.

Williams WG. 1963. Dilatation of the left atrial appendage. *Br Heart J* 25:637-43.

Zhao J, Ge Y, Yan H, Pan Y, Liao Y. 1999. Treatment of congenital aneurysms of the left atrium and left atrial appendage. *Tex Heart Inst J* 26:136-9.

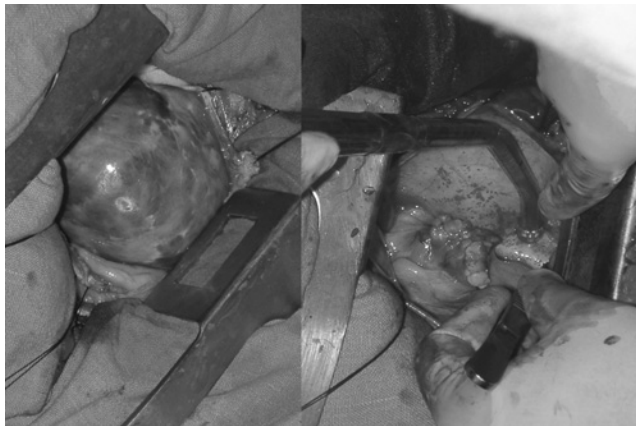

Figure 2. Left atrium appendage aneurysm before and after excision.