

# Single-Patch Fold-Back Technique for Augmentation of the Superior Vena Cava in Sinus Venosus Atrial Septal Defect Associated with Partial Anomalous Pulmonary Venous Return

Suguru Ohira, MD,<sup>1</sup> Kiyoshi Doi, MD, PhD,<sup>1</sup> Takeshi Nakamura, MD, PhD,<sup>2</sup> Hitoshi Yaku, MD, PhD<sup>1</sup>

Department of <sup>1</sup>Cardiovascular Surgery, and <sup>2</sup>Cardiology, Kyoto Prefectural University of Medicine, Kyoto, Japan

## ABSTRACT

Sinus venosus atrial septal defect (ASD) is usually associated with partial anomalous pulmonary venous return (PAPVR) of the right pulmonary veins to the superior vena cava (SVC), or to the SVC-right atrial junction. Standard procedure for repair of this defect is a patch roofing of the sinus venosus ASD and rerouting of pulmonary veins. However, the presence of SVC stenosis is a complication of this technique, and SVC augmentation is necessary in some cases. We present a simple technique for concomitant closure of sinus venosus ASD associated with PAPVR and augmentation of the SVC with a single autologous pericardial patch.

## INTRODUCTION

Sinus venosus atrial septal defect (ASD) with partial anomalous pulmonary venous return (PAPVR) accounts for approximately 10% of patients with ASD. Sinus venosus ASD is commonly located near the superior vena cava (SVC) right atrial (RA) junction. Patch repair is a standard technique to close the ASD and reroute the PAPVR simultaneously [DeLeon 1993; Gajjar 2011]. Surgical procedures not involving artificial materials are being used to repair this type of defect [Warden 1984; Williams 1984; Yamagishi 2000]. However, stenosis or obstruction of the SVC has been reported as a complication of these techniques, and SVC augmentation is necessary in some cases [Gajjar 2011]. Here we describe a simple technique for concomitant closure of sinus venosus ASD associated with PAPVR and augmentation of the SVC with a single patch.

## CASE REPORT

A 56 year old woman was referred to our hospital with dyspnea on exertion and heart palpitations. A clinical diagnosis of sinus venosus ASD with PAPVR was made based on computed

tomography (CT) and transesophageal echocardiography (TEE). Tricuspid annular dilatation was also detected. Surgical repair was performed through a median sternotomy. A pericardial patch was harvested, soaked in 0.625% glutaraldehyde for 10 minutes, then rinsed with saline. The SVC was dissected to assess the anatomy of the PAPVR. Cardiopulmonary bypass (CPB) was initiated with aortic cannulation and bicaval drainage. The SVC was cannulated with a 22 Fr angled cannula just below the SVC and innominate vein junction. After induction of cardiac arrest, the right atrium (RA) was incised longitudinally and the incision extended to expose the ASD and PAPVR along the crista terminalis. A sinus venosus ASD (30×30 mm diameter) was located at the border of the atrial septum near the junction of the SVC and the RA. The orifices of the anomalous pulmonary veins were connected to the junction of the SVC and RA. The autologous glutaraldehyde-treated pericardial patch was trimmed to create two portions. The ASD portion of the patch was flat, half-oval, and 30 mm in diameter, and the SVC portion of the patch was trimmed to a tear-drop shape after closure of the ASD. The smooth surface of the pericardial patch was placed on the left of the ASD. The ASD was closed with this

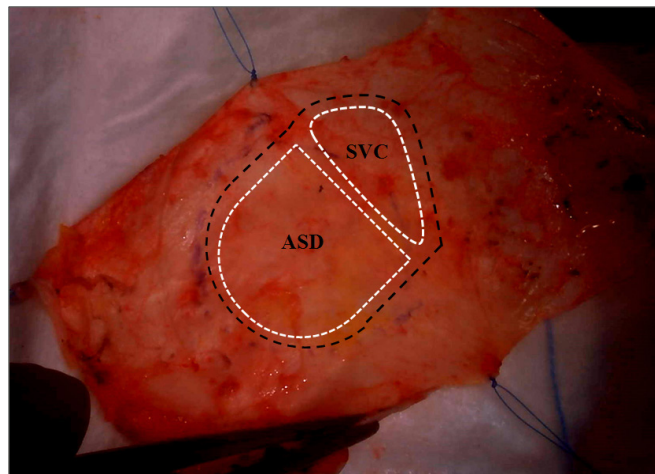


Figure 1. The design of a single autologous patch. It is composed of atrial ASD and SVC portions. Both are encircled by white dashed lines. A single large patch is created by trimming along the black dashed line.

Received October 17, 2014; accepted December 1, 2014.

Correspondence: Suguru Ohira, MD, Department of Cardiovascular Surgery, Kyoto Prefectural University of Medicine, 465 Kajii-cho, Kawaramachi-Hirokoji, Kamigyo-ku, Kyoto 602-8566, Japan; 81-75-2515752; fax: 81-75-2575910 (e-mail: [s-ohira@koto.kpu-m.ac.jp](mailto:s-ohira@koto.kpu-m.ac.jp)).

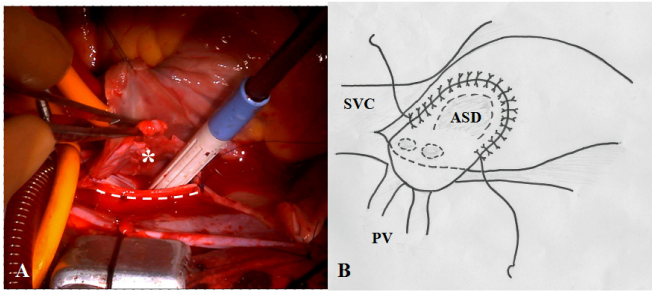


Figure 2. Intraoperative view (A) and schema (B). The ASD is closed and PVs are rerouted with an autologous pericardial patch. The SVC portion of the patch (asterisk) is grasped with forceps. A suction tube is inserted into the left atrium through the ASD. ASD indicates atrial septal defect; SVC, superior vena cava; PV, pulmonary vein.

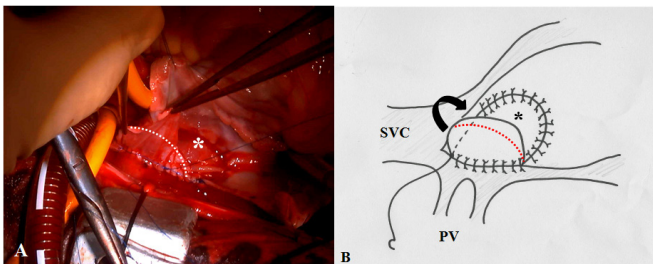


Figure 3. Intraoperative view (A) and schema (B). ASD closure and PV rerouting are completed. The SVC portion of the patch is grasped with forceps. The ASD portion (asterisk) is “folded back” to augment the SVC. The dotted line is for trimming the patch for the SVC portion. ASD indicates atrial septal defect; SVC, superior vena cava; PV, pulmonary vein.

patch using 5-0 polypropylene running suture. Sutures were started on the left side of the ASD (Figure 1). After reaching the right lip of the incised SVC, the patch was “folded back” and the right margin of the incised SVC was closed with serial 5-0 polypropylene running sutures (Figure 2). The left side of the SVC and pericardial patch were sutured in a row. The patch was cut to join the original incision line just above the SVC-RA junction (Figure 3). Tricuspid annuloplasty was performed with a 28 mm, semi-rigid prosthetic ring. After converging the suture line on the SVC, the RA was closed completely (Figure 4). The patient was weaned from CBP uneventfully. Sinus rhythm was maintained and there was no increase in blood flow either in the RA or the SVC. The central venous pressure was 3-5 cm H<sub>2</sub>O. The postoperative course was uneventful, and no stenosis of the SVC or right pulmonary veins was seen on CT.

## DISCUSSION

Various surgical techniques have been described for the treatment of sinus venosus ASD with PAPVR. Patch closure is a standard technique to simultaneously close the ASD and reroute the PAPVR [DeLeon 1993; Gajjar 2011]. The Warden or Williams procedure is a well known technique for ASD closure, with the pulmonary vein returned to the SVC

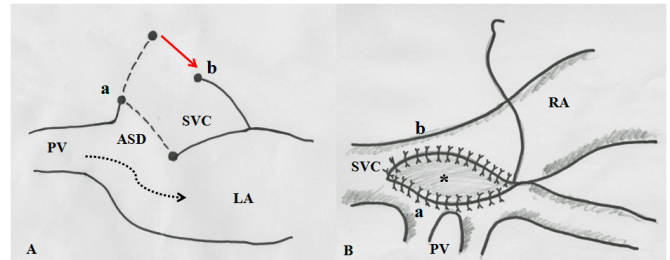


Figure 4. (A) Schema of the fold-back technique (coronal section). The dashed line demonstrates a single autologous patch. Point “a” corresponds to the right lip of the incised SVC. Point “b” corresponds to the left lip of the incised SVC. (B) Schema after the completion of SVC augmentation. The residual right atrial wall was closed directly. ASD indicates atrial septal defect; SVC, superior vena cava; PV, pulmonary vein; LA, left atrium; RA, right atrium.

without artificial materials [Warden 1984; Williams 1984]. However, late SVC stenosis and arrhythmias have been reported as significant complications of this procedure. Yamagishi and colleagues reported the “double-decker technique” to minimize right atriotomy and create a large SVC pathway for sinus venosus ASD with PAPVR [Yamagishi 2000]. The advantages of this technique are prevention of SVC stenosis and postoperative arrhythmia. However, this technique is sometimes difficult to perform in adult cases due to the inflexible nature of the tissue. In the present case, the pulmonary veins returning to the SVC and RA junction comprised the main branches of the right upper lung, and a simple patch closure was performed.

The most serious complication of this type of ASD repair is SVC obstruction or stenosis. When the pulmonary veins drain at the SVC to RA junction, SVC augmentation is preferable to prevent SVC stenosis caused by patch closure of ASD [Gajjar 2011]. The concept of the “single-patch fold-back technique” is concomitant closure of the ASD and enlargement of the SVC with a single pericardial patch to prevent SVC and PV stenosis. First, a single large patch is produced sufficient for ASD closure. Then, sutures are placed to close the ASD up to the right lip of the SVC incision, and the remaining portion of the patch is “folded back” and trimmed for SVC enlargement. Compared to the two-patch technique, the advantages of this procedure are that less suture lines are needed and handling is easier when suturing the SVC portion, because one side of the SVC lip is fixed.

In this case there were no postoperative supraventricular arrhythmias. Postoperative CT showed no stenosis of the augmented SVC or the rerouted right upper PVs. Despite these favorable results, the long-term outcome remains unknown. Therefore, careful follow-up is necessary.

## CONCLUSION

In conclusion, we report a “single-patch fold-back technique” for repair of sinus venosus ASD with PAPVR to prevent postoperative SVC stenosis. This technique is simple, reproducible, and applicable for similar groups of cardiovascular anomalies.

## REFERENCES

- DeLeon SY, Freeman JE, Ilbawi MN. 1993. Surgical techniques in partial anomalous pulmonary veins to the superior vena cava. *Ann Thorac Surg* 55:1222-6.
- Gajjar T, Hiremath CS, Desai NB. 2011. Surgical closure of sinus venosus atrial septal defect using a single patch-transcaval repair technique. *J Card Surg* 26:429-34.
- Warden HE, Gustafson RA, Tarnay TJ, Neal WA. 1984. An alternative method for repair of partial anomalous pulmonary venous connection to the superior vena cava. *Ann Thorac Surg* 38:601-5.
- Williams WH, Zorn-Chelton S, Raviele AA, et al. 1984. Extracardiac atrial pedicle conduit repair of partial anomalous pulmonary venous connection to the superior vena cava in children. *Ann Thorac Surg* 38:345-55.
- Yamagishi M, Fujiwara K, Yaku H, Wada Y, Kitamura N. 2000. Repair of partial anomalous pulmonary venous connection with a minimal atriotomy. *Jpn J Thorac Cardiovascular Surg* 48:370-2.