

## IMAGES IN CARDIOTHORACIC SURGERY

# Multislice Computed Tomography Visualization of the VSTENT Device

Gianluca Polvani, MD,<sup>1</sup> Fabio Barili, MD,<sup>1</sup> Luca Dainese, MD,<sup>1</sup> Veli K. Topkara, MD,<sup>2</sup> Gabriela Segura, MD,<sup>1</sup> Paolo Biglioli, MD<sup>1</sup>

<sup>1</sup>Department of Cardiovascular Surgery, Centro Cardiologico Monzino, University of Milan, Milan, Italy;

<sup>2</sup>Division of Cardiothoracic Surgery, College of Physicians and Surgeons of Columbia University, New York Presbyterian Hospital, Columbia University Medical Center, New York, New York, USA

We present a series of multislice computed tomographic scans of a patient who underwent implantation of stent-based left ventricle-to-coronary artery bypass using the VSTENT (Percardia, Merrimack, NH, USA).

In 2003, a 66-year-old man was admitted to our service for the treatment of coronary artery disease. He agreed to be part of the European multicenter ADVANTAGE study (Adjunctive Treatment with the VCAB/VSTENT Myocardial

Implant System in Coronary Artery Bypass Grft Patients) [Boekstegers 2002; Vicol 2005], which was developed to evaluate the safety and the results of stent-based left ventricle-to-coronary artery bypass using the VSTENT. He underwent implantation of the VSTENT device on the second marginal branch, in adjunct to coronary artery bypass grafting. The perioperative and postoperative course was uneventful.

At 6-month follow-up, the angiography showed the patency of the device. The second marginal branch was occluded at its origin and coronary blood flow was supplied by the VSTENT.

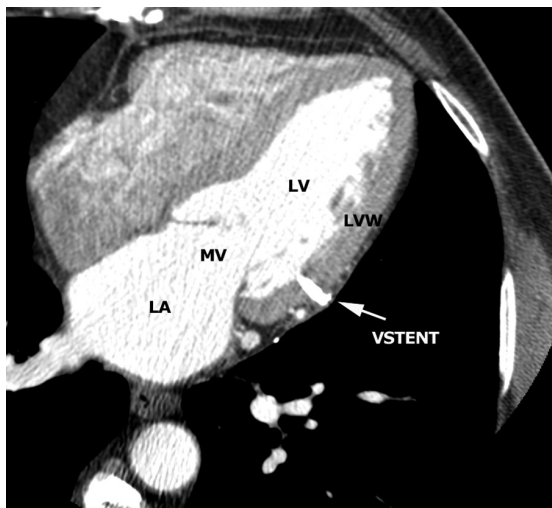


Figure 1. Tomographic scan showing the transmural location of the VSTENT device. LA indicates left atrium; LV, left ventricle; LVW, left ventricular wall; MV, mitral valve.

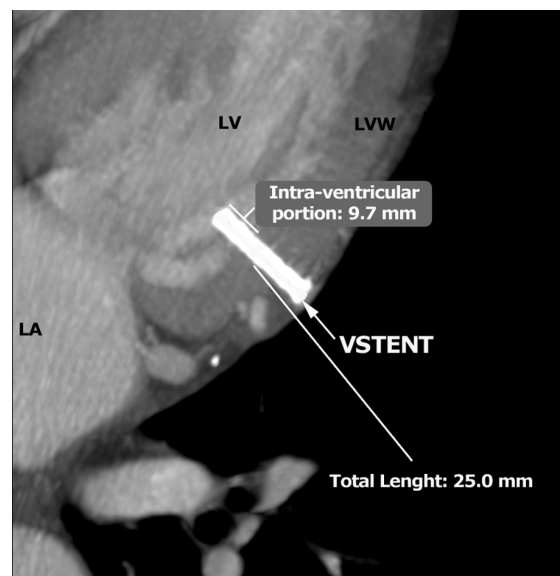


Figure 2. Tomographic scan showing the intraventricular part of the VSTENT device. The total length of the device was 25 mm. The tomographic scan permitted us to evaluate even the length of the intraventricular portion of the VSTENT device. LA indicates left atrium; LV, left ventricle; LVW, left ventricular wall.

Received July 19, 2006; received in revised form September 4, 2006; accepted September 12, 2006.

Correspondence: Fabio Barili, MD, Department of Cardiovascular Surgery, Centro Cardiologico Monzino, University of Milan, Via Parea 4, 20138 Milan, Italy; 39-02-58002355; fax: 39-02-58011194 (e-mail: [fabarili@libero.it](mailto:fabarili@libero.it) or [fabio.barili@unimi.it](mailto:fabio.barili@unimi.it)).

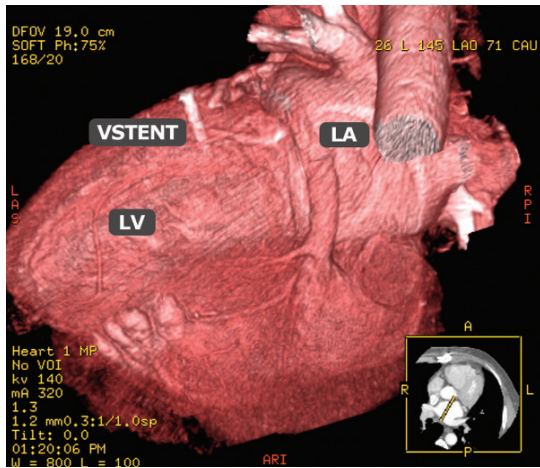


Figure 3. Multislice tomographic 3-dimensional reconstruction showing the VSTENT location. LA indicates left atrium; LV, left ventricle.

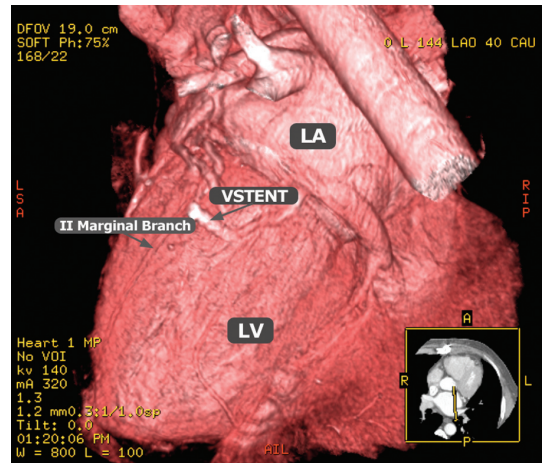


Figure 4. Multislice tomographic 3-dimensional reconstruction showing the second marginal branch perfusion. LA indicates left atrium; LV, left ventricle.

At 16-month follow-up, the patient was asymptomatic (New York Heart Association class I). No ischemic abnormalities were found in resting electrocardiogram or transthoracic Doppler echocardiography. A dobutamine echocardiography stress test did not detect wall motion or perfusion abnormalities. A multislice computed tomography of the chest was performed and it revealed the correct location of the VSTENT (Figures 1-4). It permitted us to evaluate the intraventricular portion of the device and its relationship with other cardiac structures, such as the mitral valve (Figures 1-2). It was not possible to directly assess the intra-stent blood flow as high-density stent material caused blooming artifacts. However, the patency was indirectly confirmed by evidence of second marginal branch perfusion on multislice computed tomography (Figure 4).

Our clinical experience with this and 7 other patients is similar to that reported by others [Boekstegers 2002, 2005;

Vicol 2005]. VSTENT implantation is feasible and safe in the short-term and mid-term follow-up. It guarantees coronary blood flow in the vessel supplied. Its main limitation was the high incidence of VSTENT stenosis that could be prevented with the use of drug-eluting stents [Boekstegers 2005].

## REFERENCES

- Boekstegers P, Raake P, Al Ghobainy R, et al. 2002. Stent-based approach for ventricle-to-coronary artery bypass. *Circulation* 106:1000-6.
- Boekstegers P, Raake P, Hinkel R, et al. 2005. Hemodynamic and vascular effects of ventricular sourcing by stent-based ventricle to coronary artery bypass in patients with multivessel disease undergoing coronary artery bypass surgery. *Circulation* 112(suppl 9):I304-10.
- Vicol C, Reichart B, Eifert S, et al. 2005. First clinical experience with the VSTENT: a device for direct left ventricle-to-coronary artery bypass. *Ann Thorac Surg* 79:573-9.