

Repair of Mycotic Coronary Aneurysm without Cardiopulmonary Bypass: Case Report

Jerry W. Pratt, MD,¹ Gilbert Kukielka, MD,³ David A. Brown, MD²

¹Keesler Medical Center, Keesler Air Force Base, Biloxi, Mississippi; ²Midwestern Cardiac Surgery, Mansfield;

³Division of Cardiology, The Ohio State University, Columbus, Ohio, USA



Dr. Pratt

ABSTRACT

Mycotic aneurysms of the coronary arteries are extremely rare, with 15 cases reported. We report the successful treatment of a mycotic aneurysm of the left anterior descending coronary artery by coronary artery bypass grafting with aneurysm ligation and resection without the use of cardiopulmonary bypass.

INTRODUCTION

Mycotic coronary artery aneurysms are extremely rare and are a subgroup of acquired coronary artery aneurysms. They are associated with myocardial ischemia and infarction, cardiac arrhythmias, pericardial tamponade, and sudden cardiac death [Ebert 1971, McGee 1980, Kalangos 1994, Gebuhrer 1997, Matsumoto 1998, Osevala 1999, Safi 1999]. We describe a patient with an acute myocardial infarction as a result of a mycotic coronary artery aneurysm of the left anterior descending (LAD) coronary artery successfully treated by coronary artery bypass grafting with aneurysm ligation and resection without the use of cardiopulmonary bypass.

CASE REPORT

A 40-year-old man was admitted to our hospital for further evaluation and treatment of right-sided chest pain with associated left hand numbness, which he had during hemodialysis. He had a history of tobacco abuse, cocaine abuse, and end-stage renal disease secondary to longstanding hypertension. He received dialysis via an indwelling dialysis catheter, because two previous arteriovenous fistulas had thrombosed. He had been treated 5 months earlier with antibiotics for a Klebsiella dialysis catheter infection.

The opinions and conclusions in this paper are those of the authors and are not intended to represent the official position of the Department of Defense, United States Air Force, or any other government agency.

Received March 30, 2004; accepted April 1, 2004.

Address correspondence and reprint requests to: David A. Brown, MD, Midwestern Cardiac Surgery, Inc, 770 Balgreen DR, Suite 107, Mansfield, OH 44906, USA; 1-419-522-0320; fax: 1-419-522-0350 (e-mail: dabrown@mwcinc.com).

Physical examination results were normal. Electrocardiogram and serum cardiac enzymes were consistent with an anteroseptal myocardial infarction. Cardiac catheterization revealed a 90% lesion of the LAD (75%-95% luminal narrowing) after the first septal perforator with sacular aneurysmal dilatation. There was no significant stenosis of the circumflex or right coronary arteries; there was mild left ventricular systolic dysfunction and hypertrophy. The patient was referred for surgical evaluation (Figure 1).

SURGICAL TECHNIQUE

The left internal mammary artery (LIMA) was mobilized using direct visualization via a median sternotomy. The pericardium was opened revealing a large-caliber LAD and a 3.0-cm bulge lateral to the pulmonary artery. The LIMA was anastomosed to the LAD after stabilization was achieved on the beating heart (Octopus III; Medtronic, Minneapolis, MN, USA) without the use of cardiopulmonary bypass. The proximal LAD was then ligated just distal to the mass using 3-0 polypropylene suture. Proximal to the mass, the LAD was compressed and occluded with a 3-0 polypropylene tourniquet; occlusion was demonstrated by flow through an 18-gauge needle inserted in the aneurysm.

The electrocardiogram revealed significant anterior lead ST segment elevation during the occlusion despite the patent LIMA anastomosis downstream. The patient remained hemodynamically stable and no wall motion abnormalities were noted on transesophageal echocardiogram. The aneurysm was then opened longitudinally revealing a heavily calcified LAD wall and a 4-mm perforation with a green hematoma contained within a fibrous pseudoaneurysm. The LAD perforation was oversewn with 4-0 polypropylene sutures within the pseudoaneurysm, and the tourniquet was released with rapid ST segment resolution, presumably due to reperfusion of the first septal perforator. Cultures and microscopic examination results of the pseudoaneurysm were negative for organisms.

On postoperative day 5 the patient underwent elective excision of a thrombosed, aneurysmal brachial artery arteriovenous fistula. The patient was discharged that same day after an otherwise uneventful postoperative course and received 6 weeks of broad-spectrum antibiotic coverage. Two months later, the patient presented again with chest pain. Cardiac enzymes were normal and an electrocardiogram was

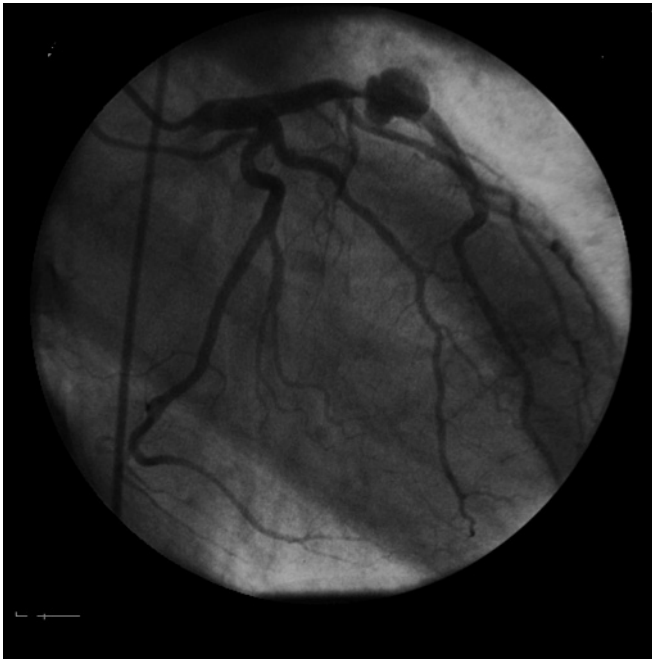

Figure 1. Before surgery, cardiac catheterization revealed a 90% lesion of the left anterior descending artery after the first septal perforator with a sacular aneurysmal dilatation.

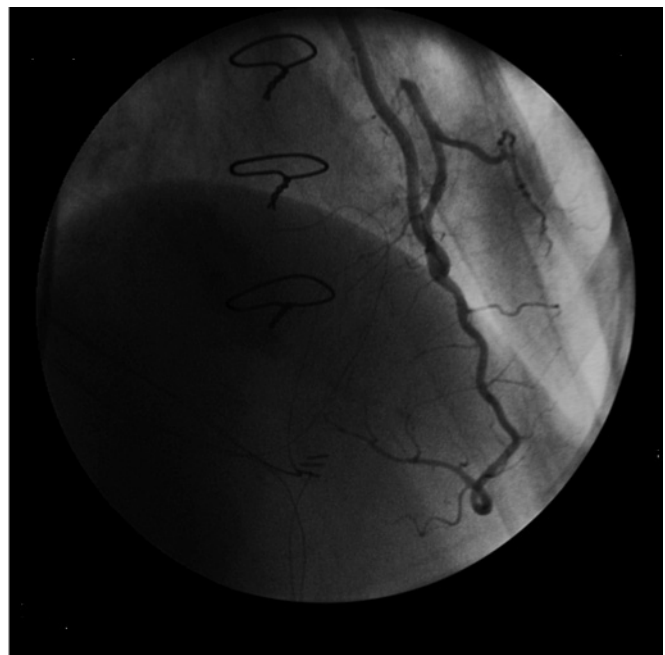


Figure 2. After surgery, cardiac catheterization revealed a widely patent left internal mammary artery-left anterior descending artery (LAD) anastomosis and a patent LAD proximal to the first septal perforator.

unchanged. Cardiac catheterization revealed a widely patent LIMA-LAD anastomosis and a patent LAD proximal to the first septal perforator (Figure 2). The patient died 11 months later from a gastrointestinal hemorrhage.

DISCUSSION

Isolated coronary artery aneurysms are extremely rare, with a reported incidence of 0.3% to 4.9% of angiograms. These aneurysms are either congenital or acquired. Most acquired coronary artery aneurysms are a result of atherosclerosis. Other causes include Kawasaki disease, vasculitis, dissection, trauma, complications of percutaneous coronary angioplasty, and infections [Safi 1999]. Mycotic aneurysms occur in approximately 2.6% of all aneurysms and in approximately 3% to 15% of cases of endocarditis [Reece 1994, Safi 1999]. Fifteen cases of mycotic coronary artery aneurysms have been reported, with the majority diagnosed postmortem [Reece 1994, Osevala 1999]. The term mycotic was coined by Osler in 1885 and refers to bacterial invasion of the vasa vasorum or intima that progresses to necrosis of the vascular wall, leading to aneurysmal dilatation [Reece 1994, Matsumoto 1998]. The microorganisms reported with mycotic aneurysms include *Staphylococcus aureus*, *Streptococcus viridans*, *Clostridium perfringens*, *Salmonella sp*, and syphilis [Gebuhrer 1997, Kalangos 1994, McGee 1980, Osevala 1999], although cryptogenic or mycotic coronary artery aneurysms in the absence of underlying infectious endocarditis have been reported [Safi 1999].

The clinical significance of this lesion is variable. Although most patients are probably asymptomatic and

undiagnosed, symptoms are life threatening and include angina and myocardial infarction, distal embolization, or vessel thrombosis [Ebert 1971, Kalangos 1994, Gebuhrer 1997, Matsumoto 1998]. Sick sinus syndrome [Kalangos 1994], cardiac tamponade, and sudden death secondary to coronary artery rupture [McGee 1980, Kalangos 1994, Osevala 1999, Safi 1999] have also been reported. Intervention for coronary artery aneurysms has advanced as surgical technology and experience have grown. Ebert et al [1971] reported the first patient treated by resection and grafting of a coronary artery aneurysm with revascularization using an interposed saphenous vein graft. Since this report, little has changed in the therapy for mycotic coronary artery aneurysms. Because of the potential life-threatening outcomes, prompt surgical intervention is required. Surgery should include ligation to prevent distal embolization and/or resection of localized aneurysm and distal coronary artery revascularization with arterial or venous graft [Kalangos 1994, Reece 1994]. Long-term antibiotic therapy is also recommended.

In this case, minimally invasive surgical revascularization techniques and complete aneurysm resection were effectively employed in the treatment of a mycotic coronary artery aneurysm of the LAD. Most anterior wall vessels may be readily bypassed without the use of cardiopulmonary bypass. The objective with this procedure was to establish distal flow prior to aneurysm ligation and resection, which was deemed necessary to avoid the future risk of distal embolization or subsequent rupture. The avoidance of cardiopulmonary bypass may decrease the risk of sepsis in actively infected patients as well as greatly simplifying the procedure.

We feel that minimally invasive coronary artery bypass techniques are appropriate alternatives to aortocoronary grafting with cardiopulmonary bypass in the management of mycotic coronary artery aneurysms.

ACKNOWLEDGEMENT

We would like to thank Kelly Knott for her assistance with the preparation of this manuscript.

REFERENCES

- Ebert PA, Peter RH, Gunnells JC, Sabiston DC Jr. 1971. Resecting and grafting of coronary artery aneurysm. *Circulation* 43:593-8.
- Gebuhrer V, Genoud JL, Andre-Fouet X, et al. 1997. Coronary artery mycotic aneurysm discovered by transesophageal echocardiography. *Eur Heart J* 18: 352.
- Kalangos A, Julia PL, Ozler A, Jebara VA, Fabiani JN, Sezerman O. 1994. Successful surgical treatment of a coronary artery mycotic aneurysm. *Ann Thorac Surgery* 58:1521-3.
- Matsumoto M, Konishi Y, Miwa S, Minakata K. 1998. Mycotic aneurysm of the left coronary artery. *Ann Thorac Surg* 65:841-2.
- McGee M, Khan M. 1980. Ruptured mycotic aneurysm of a coronary artery: a fatal complication of salmonella infection. *Arch Intern Med* 140:1097-8.
- Osevala M, Heleotis T, DeJene A. 1999. Successful treatment of a ruptured mycotic coronary artery aneurysm. *Ann Thorac Surg* 67:1780-2.
- Reece IJ, al Tareif H, Tolia J, Saeed FA. 1994. Mycotic aneurysm of the left anterior descending coronary artery after aortic endocarditis: a case report and brief review of the literature. *Tx Hrt Inst J* 21:231-5.
- Safi J Jr, Castelli JB, Kalil-Filho R, Mansur AJ. 1999. Cryptogenic mycotic aneurysm of the right coronary artery. *South Med J* 92:67-8.