

## Simplified Placement of Multiple Artificial Mitral Valve Chords

Nicholas C. Dang, MD, Allan S. Stewart, MD, Joy Kay, BS, Michelle L. Mercando, BS, Kurt H. Kruger, BS, Veli K. Topkara, MD, Mehmet C. Oz, MD

Division of Cardiothoracic Surgery, Department of Surgery, Columbia University, College of Physicians and Surgeons, New York, NY, USA

### ABSTRACT

**Background:** The use of artificial chords for the replacement of diseased mitral valve chordae and the correction of anterior and posterior leaflet prolapse is well described, although it is infrequently applied because of technical challenges.

**Methods:** A simplified approach to attaching the new chords to a single papillary muscle base within the left ventricle has been reported, and we present a series of 13 patients with moderate-severe mitral regurgitation (MR) who underwent chordal replacement using this improved technique.

**Results:** The MR grade by echocardiogram improved from  $3.7 \pm 0.4$  preoperatively to  $1.0 \pm 0.8$  postoperatively. All patients were doing well at a mean follow-up interval of  $285 \pm 62$  days.

**Conclusion:** Chordal replacement for both anterior and posterior leaflet prolapse is an effective treatment for MR when combined with standard mitral valve repair techniques. The authors' technique of determining proper chordal height and placing multiple chordae is also discussed.

### INTRODUCTION

Mitral regurgitation (MR) secondary to disease of mitral valve (MV) chordae and associated anterior and posterior leaflet prolapse is sometimes approached surgically by chordae tendineae replacement. Several reports have commented on the successful use of expanded polytetrafluoroethylene (ePTFE) (Gore-Tex; W. L. Gore and Associates, Flagstaff, AZ, USA) as an optimal suture material for chordal replacement [David 1996, 1998, Kobayashi 2000]. These techniques can be combined with other MV repair procedures such as quadrangular resection and sliding leaflet repair, ring annuloplasty, and anterior-to-posterior leaflet edge-to-edge repair. However, the use of ePTFE is uncommon because the proper suture height can be difficult to determine and confirm while securing the sutures through the leaflets. In addition, the

technique itself is cumbersome. A report by von Oppell and Mohr [von Oppell 2000] proposes a novel means of securing numerous ePTFE chords to a single papillary muscle base within the left ventricle and presetting the chordal height to facilitate surgeon use.

We describe a series of 13 patients with moderate-severe MR who underwent MV repair with chordal replacement to either or both of the anterior and posterior leaflets by means of the Mohr technique. The method of determining proper chordal height, as well as placing multiple chordae to the same and different leaflets, is discussed.

### MATERIALS AND METHODS

#### Clinical Experience

From December 2003 to July 2004, 13 patients with moderate-severe MR were evaluated and deemed candidates for MV repair with chordal replacement. Eleven (84.6%) of the patients were male. The mean ( $\pm$ SD) age was  $64.8 \pm 13.2$  years (range, 41-82 years). The mean preoperative MR grade by echocardiogram was  $3.7 \pm 0.4$ . The mean preoperative left ventricular ejection fraction was 59.1%. One patient with chronic atrial fibrillation was scheduled for a concomitant MAZE procedure. An additional 4 patients who had notable coronary artery disease were scheduled for concomitant coronary artery bypass graft (CABG) procedures. All patients underwent operation by the same primary surgeon (M.C.O.) over the 8-month period.

#### Surgical Procedures

The primary MV repair procedure and any concomitant procedures for each patient are outlined in the Table. ePTFE suture was the chord material used, and annuloplasty rings were placed in all patients.

To determine the proper height for each replacement chord, we favor the technique described by von Oppell and Mohr [von Oppell 2000]. This length is determined by measuring the distance between the papillary muscle and the correct plane of apposition on an adjacent, nonprolapsed segment. The distance is set on a Mohr Suture Ruler Chordae Tendineae Measuring and Knotting device (03-5409; Geister, Tuttlingen, Germany) (Figure 1), and "premeasured" loops with 4-0 ePTFE suture are created by passing both ends of the suture through a small felt pledget and tying a knot. A separate 3-0 Tevdek suture (Deknatel Medical, Fall River, MA,

Received January 18, 2005; accepted March 6, 2005.

Address correspondence and reprint requests to: Mehmet C. Oz, MD, Director, Cardiovascular Institute, Division of Cardiothoracic Surgery, Department of Surgery, Columbia University, College of Physicians and Surgeons, 177 Fort Washington Ave, Milstein Hospital, 7GN-435, New York, NY 10032, USA; 1-212-305-4434; fax: 1-212-305-2439 (e-mail: [mco2@columbia.edu](mailto:mco2@columbia.edu)).

## Surgical Procedures\*

Patient No.	Mitral Valve Repair Procedure	Concomitant Procedures
1	ePTFE chords to p1; 30-mm Cosgrove ring	None
2	ePTFE chords to a2, p1; p2 resection; 32-mm Cosgrove ring	None
3	ePTFE chords to a3, p3; 30-mm Cosgrove ring	None
4	ePTFE chords to a2; p2 resection; 34-mm Cosgrove ring	MAZE
5	ePTFE chords to p2; 32-mm Cosgrove ring	None
6	ePTFE chords to p1, p2; 30-mm Cosgrove ring	None
7	ePTFE chords to a1; 32-mm Cosgrove ring; a1-p1 edge-to-edge repair	None
8	ePTFE chords to a1; p2 resection; sliding annuloplasty; 32-mm Cosgrove ring	None
9	ePTFE chords to p2; 32-mm Carpentier-Edwards ring	CABG
10	ePTFE chords to p2, p3; 29-mm Taylor ring	CABG
11	ePTFE chords to a1; 30-mm Carpentier-Edwards ring	CABG
12	ePTFE chords to p3; 34-mm Cosgrove ring	CABG
13	ePTFE chords to p2, p3; 30-mm Carpentier-Edwards ring; a3-p3 edge-to-edge repair	None

\*ePTFE indicates expanded polytetrafluoroethylene; p1, posterior leaflet segment 1; a2, anterior leaflet segment 2; CABG, coronary artery bypass grafting.

USA) is passed through the same pledget and then secured to the appropriate papillary muscle. The loop end is then sutured to the edge of the prolapsed leaflet segment with another 4-0 ePTFE suture.

If multiple chords are to be placed to the same leaflet, the distance of each chord is measured from the papillary muscle to the precise insertion site on that leaflet. This measuring technique can be applied to chords that span to different leaflet segments as well. On the papillary muscle end, a slightly larger felt pledget is used, and the additional chord loops are simply passed through the upper end of the pledget (Figure 2). A separate 3-0 Tevdek suture again anchors the pledget to the papillary muscle. If further support is necessary, another papillary muscle can be used as the base for additional chords (Figure 3).

## RESULTS

The mean postoperative MR grade by echocardiogram was  $1.0 \pm 0.8$  at a mean follow-up interval of  $22 \pm 36$  days. No patient had a postoperative MR grade greater than 2+. All

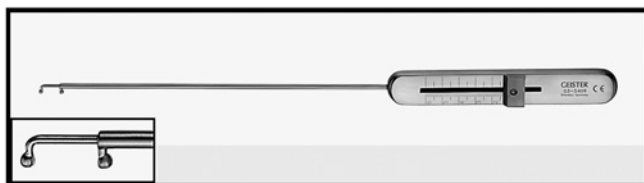


Figure 1. Mohr Suture Ruler Chordae Tendineae Measuring and Knotting device. The proper chordal height is set by the ruler on the device handle, and expanded polytetrafluoroethylene loops are created around the prongs at the distal tip.

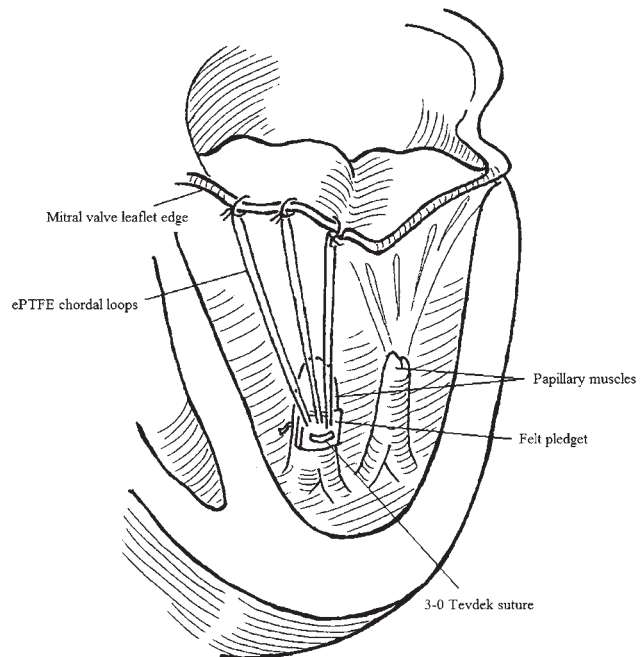


Figure 2. The premeasured expanded polytetrafluoroethylene (ePTFE) loops are extended from a single felt pledget placed on the corresponding papillary muscle. The loops are then secured to the edge of the mitral valve leaflet with an additional 4-0 ePTFE suture.

patients reported improved symptoms related to MR at a mean follow-up interval of  $285 \pm 62$  days. Two of the patients who had undergone concomitant CABG developed new-onset atrial fibrillation. One of these patients experienced a left parietal infarct, leading to transient expressive aphasia on postoperative day 2. She was placed on aspirin and amiodarone therapy, and her neurologic status returned to baseline by the time she was discharged from the hospital on postoperative day 6.

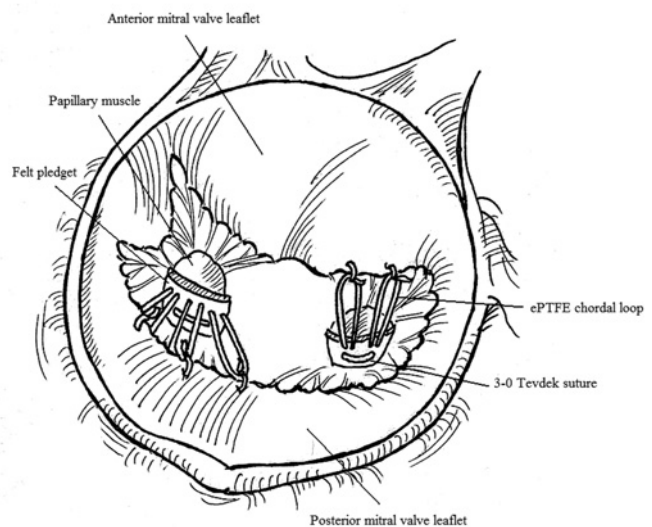


Figure 3. Multiple expanded polytetrafluoroethylene (ePTFE) loops from separate papillary muscles to opposing mitral valve leaflets, atrial view.

## DISCUSSION

In most instances of myxomatous disease of the MV, adequate leaflet tissue exists for the excision of diseased areas. For flail posterior leaflets, quadrangular resection is usually performed, with or without sliding plasty. Repair of anterior leaflet prolapse is technically more demanding and includes such techniques as triangular resection, shortening of papillary muscles, chordal shortening, and chordal transfer. Less commonly, the chordae are damaged by infection, infarction, or calcification and are amenable to isolated repair. With the desire to offer a simpler approach, Frater and David introduced the concept of chordal replacement using ePTFE sutures for MV repair [David 1996, Frater 1996], and this technique has been adopted successfully by many surgeons. One of the challenges of this technique, however, is determining and creating the proper chordal height to ensure adequate leaflet coaptation. Indeed, when the chords are tied on the atrial surface of the leaflet, the height can sometimes be altered with a tendency toward over-shortening. Numerous tactics have since been described to achieve the exact necessary chordal height, but we favor the technique described by von Oppell and Mohr.

This technique uses a ruler device that permits precise measurement of the proper chordal length and facilitates the creation of “premeasured” chordal loops, thereby obviating adjustment of the chords after they have been placed. If, however, the chord is felt to be too short, additional length can be introduced into the second ePTFE suture that secures the chordal loop to the leaflet edge. If the chord is felt to be too long, it can be twisted several times before being sutured to the leaflet edge. By placing a single felt pledget on the pap-

illary muscle, the surgeon is able to use a uniform base from which multiple chords can be extended. If even more artificial chords are required, the same technique can be applied to a separate papillary muscle, and the chords are spanned to either the same or different leaflet segments.

In our still limited and short-term experience, ePTFE chordal placement for both anterior and posterior leaflet prolapse is an effective treatment for MR when combined with standard MV repair techniques. Determination of the proper chordal height is of paramount importance for achieving successful repair, and methods to further refine these efforts may eventually pave the way toward more efficient minimally invasive and percutaneous approaches.

## REFERENCES

- David TE, Armstrong S, Sun Z. 1996. Replacement of chordae tendineae with Gore-Tex sutures: a ten-year experience. *J Heart Valve Dis* 5:352-5.
- David TE, Omran A, Armstrong S, et al. 1998. Long-term results of mitral valve repair for myxomatous disease with and without chordal replacement with expanded polytetrafluoroethylene sutures. *J Thorac Cardiovasc Surg* 115:1279-85; discussion 1285-6.
- Frater RW. 1996. 10th Goretex chorda anniversary. *J Heart Valve Dis* 5:348-51.
- Kobayashi J, Sasako Y, Bando K, et al. 2000. Ten-year experience of chordal replacement with expanded polytetrafluoroethylene in mitral valve repair. *Circulation* 102:III-30-4.
- von Oppell UO, Mohr FW. 2000. Chordal replacement for both minimally invasive and conventional mitral valve surgery using premeasured Gore-Tex loops. *Ann Thorac Surg* 70:2166-8.