

Incidental Gossypiboma Discovered during Tricuspid Valve Re-Repair 11 Years after Ebstein Anomaly Repair

Tornike Sologashvili, MD,¹ Afksendiyos Kalangos, MD, PhD,¹ Cécile Tissot, MD,² Patrick O. Myers, MD¹

¹Division of Cardiovascular Surgery, Geneva University Hospitals and School of Medicine, Geneva;

²Unit of Pediatric Cardiology, Children's University Hospital Geneva and School of Medicine, Geneva, Switzerland

ABSTRACT

Background: A retained surgical sponge, an extremely rare occurrence after cardiac surgery, can trigger a granulomatous reaction and form a sizeable mass or gossypiboma. We report the incidental operative finding of a gossypiboma 11 years after repair of Ebstein anomaly.

Case Report: A 24-year-old man, who had previously undergone tricuspid annuloplasty for Ebstein anomaly 11 years earlier at another institution, was referred for recurrent severe tricuspid regurgitation. During the dissection along the superior vena cava and the right atrium, we entered 2 cystic cavities that exuded a pus-like material, which was sent for culture. Mesh from a retained surgical sponge (gossypiboma) was identified. After complete debridement and administration of vancomycin, the tricuspid valve was repaired. Antibiotics were continued until culture results were confirmed to be negative. The patient's postoperative course was uneventful, and he presented no signs of infection.

Conclusions: We report a rare case of incidentally found gossypiboma after cardiac surgery.

INTRODUCTION

Despite extreme caution and the introduction of checklists, leaving a foreign object within the operative wound can occur, although it is extremely rare. A retained surgical sponge can trigger a granulomatous reaction and form a sizeable mass, also called a gossypiboma. If such incidents are rare following abdominal or orthopedic surgery, they are extremely rare after thoracic surgery [Vayre 1999]. We report the incidental operative finding of a gossypiboma 11 years after repair of Ebstein anomaly.

Received January 29, 2013; received in revised form July 15, 2013; accepted July 17, 2013.

Correspondence: Patrick O. Myers, MD, Division of Cardiovascular Surgery, Geneva University Hospitals and School of Medicine, 4, Rue Gabrielle-Perret-Gentil, 1211 Geneva 14, Switzerland; 41-22-372-7638; fax: 41-22-372-7634 (e-mail: patrick.myers@hcuge.ch).

CASE REPORT

A 24-year-old man, who had previously undergone repair of an atrial septal defect at 6 years of age and then tricuspid De Vega annuloplasty for Ebstein anomaly at 13 years at another institution, was referred for recurrent severe tricuspid regurgitation and syncope due to intermittent supraventricular tachycardia. The echocardiogram showed severe tricuspid regurgitation from apical displacement and tethering of the septal leaflet, anterior and posterior leaflet prolapse, moderate right atrial and right ventricular dilatation, and a normal systolic function. The results of a 24-hour Holter examination were negative.

The patient underwent repeat tricuspid valve repair. During the dissection along the superior vena cava and right atrium, we identified and entered 2 cystic cavities that exuded a pus-like material, which was sent for culture. The results of a gram stain were negative. We identified mesh from a retained surgical sponge (gossypiboma), likely from the operation 11 years earlier. The cysts were removed entirely, the area was washed with Betadine and antibiotic solution, and vancomycin was administered. We repaired the tricuspid valve with a modified cone repair, including annuloplasty with a 28-mm Carpentier-Edwards Physio II ring (Edwards Lifesciences, Irvine, CA, USA) and anterior leaflet neochordae to relieve prolapse. Antibiotics were continued until cultures were confirmed to be negative for infection. The postoperative course was uneventful, and the patient presented no signs of infection.

Our post hoc review of the preoperative imaging showed no evidence for the gossypiboma on chest radiography (Figure 1), transthoracic echocardiography, or transesophageal echocardiography. Magnetic resonance imaging data from the patient's previous institution showed a mass on the right lateral aspect of the superior vena cava (Figure 2). The patient denied any history of recurrent fevers or unexplained bacteremia after his initial operation.

DISCUSSION

A retained surgical sponge is, luckily, a rare occurrence in the current era. It usually elicits a granulomatous reaction forming a cyst and manifests itself with unexplained postoperative inflammatory syndrome, fevers, and aches [Vayre 1999], although it is

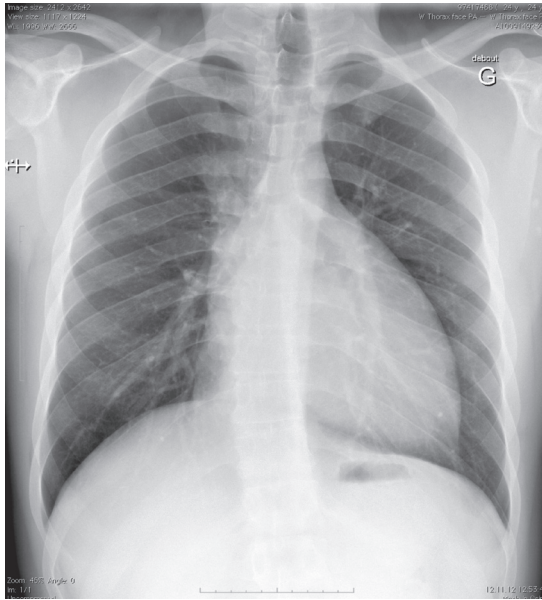


Figure 1. Anteroposterior chest radiograph.

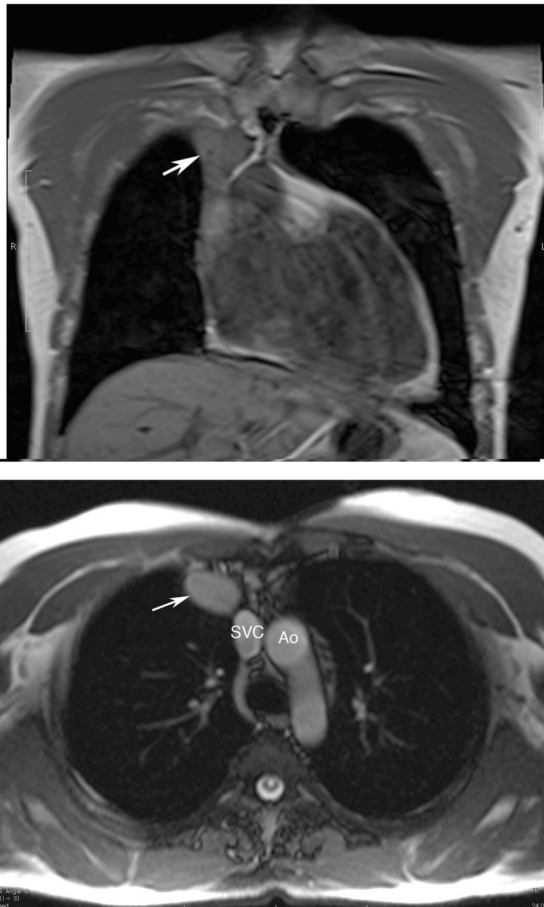


Figure 2. Magnetic resonance imaging. Cystic mass (arrows) on the antero-lateral aspect of the superior vena cava (SVC). Ao indicates aortic arch.

clinically silent in up to 6% of patients [Wan 2009]. Secondary infection of the cotton matrix can manifest itself as a nonspecific inflammatory reaction. Three quarters of gossypibomas occur after abdominal or pelvic surgery, and two thirds occur after planned elective surgery [Okur 2009; Wan 2009]. Risk factors for gossypibomas include case-related factors, such as emergency procedures, lengthy procedures, unexpected changes in procedure, multicavity cases, high body mass index, and shift changes, as well as operating room environmental risk factors (such as poor communication; absent, incomplete, or interrupted sponge counts; absence of a standardized count policy; and use of non-radio-opaque sponges in cases involving large cavities, such as the chest or abdomen [Wan 2009]). Although pus is often found at surgical exploration, this material is most often sterile, and antibiotic treatment is not always necessary. An intrathoracic gossypiboma is relatively rare, and even fewer have been reported after cardiac surgery [Okur 2009; Hochhegger 2012]. An asymptomatic mass on a chest radiograph is a frequently reported presentation [Szarf 2009; Hochhegger 2012]; however, given the low incidence of gossypiboma, the variety of symptoms, and their nonspecific radiologic findings, making a correct preoperative diagnosis can be difficult, particularly if a radio-opaque marker is not present [Szarf 2009].

Features of gossypibomas apparent in plain chest radiographs include a heterogeneous mass, which can be calcified or contain both dense material and air pockets [Vayre 1999]. Echocardiography shows a well-defined mass with no extension to adjacent structures, a thick contour, heterogeneous content, acoustic shadowing, and no Doppler flow within the mass [Tsutsui 2003]. Computed tomographic features of gossypibomas include a spongiform appearance with gas bubbles, a low-density mass with a thin enhancing capsule, and calcifications deposited along the network architecture of a surgical sponge [Kopka 1996]. Gossypibomas within the pleural space can show no gas lucencies, because of resorption of the air by the pleura [Sheehan 2000]. Radio-opaque markers are often mistaken for calcification, either of the pleura or of the rim of a hematoma [Kopka 1996]. Magnetic resonance imaging shows gossypibomas as well-delineated formations with low signal intensity on T1-weighted images and very high signal intensity on T2-weighted images, although structures with low signal intensity with wavy, striped, and/or spotted appearances within the mass have also been described [Sugimura 1992; Vayre 1999; Tsutsui 2003].

In conclusion, we report a rare case of incidentally found gossypiboma after cardiac surgery.

REFERENCES

- Hochhegger B, Zanetti G, Garcia TS, Marchiori E. 2012. Retained surgical sponge presenting as a cardiac mass. *Eur J Cardiothorac Surg* 41:e129.
- Kopka L, Fischer U, Gross a J, Funke M, Oestmann JW, Grabbe E. 1996. CT of retained surgical sponges (textilomas): pitfalls in detection and evaluation. *J Comput Assist Tomogr* 20:919-23.
- Okur H, Okur E, Baran R. 2009. Three cases of intrathoracic gossypiboma with varying morbidities depending on the time of detection. *Thorac Cardiovasc Surg* 57:432-4.

Sheehan RE, Sheppard MN, Hansell DM. 2000. Retained intrathoracic surgical swab: CT appearances. *J Thorac Imaging* 15:61-4.

Sugimora H, Tamura S, Kakitsubata Y, et al. 1992. Magnetic resonance imaging of retained surgical sponges. Case report. *Clin Imaging* 16:259-62.

Szarf G, Mussi de Andrade TC, Nakano E, et al. 2009. Forty-year-old intrathoracic gossypiboma after cardiac valve surgery. *Circulation* 119:3142-3.

Tsutsui JM, Hueb WA, Nascimento SA, Borges Leal SM, De Andrade JL, Mathias W. 2003. Detection of retained surgical sponge by transthoracic and transesophageal echocardiography. *J Am Coll Cardiol* 16:1191-3.

Vayre F, Richard P, Ollivier JP. 1999. Intrathoracic gossypiboma: magnetic resonance features. *Int J Cardiol* 70:199-200.

Wan W, Le T, Riskin L, Macario A. 2009. Improving safety in the operating room: a systematic literature review of retained surgical sponges. *Current Opin Anaesth* 22:207-14.