

## The Cuff Technique for Reconstructing an Isolated Left Vertebral Artery in Total Arch-Replacement Surgery

Min-Ho Song, MD, PhD,<sup>1</sup> Tomohiro Nakayama, MD,<sup>1</sup> Keisuke Hattori, MD, PhD,<sup>1</sup>  
Yayoi Yoshida, MD,<sup>2</sup> Yuichi Ueda, MD, PhD<sup>3</sup>

Departments of <sup>1</sup>Cardiovascular Surgery and <sup>2</sup>Surgery, Gifu Prefectural Tajimi Hospital, Tajimi; <sup>3</sup>Department of Cardiothoracic Surgery, Nagoya University Graduate School of Medicine, Nagoya, Japan

### ABSTRACT

In total arch-replacement surgery, careful attention must be paid to the presence of anomalous arch vessels, because their presence may require surgeons to change the brain-protection strategy during deep hypothermic circulatory arrest and selective cerebral perfusion. The anomaly we most often encounter is an isolated left vertebral artery (ILVA). We describe a case involving a straightforward but physiological way of reconstructing the ILVA in which a cuff is hollowed together with the left subclavian artery.

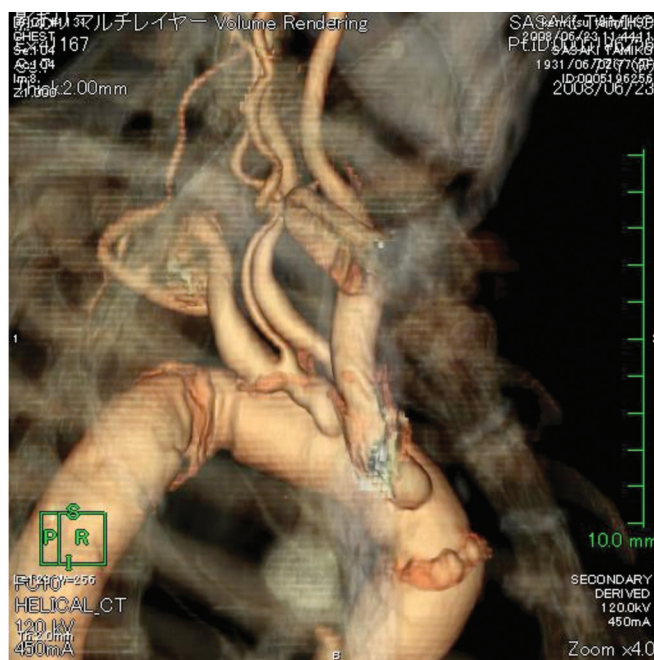
### INTRODUCTION

In total arch-replacement surgery, careful attention must be paid to the presence of anomalous arch vessels, because their presence may require surgeons to change the brain-protection strategy during deep hypothermic circulatory arrest and selective cerebral perfusion (SCP). The anomaly we most often encounter is an isolated left vertebral artery (ILVA) [Suzuki 2006], and we have stumbled on a common but physiological means of reconstructing the ILVA as a cuff hollowed together with the left subclavian artery (LSCA). This experience prompted us to report this case involving such a reconstruction.

### CLINICAL SUMMARY

A 77-year-old woman underwent operation because of a 70-mm thoracic aneurysm of the arch and distal arch. The patient was known preoperatively to have the ILVA originating directly from the aortic arch, which was demonstrated by computed tomography. We used cardiopulmonary bypass in the usual way during surgery. We cooled the patient to a pharyngeal temperature of 24°C and attained circulatory arrest. We opened the aneurysm and inserted perfusion balloon catheters for SCP into the brachiocephalic artery (BCA) and

the left common carotid artery (LCCA). We carefully examined the ILVA and concluded that the orifices of the ILVA and the LSCA should be excised together because they were close together and because their separation would make their anastomosis difficult. We inserted the perfusion balloon catheter into the right SCA, and the ILVA was simply occluded by the occlusion catheter. The orifices of the BCA, the LCCA, and the ILVA, together with the LSCA, were hollowed as cuffs and turn-ups. We performed the distal anastomosis first, as previously described [Song 2007]. As we pulled out the folded prosthetic graft, we decided that the joint ILVA and LSCA cuff should be anastomosed second, because the cuff and the anastomosis site of the 3-branch graft would turn away deeply from the distal anastomosis. The third branch of the prosthetic graft was beveled in accordance with aortic arch convex figure,



Postoperative 3-dimensional computed tomography image showing a wide-open cuff of an isolated left vertebral artery and left subclavian artery placed at the third branch of the graft.

Received July 8, 2008; accepted October 1, 2008.

Correspondence: Min-Ho Song, MD, PhD, Department of Cardiovascular Surgery, Gifu Prefectural Tajimi Hospital, 5-161 Maebata-cho, Tajimi, Gifu, 507-8522, Japan; 81-572-22-5311; fax: 81-572-25-1246 (e-mail: [son-minho@pref.gifu.lg.jp](mailto:son-minho@pref.gifu.lg.jp)).

and it was sewn with the ILVA and the LSCA. We anastomosed the distal prosthetic grafts and then consecutively anastomosed the LCCA, the BCA, and, finally, the proximal ascending aorta. The SCP time was 60 minutes; the hypothermic ischemic time of the lower body was 71 minutes. The aortic cross-clamp time was 172 minutes, the cardiopulmonary bypass time was 194 minutes, and the operation time was 477 minutes. The patient recovered well after the surgery without any neurocognitive morbidities and was discharged home 21 days after the surgery after a computed tomography evaluation confirmed the wide-open ILVA and LSCA (Figure 1).

## DISCUSSION

Methods have been proposed for ILVA reconstruction [Suzuki 2002]. These methods include en bloc reconstruction of arch branches, interposition of a small artificial graft or a saphenous-vein graft between the aortic-arch graft and the ILVA [Naito 2003], anastomosis to the branch of the graft sewn to the LSCA, and direct anastomosis to the native LSCA.

Direct anastomosis of the ILVA with the native LSCA would seem to be advantageous from the viewpoint of long-term patency, but it requires a wide exposure of the LSCA and anastomosis at a very deep position [Suzuki 2006]. The ILVA and a graft branch sewn to the LSCA anastomosis may be the easiest way, but it may lead to a possible late complication of the prosthetic graft and the ILVA anastomosis, such as stenosis and pseudoaneurysm. The cuff technique

we have described could circumvent these shortcomings; the technique is also easy and physiological. Although the cuff technique has been criticized to be of limited usefulness because severe atherosclerotic changes are usually present at this site and because the ILVA and the LSCA are often involved in aneurysmal dilatation of the aorta, these conditions do not always make the cuff technique impossible. The excised cuff is always small, and meticulous suturing through beveling of the branched graft in a curved manner attains good hemostasis at the anastomosis site.

Although there are no published long-term results concerning the patency of the reconstructed ILVA, we think that our cuff technique constitutes a physiological method for reconstructing the ILVA.

## REFERENCES

- Naito Y, Nakajima M, Inoue H, Mizutani E, Tsuchiya K. 2003. Successful treatment of a mycotic aortic arch aneurysm associated with an isolated left vertebral artery. *J Thorac Cardiovasc Surg* 126:883-5.
- Song MH, Tokuda Y, Hirai M, Ueda Y. 2007. Learning curve of arch-first technique analyzed by cumulative sum. *Asian Cardiovasc Thorac Ann* 15:507-10.
- Suzuki K, Kazui T, Bashar AH, et al. 2006. Total arch replacement in patients with arch vessel anomalies. *Ann Thorac Surg* 2006;81:2079-83.
- Suzuki K, Kazui T, Bashar AH, Yamashita K, Terada H, Washiyama N. 2002. Total aortic arch replacement for thoracic aneurysm involving an isolated left vertebral artery. *Jpn J Thorac Cardiovasc Surg* 50:381-2.