

Right Ventricle Mass Removal from Tricuspid Valve Apparatus: An Unusual Thromboembolic Complication of Severe Ketoacidosis

Ireneusz Haponiuk, MD,^{1,2} Maciej Chojnicki, MD,¹ Konrad Paczkowski, MD,¹ Wojciech Kosiak, PhD,³ Radosław Jaworski, MD,¹ Mariusz Steffens, MD,¹ Aneta Szofer-Sendrowska, MD,¹ Katarzyna Gierat-Haponiuk, MD,⁴ Marek Tomaszewski, MD³

¹Department of Pediatric Cardiac Surgery, Mikolaj Kopernik Hospital in Gdansk; ²Physiotherapy, Gdansk Academy of Physical Education and Sport; Departments of ³Pediatrics, Hematology and Oncology and ⁴Rehabilitation, Medical University of Gdansk, Gdansk, Poland

ABSTRACT

The presence of a pathologic mass in the right ventricle (RV) may lead to hemodynamic consequences and to a life-threatening incident of pulmonary embolism. The diagnosis of an unstable thrombus in the right heart chamber usually necessitates intensive treatment to dissolve or remove the pathology. We present a report of an unusual complication of severe ketoacidosis: thrombus in the right ventricle, removed from the tricuspid valve (TV) apparatus. A four-year-old boy was diagnosed with diabetes mellitus (DM) type I de novo. During hospitalization, a 13.9 × 8.4 mm tumor in the RV was found in a routine cardiac ultrasound. The patient was referred for surgical removal of the floating lesion from the RV. The procedure was performed via midline sternotomy with extracorporeal circulation (ECC) and mild hypothermia. Control echocardiography showed complete tumor excision with normal atrioventricular valves and heart function. Surgical removal of the thrombus from the tricuspid valve apparatus was effective, safe, and a definitive therapy for thromboembolic complication of pediatric severe ketoacidosis.

INTRODUCTION

The presence of a pathologic mass in the right ventricle (RV) may lead to hemodynamic consequences and to a life-threatening incident of pulmonary embolism. The origin of the heart mass is usually infectious, especially in high-risk patients with multiple intravenous injections and immune deficiencies that present with bacterial vegetations [Tas 2014; Michta 2015]. The second most common reason is thromboembolism, in patients suffering from peripheral venous thrombosis, and systemic coagulation problems in the course of different pathologies. The differential diagnostics also include heart tumors [Gerede 2015].

Received August 18, 2015; received in revised form February 15, 2016; accepted March 2, 2016.

Correspondence: Ireneusz Haponiuk, MD, Department of Pediatric Cardiac Surgery, Mikolaj Kopernik Hospital, Nowe Ogrody 1-6, Gdansk, Poland; +48-58-764-01-00 (e-mail: ireneusz_haponiuk@poczta.onet.pl).

Children are not excluded from a risk of thrombosis. The diagnosis of an unstable thromboembolic mass in the right heart chambers usually necessitates intensive treatment to dissolve or remove the pathology. We present a report of an unusual complication of severe ketoacidosis: thrombus in the right ventricle (RV), removed from the tricuspid valve (TV) apparatus.

CASE REPORT

A four-year-old boy with newly diagnosed diabetes mellitus (DM) type I was admitted to the Department of Pediatrics in a confused state with apathy and drowsiness. Severe dehydration was noticed, with tachycardia 110-120/min, weak pulse, and tachypnea. The laboratory exams revealed severe hyperglycemia of 595 mg/dL and a number of markers of ketoacidosis and dehydration: pH 7.18; BE 22; HCO₃ 5.0 mmol/L; Na 147 mEq/L; K 6.1 mEq/L; hematocrit 35.9%; RBC 4.26 T/L; PLT 325 G/L; WBC 10.2 G/L; creatinine 1.4 mg/dL; osmolarity 330 mOsm/kgH₂O; CRP 0.2 mg/L.

In anamnesis analyzed for the last four weeks previously the healthy boy was complaining of increasing fatigue, loss of appetite, polydipsia, nocturia, and weight loss of 4 kg. After emergency treatment, the insulin was administered subcutaneously.

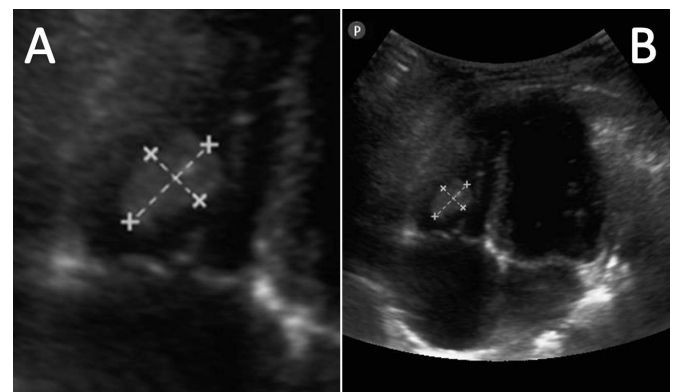


Figure 1. Bedside echocardiography with the convex probe. A, Tumor in the right ventricle (13.9 × 8.4 mm). B, Apical 4-chamber view.

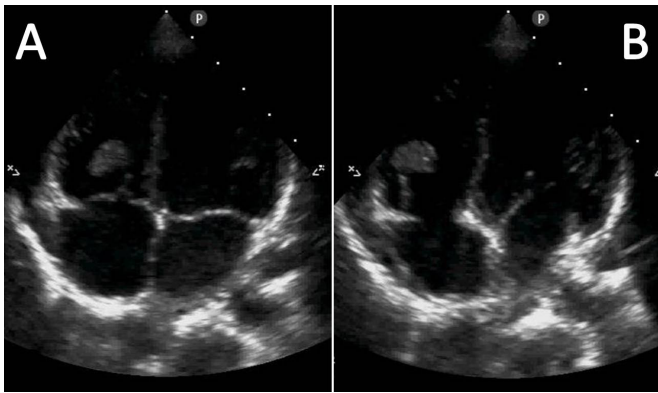


Figure 2. A and B, Apical 4-chamber view with the sector probe. Tumor attached to the right ventricle chordae in the subvalvular tricuspid valve apparatus.

During hospitalization, a bedside echocardiography was done because of increasing cardiac murmur. A tumor in the RV sized 13.9×8.4 mm attached to the TV chordae tendineae was found. Except moderate tricuspid insufficiency, no other heart pathology was found (Figure 1). Detailed transthoracic (TTE) and transoesophageal echocardiography (TEE) examinations were performed. The finding proved to be a movable, well-confined, isoechogenic solid lesion attached to the RV chordate in the subvalvular TV apparatus (Figure 2). The administration of heparin in order to dissolve the suspected thrombus was ineffective. Because of unknown origin and a high risk of pulmonary embolism due to floating mass, the child was referred for surgical removal of the lesion in emergency settings.

Surgical Procedure

The procedure was performed via midline sternotomy with extracorporeal circulation (ECC) and mild hypothermia. After classic midline sternotomy and gentle preparation for ECC cannulation, preoperative heparin was administered in regular dose (3 mg/kg/bw), cardiopulmonary bypass was started, and mild hypothermia was reached. At the 32°C central temperature both caval snares were tightened; after aortic cross-clamp and cardioplegic arrest the heart was opened. The RV cavity was reached through the right atrial (RA) approach, the atrial septal defect foramen ovale type (FoA) was primary sutured. The tumorous mass was exposed in the subvalvular TV apparatus, within the papillary muscle and chordae of the septal and partially posterior leaflets. Its macroscopic image resembled thrombotic material. The irregular friable light-pink tumorous mass attached to the chordae tendineae was gently prepared and evacuated from the RV cavity, without the need to excise the TV apparatus (Figure 3). The great care to preserve TV function was checked during intraoperative control. The heart was closed, aortic cross-clamp released, and after the patient's rewarming, the ECC was finished with sinus rhythm. Heparin reversion, routine hemostasis, pacing wires, pericardial drainage, and chest closure were performed. Control TEE showed normal contractility and good TV competence with

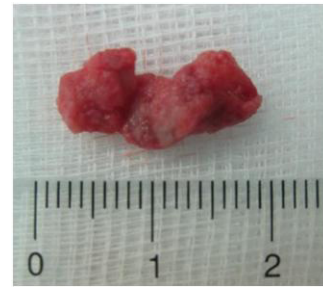

Figure 3. The irregular friable light-pink tumorous mass resected from the right ventricle cavity.

complete removal of the RV mass. The patient was extubated in the postoperative unit two hours after the procedure without complications.

Early postoperative course was uneventful. Anticoagulation therapy with oral aspirin 3 mg/kg/bw administration for the next 30 days was added to insulin treatment. Control echocardiography showed complete tumor excision with normal atrioventricular valves and heart function. The wound healing was uncomplicated. The patient was transferred to the Department of Pediatric Endocrinology on the fourth postoperative day, while the histopathology view of the removed RV mass confirmed an organized thrombus with a predominantly neutrophil infiltration.

In the outpatient controls the patient's general condition was good, with age-appropriate development and skills. Effective glycemic control was obtained using an insulin pump. Control echocardiography revealed no distant complications, and mild TV insufficiency shows no progression over 2-year follow-up time.

DISCUSSION

The risk factors of right heart chamber clots are prolonged catheterization with indwelling catheters [Shin 2013; Ozimek 2000], prematurity, malignant neoplasms and prolonged chemotherapy [Ozimek 2000], infections with blood culture positivity, acquired or genetic thrombophilia with systemic coagulation problems [Kovacikova 2011], blunt trauma of the chest [A ilio lu 2012], cyanotic congenital heart disease or previous cardiac interventions [de Winkel 2010] and nephrotic syndrome [Shah 1996; Cetin 2014, Ekici 2011].

To the best of our knowledge we present the first report of resection of thrombus from the RV that was diagnosed in a child with severe ketoacidosis, in the course of DM type I diagnosed de novo. We stress that the patient was free of previous risk factors, family history, or diagnosed thromboembolic complications.

The diagnostics of the heart mass are based on echocardiography (TTE + TEE) as indicated [Ozimek 2000; de Winkel 2010]. The observed thrombus is usually a mobile echogenic RA or RV mass, while the most dangerous are those located, or even floated on the free border of the TV. The patient was in the group of high-risk patients because of high mobility of the RV mass.

Although therapeutic options include close observation, anticoagulation, thrombolytic therapy, and thrombectomy, guidelines for management of pediatric arterial and venous thrombosis vary greatly among different centers. There are reports of safe and successful dissolution of RA thrombus with low molecular weight heparin [Shin 2013], even in extremely low birthweight infants, classic heparin therapy [A ilio lu 2012], or attempts to use recombinant tissue plasmin activator (rt-PA) infused by a central venous catheter [Ozimek 2000; Ekici 2011]. In unstable or resistant to anticoagulation RA or RV thrombus the only reasonable option remains surgical removal, followed by intravenous and oral anticoagulation.

Because of the unstable position of the mass in preoperative diagnostics and ineffective heparin treatment we initially chose surgical excision as a reasonable emergency procedure in a child with DM [Shah 1996]. We precluded an alternative method of percutaneous mechanical thrombectomy (endovascular embolectomy) with TEE and fluoroscopy because of potential risk for TV subvalvular apparatus, as well as the lack of clear contraindications to surgery [Beregi 1997].

The thrombotic mass usually disappeared after the introduction of various heparin therapies on the follow-up echocardiograms of reported cases [Cetin 2014], thus daily echocardiographic examination is essential during the treatment in order to assess both the timing and mode of thrombus dissolution, or surgical removal [Ozimek 2000; Cetin 2014]. Control TTEs were performed in the presented boy following surgery, also due to the risk of returning clot formation during treatment for DM [de Winkel 2010; Yamamoto 1993].

Conclusion

Surgical removal of the thrombus from the tricuspid valve apparatus was effective, safe, and a definitive therapy for this unusual thromboembolic complication of pediatric severe ketoacidosis.

REFERENCES

- Aşlıoğlu N, Paksu MS, Sungur M, Demirel S. 2012. Intracardiac thrombus case caused by blunt trauma due to child abuse. *Pediatr Emerg Care* 28:566-7.
- Beregi JP, Aumégeat V, Loubeyre C, Couillet JM, Asseman P, Debacker-Steckelorum C. 1997. Right atrial thrombi: percutaneous mechanical thrombectomy. *Cardiovasc Intervent Radiol* 20:142-5.
- Cetin II, Ekici F, Ünal S, Kocabaş A, Sahin S, Yazıcı MU. 2014. Intracardiac thrombus in children: the fine equilibrium between the risk and the benefit. *Pediatr Hematol Oncol* 31:481-7.
- de Winkel N, Becker K, Vogt M. 2010. Echogenic mass in the right atrium after surgical ventricular septal defect closure: thrombus or tumour? *Cardiol Young* 20:86-8.
- Ekici F, Varan B, Şaylan-Çevik B, Özkan M, Ok-Atılğan A, Oktay A. 2011. A large intracardiac fungus ball in a premature infant. *Turk J Pediatr* 53:325-7.
- Gerede DM, Ongun A, Durdu S, Acibuca A, Dincer I. 2015. A rare myxoma in the right ventricular outflow tract. *Turk Gogus Kalp Dama*, 23:739-40.
- Kovacikova L, Skrak P, Zahorec M. 2011. Thrombus obstructing the right ventricle outflow tract in a neonate with methylenetetrahydrofolate reductase 677T genotype. *Eur J Pediatr* 170:1201-3.
- Michta K, Pietrzyk E, Wożakowska-Kapłon B. 2015. Surgically treated cardiac masses — a single-centre experience *Folia Cardiologica* 10:86-90.
- Ozimek W, Wróblewska-Kałużewska M, Gadomski A, Sopyło B, Rokicka-Milewska R, Jaranowska D. 2000. Echocardiographic assessment of right atrial thrombus related to the implanted port device in patient receiving chemotherapy for non-Hodgkin's lymphoma. *Med Sci Monit* 6:1013-17.
- Shah CP1, Thakur RK, Ip JH, Xie B, Guiraudon GM. 1996. Management of mobile right atrial thrombi: a therapeutic dilemma. *J Card Surg* 11:428-31.
- Shin JH, Kim GN, Kil HR, Chang MY. 2013. Successful use of low molecular weight heparin in intracardiac thrombus of an extremely low birth weight infant. *Indian J Pediatr* 80:779-80.
- Taş S, Tuncer E, Boyacıoğlu K, et al. 2014. Cardiac myxomas: a 27-year surgical experience. *Turk Gogus Kalp Dama* 22:526-33.
- Yamamoto N, Hisamochi K, Sugiyama S, Nakayama Y, Senoo Y, Teramoto S. 1993. Extirpation of intra-atrial tumor thrombus of renal cell carcinoma by means of extracorporeal circulation-report of a case. *Nihon Kyobu Geka Gakkai Zasshi* 41:492-7.