

Acute Mitral Valve Dysfunction Due to Escape of Prosthetic Mechanical Leaflet and Peripheral Leaflet Embolization

Eyup Serhat Calik, MD¹, Husnu Kamil Limandal¹, MD, Umit Arslan, MD¹, Mehmet Tort, MD¹, Ziya Yildiz, MD¹, Ednan Bayram, MD², Ozgur Dag, MD¹, Mehmet Ali Kaygin, MD¹, Bilgehan Erkut, MD¹

¹Cardiovascular Surgery Department, Erzurum Regional Training and Research Hospital, Erzurum, Turkey; ²Atatürk University Medical Faculty Department of Cardiology, Erzurum, Turkey

ABSTRACT

Background: Leaflet escape of prosthetic valve is rare but potentially life threatening. Early diagnosis is essential on account of avoiding mortality, and emergency surgical correction is compulsory. This complication has previously been reported for both monoleaflet and bileaflet valve models.

Methods: A 30-year-old man who had undergone mitral valve replacement with a bileaflet valve 8 years prior at another center was admitted with acute-onset with cardiogenic shock as an emergency case. Transthoracic echocardiograms showed acute-starting severe mitral regurgitation associated with prosthetic mitral valve. There was a suspicious finding of a single prosthetic mitral leaflet. But the problem related with the valve wasn't specifically determined. The patient underwent emergent surgery for replacement of the damaged prosthetic valves immediately. There was no tissue impingement and thrombosis, one of the two leaflets was absent, and there were no signs of endocarditis or pannus formation in the prosthetic valve. The missing leaflet could not be found within the cardiac cavity. The abdominal fluoroscopic study and plain radiography were unable to detect the escaped leaflet during surgery. The damaged valve was removed and a replacement 29 mm bileaflet mechanical valve was inserted by right lateral thoracotomy.

Results: After post-operative week one, the abdominal computed tomography scan and the ultrasound showed the escaped leaflet in the left femoral artery. Fifteen days after the surgery the escaped leaflet was removed safely from the left femoral artery and the patient made a complete recovery.

Conclusion: The escaped leaflet showed a fracture of one of the pivot systems caused by structural failure. Early cardiac surgery should be applied because of life-threatening problems.

INTRODUCTION

Malfunction of latterday prosthetic heart valves is usually caused by external factors such as endocarditis, thrombosis, or inadequate surgical techniques rather than by principal factors like errant design [Borowski 1992; Kornberg 1999].

Received June 20, 2015; received in revised form September 17, 2015; accepted October 19, 2015.

Correspondence: Bilgehan Erkut, MD, Erzurum Regional Training and Research Hospital, Cardiovascular Surgery Department, Erzurum, Turkey 25080; +905337451006 (e-mail: bilgehanerkut@yahoo.com).

Acute prosthetic valve dysfunction is a critical condition which is associated with a high morbidity and mortality rate. The leaflet escape from a prosthetic is one of the reasons for valve malfunctions. Leaflet escape due to fracture of a mechanical valve prosthesis has been previously reported for monoleaflet and bileaflet mechanical valves [Cianciulli 2007; Hemmer 2000; Bottio 2003]. It is very rare, is a critical condition for any patient, and is associated with cardiogenic instability and shock. Hence, the rapid and exact diagnosis of valve dysfunction is of vital importance [Cianciulli 2007] and requires immediate surgery.

While the leaflet escape associated with structural valve failure caused by a pivoting system fracture can cause death, the embolization of leaflets normally does not create severe problems. But the removal of the embolized disc should be carried out because of the risk of a progressive extrusion on the peripheral arterial wall. This surgery can be deferrable and carried out and programmed with smaller risk at a later time [Cianciulli 2007].

We report a sudden leaflet dislocation of a bileaflet mitral valve in a mitral position and embolization to the left femoral artery corrected with each subsequent operation in a young male patient.

CASE REPORT

A 30-year-old man underwent mitral valve replacement with a bileaflet prosthetic valve (Sorin Bicarbon) 8 years previous, at the age of 22, at another hospital due to a history of mitral stenosis and pulmonary hypertension; he was admitted to the cardiovascular surgery intensive care unit (ICU) in cardiogenic shock. The patient was found to be well anticoagulated with warfarin, and his value of international normalized ratio was monitored between 2.5-3.2 for many years. A recent transthoracic echocardiography (TTE), which was done 2 months prior, confirmed normal left ventricular systolic function and good functioning of the prosthetic mitral valve with mild pulmonary hypertension (35 mmHg) and mild tricuspid regurgitation.

On admission, he presented with severe orthopnea, cough, hemoptysis, chest pain, deep cyanosis, and palpitation. His jugular vein was prominently engorged. The symptoms had suddenly started 2 days before while he was working in the fields, and were worsening. Tachycardia (160 beats/min), tachypnea (35 breaths/min), and profound hypotension (70/40 mmHg) were present, and the patient was almost unconscious. Arterial blood gas analysis showed oxygen pressure of 47 mmHg, carbon dioxide pressure of 55 mmHg, with

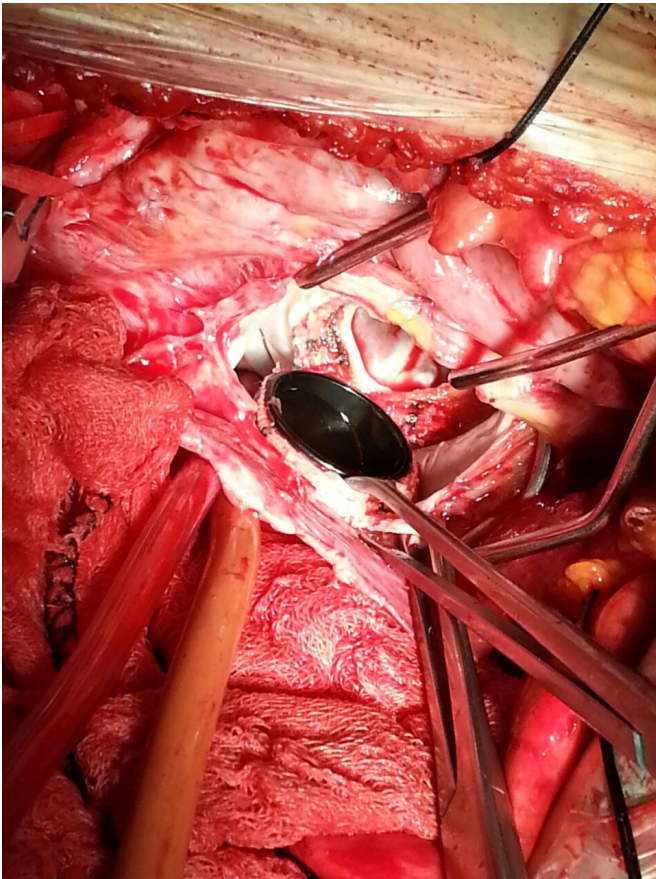


Figure 1. The intraoperative situs shows the remains of the bileaflet mechanical valve with a missing leaflet in mitral position.

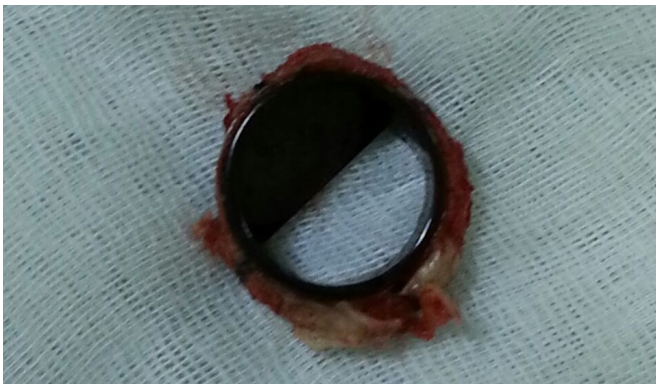

Figure 2. Sorin bicarbon prosthetic mitral valve removed by emergency surgery.

pH of 7.215 with an oxygen mask of 10 L. On pulmonary auscultation, there were rales, which were widespread in all lung fields. The valve click was absent and a systolic murmur near the heart's apex could be noticed on cardiac auscultation. Chest x-ray revealed acute pulmonary edema with aggravated cardiomegaly. The electrocardiography showed sinus tachycardia and atrial extrasistolls. Bedside TTE was performed

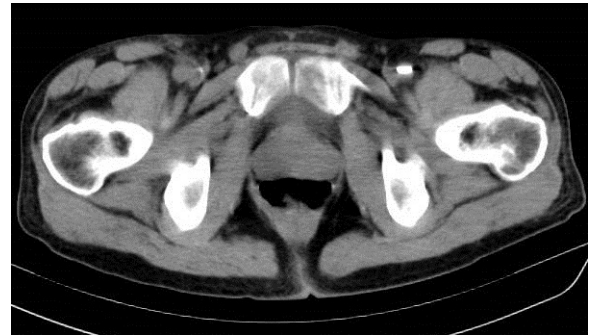

Figure 3. Computed tomography scan showing the location of the escaped leaflet in the left femoral artery.

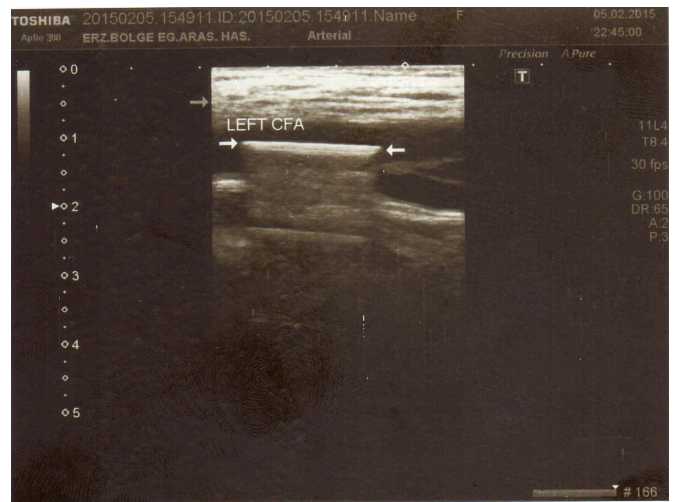

Figure 4. Ultrasound shows the escaped leaflet as a linear hyperechoic object in the left common femoral artery lumen.

to evaluate the cause of the shock and acute decompensated heart failure. TTE showed massive mitral regurgitation, extending into the left atrium and pulmonary veins, and moderate tricuspid regurgitation and severe pulmonary hypertension (85 mmHg). There was a suspicious finding of a single prosthetic mitral leaflet, but details of the mitral leaflet morphology and Color Doppler were not sufficient for evaluating the prosthetic mitral valve function due to tachycardia and poor echo window. The cardiac fluoroscopic examination and transesophageal echocardiography could not be made because of the disorder of the general situation and hemodynamically instability prevented viewing the movements of the mitral valve. The patient was intubated due to intolerably, tachypneic, and progressively hypoxic, and was started on mechanical ventilation before operation in the ICU. After the patient had been monitored, medical therapy (dopamine, noradrenalin, and diuretics) was started. The patient was taken for an emergency operation for valve replacement by right lateral thoracotomy. At reoperation, the cardiopulmonary bypass (CPB) was established with cannulation of the right femoral artery and right femoral vein using two-stage cannula. When the left atrium was opened, the valve's

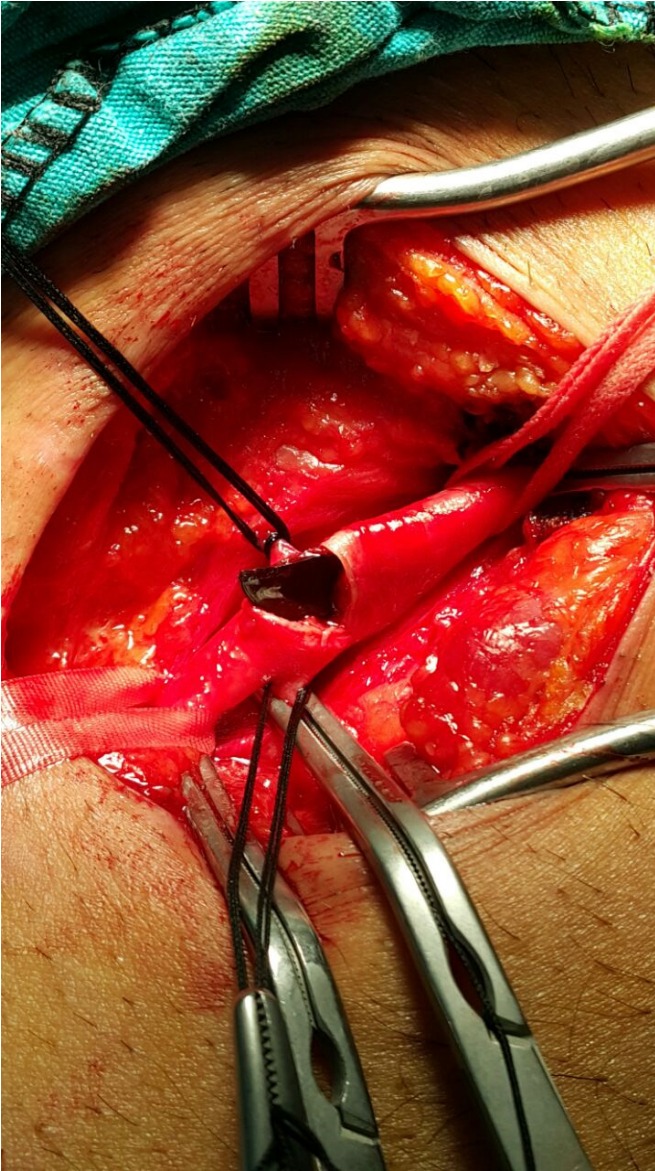


Figure 5. The remaining fragment of leaflet was removed with a 5 mm incision in the left femoral artery.

posterior leaflet was missing, and the anterior leaflet was moving freely; there was no tissue impingement (Figure 1).

There was no thrombosis, sign of endocarditis, or pannus formation. The prosthetic valve was excised and removed (Figure 2). A 29 mm St. Jude mechanical bileaflet mitral valve was inserted. The missing leaflet could not be found within the cardiac cavity. The abdominal fluoroscopic study and plain radiography were unable to detect the escaped leaflet at the end of the operation. CPB was discontinued and dopamine/dobutamine administered. The patient was weaned from CPB and could be referred to the ICU in stable condition. Hemorrhagic complications weren't identified. Postoperatively, the patient awoke on day 3, and showed no sign of neurological abnormality and did not need respiratory

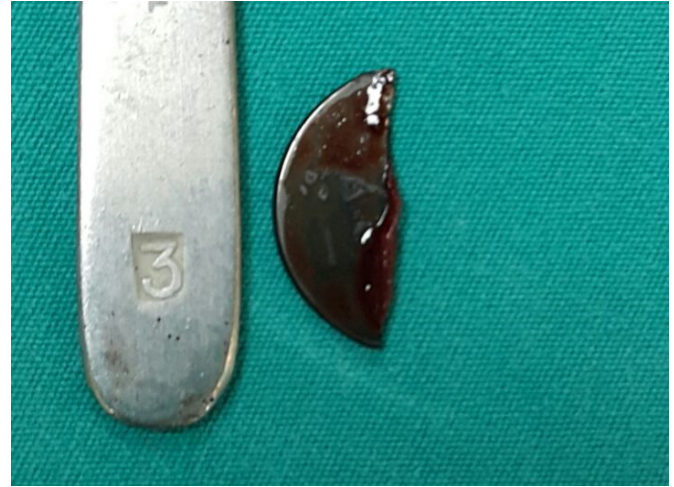

Figure 6. Missing leaflet.

support. Postoperative TTE showed the mitral valve to be functioning well, with an ejection fraction of 55% and pulmonary hypertension (25 mmHg), but no pericardial effusion. When the hemodynamic parameters had been stabilized, catecholamine treatment was discontinued gradually. At the end of the first week, abdominal CT (Figure 3) and USG (Figure 4) scans were made to find the missing valve. They showed that the escaped leaflet was in the left femoral artery. With a second operative intervention, the embolized leaflet was removed safely 15 days later using a left femoral exploration (Figures 5 and 6). No problems were encountered during the patient's postoperative course, and the patient was discharged in good condition 30 days later with a normal sinus rhythm, a normal functioning prosthetic valve on echocardiography, and was well anticoagulated.

DISCUSSION

The mechanical bileaflet valve is a rather new valve produced in many parts of the world. The material and structural testing and in-vivo testing were carried out in Hungary, Japan, Germany, and Brazil over years, and many are still widely used in many countries around the world. These prosthetic heart valves have been designed using finite-element techniques, thereby maximizing hemodynamic performance and ensuring safety [Dikmengil 2004].

One of the deep concerns for mechanical prosthetic valves is durability and robustness for the duration of life. Due to known problems associated with the valves, the patients must be closely monitored after operation, ongoing, for years. Acute prosthetic valve dysfunction is a critical condition for any patient, and may be associated with high mortality. The escape of the prosthetic valve leaflet is one of the causes of prosthetic dysfunction, and requires emergency surgery; it has been reported to be extremely rare overall worldwide [Cianciulli 2007; Deuvaert 1989; Klepetko 1989; Alvarez 1990; Kumar 1991; Tatou 2001]. The main cause of this problem is primary structural failure, and most reports in

the literature of leaflet escape is incoming from valves in the mitral position [Cianciulli 2007; Deuvaert 1989; Klepetko 1989; Alvarez 1990]. This may be due to the bigger direct systolic pressure supported by mitral disc during systole and following bigger mechanical stress of the mitral valve as compared with the aortic valve [Cianciulli 2007; Klepetko 1989]. The time of leaflet escape varies between 12 years and 19 days after the replacement of the valve [Baudet 1995; Fragoulis 2008]. The incidence of this tragic incident is between 0.2% and 0.3% according to manufacturer data. Perhaps there were cases that resulted in death without the possibility of diagnosis until now.

These bileaflet valves have solid pyrolytic carbon components, hardening ring, and stainless steel in their ring structure, and have been designed to rotate in situ. However, pyrolytic carbon is a very hard material, but also very brittle [Dikmengil 2004; Hemmer 2000]. The characteristic of the valve includes a pivot system, and has a complete and powerful sweep property. The causes of escaped leaflets have been investigated recently. The damage of the pivoting system, leading to an inadmissible rate of prosthetic failure, is the main cause in reported cases [Cianciulli 2007]. The cause of this destruction in the pivot system has been analyzed for many years. This may ensue either as a result of malpractice during implantation, or due to production problems. Failure type during implantation may be as direct and/or indirect by tearing or applying force on the stiffening ring associated with impingement of the leaflet. Failure type during production problems may be associated with orifice ring fracture and leaflet fracture, and these may usually be seen in a relatively short time period. Now, therefore, the identification of predictors of pivot fracture becomes crucial for bileaflet prosthetic valve recipients worldwide. In light of these regrettable incidents, we must follow patients by echocardiogram and fluoroscopy to evaluate leaflet movements.

Miscellaneous diagnostic methods such as TTE, TEE and fluoroscopy were used in conditions associated with heart valve problems over the years. But none of these technique are effective for diagnosis of detachment of the valve leaflet. Fluoroscopy is a helpful vehicle in the functional evaluation of prostheses with radiopaque discs. But it cannot provide data on prosthetic function due to radiolucency of the discs. Although bedside TTE and/or TEE for evaluation of valve function may be useful non-invasive diagnostic tools, they are usually not definitive diagnostics and may cause misinterpretation as obstructed closure of the prosthetic valve, paravalvular leak, or thrombosis [Kornberg 1999; Messner-Pellenc 1993; Devbhandari 2008; Vogel 1993]. In our case, although the TTE images were not sufficient for evaluating the exact mitral valve morphology and function, a single mitral leaflet was suspicious using bedside TTE. And, we thought that the other leaflet would be immobile due to pannus or thrombosis. We wanted to use TEE and/or fluoroscopy to understand the pathology associated with the valve. But due to hemodynamic instability, the patient underwent emergency surgery without any additional definitive diagnostic investigations.

Fractured or escaped valve fragments are usually difficult to locate within the heart when they embolize. This location

of the missing leaflet can be difficult to identify in the case that the leaflet embolized to the distal aorta or its branches. The most commonly reported location of the escaped leaflet is in the arterial system between the aorta and the femoral artery. When the leaflet escape happens without breaking in pieces, considering the size of the escaped leaflet, the most common site to find it is the aortic bifurcation, and it can only be retrieved surgically with laparotomy and aortotomy. But when the disc breaks in two or more fragments, it could be found in the common iliac arteries and depending on their sizes, percutaneous retrieval of the fragments could be attempted. CT is the best tool to locate the missing leaflet. Plain x-rays are not helpful because of lack of radio-opacity of the prosthetic valves. USG was done to determine exactly localization. CT scan and USG provided conclusive results. When the site of embolization is the femoral arteries, the fragments of the disc could be extracted with a little incision in the groin as in our case [Cianciulli 2007].

The clinical presentation is usually acute pulmonary edema with cardiogenic shock as the result of acute valvular incompetence [Deuvaert 1989; Klepetko 1989; Alvarez 1990; Kumar 1991]. The sudden deterioration in the condition of a previously healthy patient after valve replacement is highly suggestive of mechanical valve dysfunction, including leaflet fracture. In a leaflet escape or fracture, two important factors must be considered. The first is the hemodynamic change related to the resultant acute mitral insufficiency, and the second is embolization of the leaflet. The hemodynamic change related to leaflet fracture or escape is catastrophic, and an urgent reoperation can be carried out. The rapid and exact diagnosis of valve dysfunction is of vital importance. The acute onset of severe symptoms of heart failure, dyspnea, and shock are highly suggestive of mechanical dysfunction of the valve, and can be differentiated from thrombosis, where the onset of symptoms is gradual. As previously reported, the embolization of leaflets normally does not create severe problems [Kornberg 1999; Dikmengil 2004; Klepetko 1989; Jazayeri 2001]. The femoral exploration in our case was performed after 15 days of recovery for the patient as in similar previous reports [Cianciulli 2007; Klepetko 1989; Alvarez 1990].

It is acknowledged that timely diagnosis and emergent surgical replacement of the prosthetic valve is the most important. The appropriate manner of treating acute valve dysfunction is first to provide rapid relief for the failing left ventricle and congested lungs, and then to replace the defective valve with a functioning atrioventricular valve as quickly as possible. The embolized leaflet normally does not create severe problems, but must be found and retrieved because a progressive extrusion through the arterial wall can happen, and it may cause arterial wall damage leading to erosions, infections, and further migrations [Kornberg 1999]. The removal of any embolized valve parts is of secondary importance. If the patient is not highly symptomatic, the relevant surgery may be carried out with much lower risk at a later date. So these imaging interventions to locate the escaped leaflet can be delayed until the patient has recovered [Bottio 2003; Lee 2007; Kim 2004; Youn 2002].

Although it is rare, when a patient with previous history of prosthetic valve replacement presents with symptoms of acute decompensated heart failure, escape of the valve leaflet should be considered. In cases of the leaflet escape, the appropriate manner of treating acute prosthetic dysfunction is first to replace the defective valve as quickly as possible. The retrieval of any embolized fragments of the valve is of secondary importance, and elective surgery may be postponed to a later date. However, because of progressive extrusion through the arterial wall, the leaflet escape must be found and retrieved, even if the patient is asymptomatic.

REFERENCES

- Alvarez J, Deal CW. 1990. Leaflet escape from a Duromedics valve. *J Thorac Cardiovasc Surg* 99:372.
- Baudet E, Roques X, McBride J, Panès F, Grimaud JP. 1995. A 8-year follow-up of the Edwards-Duromedics bileaflet prosthesis. *J Cardiovasc Surg (Torino)* 36:437-42.
- Borowski A, Reib N, Klaer R. 1992. Intermittent obstruction of the Omnicarbon-valve prosthesis in the mitral position due to interference by papillary muscle. *J Cardiovasc Surg* 33:305-7.
- Bottio T, Casarotto D, Thiene G, Caprili L, Angelini A, Gerosa G. 2003. Leaflet escape in a new bileaflet mechanical valve: TRI technologies. *Circulation* 107:2303-6.
- Cianciulli TF, Lax JA, Saccheri MC, et al. 2007. Acute mitral valve dysfunction due to leaflet escape in a Tri-technologies bileaflet mechanical valve. *Eur J Echocardiogr* 8:63-6.
- Deuvaert FE, Devriendt J, Massaut J, Van Nooten G, De Paepe J, Primo G. 1989. Leaflet escape of a mitral Duromedics prosthesis. Case report. *Acta Chir Belg* 89:15-18.
- Devbhandari MP, Woo EB, Hooper TL. 2008. Long-term event-free survival with an embolized prosthetic valve leaflet in the thoracic aorta. *J Cardiothorac Surg* 3:34.
- Dikmengil M, Sucu N, Aytacoglu BN, Mavioglu I. 2004. Leaflet escape in a TRI bileaflet rotatable mitral valve. *J Heart Valve Dis* 13:638-40.
- Fragoulis S, Palatianos GM. 2008. Fractured prosthetic valve leaflet. *Eur J Cardiothorac Surg* 34:907.
- Hemmer WB, Doss M, Hannekum A, Kapfer X. 2000. Leaflet escape in a Tekna and an original Duromedics bileaflet valve. *Ann Thorac Surg* 69:942-4.
- Jazayeri S, Meunier JP, Tatou E, et al. 2001. Fracture embolization of a Tekna mitral prosthesis: Case report. *J Heart Valve Dis* 10:219-21.
- Kim JH, Oh SS, Na CY, Baek MJ, Seo HJ, Kim CW. 2004. Leaflet escape of edwards duromedics mechanical heart valve: report of 1 case. *Korean J Thorac Cardiovasc Surg* 37:373-5.
- Klepetko W, Moritz A, Mlczoch J, Schurawitzki H, Domanig E, Wolner E. 1989. Leaflet fracture in Edwards-Duromedics bileaflet valves. *J Thorac Cardiovasc Surg* 97:90-4.
- Kornberg A, Stephen MW, Schulze C, Kreuzer E. 1999. Leaflet escape in Omnicarbon monoleaflet valve. *Eur J of Cardiothorac Surg* 15:867-9.
- Kumar N, Balasundaram S, Rickard M, al Halees Z, Duran CM. 1991. Leaflet embolisation from Duromedics valves: a report of two cases. *Thorac Cardiovasc Surg* 39:382-3.
- Lee SY, Choi JB. 2007. Escape of mechanical valve: a case report. *Korean J Thorac Cardiovasc Surg* 40:63-5.
- Messner-Pellenc P, Wittenberg O, Leclercq F, et al. 1993. Doppler echocardiographic evaluation of the Omnicarbon cardiac valve prostheses. *J Cardiovasc Surg* 34:195-202.
- Tatou E, Saleh M, Eicher C, Brenot R, David M. 2001. Fracture-embolization of duromedics valve prosthesis and microscopic uncommon lesions. *Ann Thorac Surg* 71:1366-9.
- Vogel W, Stoll HP, Bay W, Fröhlig G, Schieffer H. 1993. Cineradiography for determination of normal and abnormal function in mechanical heart valves. *Am J Cardiol* 71:225-32.
- Youn YN, Yoo KJ. 2002. Valve leaflet escape of edwards duromedics mechanical valve. *Korean J Thorac Cardiovasc Surg* 35:60-3.